



universidad
de león

DEPARTAMENTO DE SANIDAD ANIMAL
FACULTAD DE VETERINARIA

TESIS DOCTORAL

**INFLUENCIA DEL AGENTE ETIOLÓGICO Y LA
RESPUESTA INMUNITARIA LOCAL SOBRE LA
PATOGENIA DE LA PARATUBERCULOSIS DE LOS
RUMIANTES**

PhD THESIS

**INFLUENCE OF THE ETIOLOGICAL AGENT AND THE
LOCAL IMMUNE RESPONSE ON THE
PATHOGENESIS OF RUMINANT
PARATUBERCULOSIS**

Memoria presentada por D. Miguel Fernández Fernández
para optar al Grado de Doctor en Veterinaria

León, Marzo de 2017



INFORME DE LOS DIRECTORES DE LA TESIS

Los Doctores. D. VALENTÍN PÉREZ PÉREZ, D^a M. CARMEN FERRERAS ESTRADA y D. JULIO BENAVIDES SILVÁN como Directores de la Tesis Doctoral titulada “INFLUENCIA DEL AGENTE ETIOLÓGICO Y LA RESPUESTA INMUNITARIA LOCAL SOBRE LA PATOGENIA DE LA PARATUBERCULOSIS DE LOS RUMIANTES” realizada por D. MIGUEL FERNÁNDEZ FERNÁNDEZ en el programa de DOCTORADO EN MEDICINA, SANIDAD Y PRODUCCIÓN ANIMAL Y CIENCIA DE LOS ALIMENTOS, informa favorablemente el depósito de la misma, dado que reúne las condiciones necesarias para su defensa.

Lo que firmamos, en León a 28 de Marzo de 2017

Valentín Pérez Pérez M. Carmen Ferreras Estrada Julio Benavides Silván

“La agricultura es el arte que enseña virtud al hombre y la base de la opulencia de todas las naciones”

Gaspar Melchor de Jovellanos, SXVIII

“La investigación de las enfermedades ha avanzado tanto que cada vez es más difícil encontrar a un individuo completamente sano”

Aldous Huxley



A mis abuelos

A mis padres

A mi hermana

Agradecimientos

Todas las cosas tienen su recorrido y esta Tesis también. Para poder recorrerlo y finalizarlo han sido muchas las personas que han participado y colaborado, y que sin ellas, estas palabras no estarían hoy escritas. Por ese motivo, quiero manifestar mi más sentido agradecimiento:

En primer lugar a mis directores, los doctores D. Valentín Pérez, D^a M. Carmen Ferreras y D. Julio Benavides por haberme dado la oportunidad de sumergirme en este mundo y dirigir este trabajo para que llegase a buen puerto, por confiar en mí, por ayudarme en todo cuanto he necesitado y por brindarme estos años de formación a vuestro lado. Eternamente agradecido.

A Valentín, por ser un ejemplo, tanto en lo personal como en lo profesional. Gracias por tu amistad, humildad, generosidad y dedicación, a veces sobrehumana, sacando tiempo de donde no lo hay e involucrándote en tantas cosas a la vez, todas ellas en busca del beneficio de los demás. Por formar un grupo de investigación profesional y ‘moderno’. Gracias por enseñarme y guiarme, mirando el presente y el futuro, durante estos años. Al final, tus ‘males’ no han impedido que este trabajo se materialice. A Maica por ser una madre-directora, por tus fructíferas explicaciones, tanto didácticas como cotidianas y, en definitiva, por hacer ameno el día a día por muchos cadáveres que se rebasen. A Julio, por tu amistad y bondad, por hacerme ver que cualquier cosa puede resultar interesante, trasmitirme tu pasión por la ciencia y convertirme en el perejil de tus salsas.

A todas las personas del departamento de Sanidad Animal con las que he compartido estos años. A Miguel, Fuertes Franco, por ser un instructor necesario y libro de consultas abierto. A PC Badajo, por las horas compartidas y charlas sobre la vida. A Marcos, para que vea que no soy borde. A Laetitia,

porque su trabajo previo y metodología han sido la base para mí y los que vengan. A Gloria y Jaime por la esencia de su labor.

A todo personal del IGM, por su ayuda durante estos años tanto laboratorial como en la granja. A 'los de las naves' por el cuidado de los animales, ayuda en muestreos y en cualquier cosa que necesité. A Carmen y M Jesús, por vuestra ayuda, empatía y buen humor (a veces demasiado) a pesar de la edad.

Danke an alle Menschen mit denen ich meinen Aufenthalt in der Schweiz geteilt haben. Besonders Prof. Anja Kipar und Dr. Monika Hilbe für die Gelegenheit auf Institut für Veterinärpathologie - Universität Zürich für ihre herzlichen Empfang, Lehre und gute Zeiten.

A mis amigos de la carrera, gracias por formar este grupo unido y servir de apoyo continuo. Conseguimos formar una 'familia' de *foriatus* en León. A 'casa cuéntame', más que una casa, importante en nuestras vidas, y lo sabéis. A todos los del piso, gracias por aguantarme, cosa recíproca, pero somos como hermanos.

A los de aquí, de Braña, porque aunque seamos cuatro casas, somos suficientes. Gracias por vuestra amistad y estar siempre que lo necesito.

A Gema, mi hermana, sinónimo de alegría y despreocupación, pero necesaria en toda causa. A Viky por ser tan buena persona, apoyarme y animarme constantemente en todas las aventuras en que me embarco.

Finalmente a mis padres, incansables y luchadores, motor para que esto haya sucedido.

En general, a todos/as los que han contribuido de una manera u otra a que este trabajo haya llegado a buen puerto. Espero no haberme olvidado de nadie.

Presentación de la Tesis Doctoral

La presente Tesis Doctoral se ha llevado a cabo en el marco del programa de Doctorado en Medicina, Sanidad y Producción Animal y Ciencia de los Alimentos de la Universidad de León regulado por el RD 1393/2007. El trabajo ha sido realizado en el Departamento de Sanidad animal de la Facultad de Veterinaria de la Universidad de León y en el Instituto de Ganadería de Montaña (IGM) del Consejo Superior de Investigaciones Científicas (CSIC). Su desarrollo ha sido posible gracias al disfrute de un contrato predoctoral financiado por la Junta de Castilla y León y el Fondo Social Europeo y a la financiación de los proyectos AGL2008-05820-C02, AGL2012-39818-C02-01 y AGL2015-66540-C2-01 por el Ministerio de Economía y Competitividad.

La Tesis Doctoral ha sido elaborada en formato de Compendio de Publicaciones y de Mención Internacional del título de Doctor conforme a la normativa que regula los estudios de doctorado. A continuación, se detallan los cuatro artículos publicados que forman el cuerpo principal de esta Tesis:

- 1. Experimental infection of lambs with C and S-type strains of *Mycobacterium avium* subspecies *paratuberculosis*: immunological and pathological findings.**
- 2. Virulence attenuation of a *Mycobacterium avium* subspecies. *paratuberculosis* S-type strain prepared from intestinal mucosa after bacterial culture. Evaluation in an experimental ovine model.**
- 3. Macrophage subsets within granulomatous intestinal lesions in bovine paratuberculosis.**
- 4. Immunohistochemical expression of interferon- γ in different types of granulomatous lesions associated with bovine paratuberculosis.**

ÍNDICE GENERAL

INDEX

1. LISTADO DE ABREVIATURAS	1
2. REVISIÓN BIBLIOGRÁFICA: La paratuberculosis.....	5
2.1. Etiología	8
2.1.1. Características generales de <i>Map</i>	9
2.1.2. Cepas de <i>Map</i>	9
2.1.2.1. Tipo de cepas de <i>Map</i>	10
2.1.2.2. Variabilidad epidemiológica de las cepas	13
2.1.2.3. Variabilidad en la virulencia de las cepas	13
2.2. Epidemiología, diagnóstico y control	14
2.3. Patogenia	20
2.3.1. Interacción patógeno-hospedador	21
2.3.2. Respuesta inmunitaria	24
2.3.2.1. Respuesta inmunitaria de tipo innato	25
2.3.2.2. Respuesta inmunitaria de tipo adaptativo	30
2.3.2.2.1. Respuesta inmunitaria celular	32
2.3.2.2.2. Respuesta inmunitaria humoral	35
2.3.3. Establecimiento y desarrollo de las lesiones	38
2.3.3.1. Influencia de la respuesta inmunitaria local en el desarrollo de las lesiones	40
2.3.3.1.1. El IFN- γ	43
2.4. Signos clínicos y curso de la enfermedad	45
2.5. Lesiones	47
2.5.1. Lesiones macroscópicas	47
2.5.2. Lesiones microscópicas	49
2.5.2.1. Clasificación de las lesiones	51
2.5.3. Espectro inmunopatológico de la paratuberculosis	59
2.5.4. Los macrófagos en la respuesta inflamatoria	60
2.5.4.1. Polarización M1 y M2	62
2.5.4.2. Macrófagos e infecciones por micobacterias	67
2.6. Infecciones experimentales con <i>Map</i>	69
2.6.1. Cepas de <i>Map</i>	71
2.6.2. Tipo de inóculo	72
2.6.3. Dosis infectiva y vía de administración	75
2.6.4. Modelos experimentales ovinos	76
2.6.5. Modelos experimentales bovinos	79
2.6.6. Infecciones experimentales en otras especies	82
3. JUSTIFICACIÓN Y OBJETIVOS.....	85

4. METODOLOGÍA Y RESULTADOS	93
4.1. PRIMER ESTUDIO: Experimental infection of lambs with C and S-type strains of <i>Mycobacterium avium</i> subspecies <i>paratuberculosis</i> : immunological and pathological findings	95
4.1.1. Introducción	98
4.1.2. Material y métodos	100
4.1.3. Resultados	107
4.1.4. Discusión	120
4.2. SEGUNDO ESTUDIO: Virulence attenuation of a <i>Mycobacterium avium</i> subspecies <i>paratuberculosis</i> S-type strain prepared from intestinal mucosa after bacterial culture. Evaluation in an experimental ovine model	133
4.2.1. Introducción	136
4.2.2. Material y Métodos	138
4.2.3. Resultados	146
4.2.4. Discusión	154
4.3. TERCER ESTUDIO: Macrophage subsets within granulomatous intestinal lesions in bovine paratuberculosis	163
4.3.1. Introducción	166
4.3.2. Material y Métodos	170
4.3.3. Resultados	178
4.3.4. Discusión	186
4.4. CUARTO ESTUDIO: Immunohistochemical expression of interferon- γ in different types of granulomatous lesions associated with bovine paratuberculosis	199
4.4.1. Introducción	202
4.4.2. Material y Métodos	205
4.4.3. Resultados	210
4.4.4. Discusión	215
5. DISCUSIÓN GENERAL.....	225
6. CONCLUSIONES/CONCLUSIONS.....	253
7. RESUMEN/SUMMARY	263
8. BIBLIOGRAFÍA	277
9. ANEXO: PUBLICACIONES/APPENDIX: PUBLICATIONS.....	309

1. LISTADO DE ABREVIATURAS

ABBREVIATIONS LIST

ADN: Ácido desoxirribonucleico

ARNm: Ácido ribonucleico mensajero

BAAR (AFB): Bacilos ácido- alcohol resistentes

C: Cepas Tipo C o bovinas

CPA: Célula presentadora de antígeno

Dpi: Días post-infección

EF-Tu: “Elongation factor thermo unstable”, factor de elongación termoinestable

ELISA: “Enzyme-Linked immunosorbent assay”, ensayo por inmunoadsorción ligado a enzimas

FAP: “Fibronectin attachment protein”, proteína de acoplamiento a la fibronectina

FcR: “Fc receptors”, receptores para la porción Fc de las inmunoglobulinas

g: gramo

GALT: “Gut associated lymphoid tissue”, tejido linfoide asociado al intestino

GM-CSF: “Granulocyte-macrophage colony-stimulating factor”, factor estimulante de colonias de granulocito-macrófago

HE: Hematoxilina-eosina

HEYM: “Herrold’s egg yolk medium”, medio de Herrold con yema de huevo

Iba1: “Ionized calcium-binding adaptor molecule 1, molécula adaptadora de unión a calcio ionizado 1

IDR: Intradermorreacción

IFN- γ : Interferon gamma

Ig: Inmunoglobulina

IGRA: “Interferon γ release assay”, ensayo de liberación de interferón gamma

IL: Interleucina

iNOS: “Inducible nitric oxide synthase”, óxido nítrico sintasa inducible

IS: “Insertion sequence”, secuencia de inserción

ITS: “Internal transcribed spacer”, espaciador transcrito interno

LAM: Lipoarabinomanano

LPP: Lipoproteína

LPS: Lipopolisacárido

M-CSF: “Macrophage colony-stimulating factor”, factor estimulante de colonias de macrophago

M1: Macrófago clásicamente activado

M2: Macrófago alternativamente activado

Maa: *Mycobacterium avium* subsp. *avium*

MAC: “*Mycobacterium avium* complex”, complejo *Mycobacterium avium*

Mah: *Mycobacterium avium* subsp. *hominissuis*

Map: *Mycobacterium avium* subsp. *paratuberculosis*

Mas: *Mycobacterium avium* subsp. *silvaticum*

Mtb: *Mycobacterium tuberculosis*

MHCII: Complejo mayor de histocompatibilidad de clase II

ml: Mililitro

mm: Milímetro

mpi: Meses post- infección

NK: “Natural killer”,

NO: “Nitric oxide”, óxido nítrico

NOD: “Nucleotide-binding oligomerization domain receptors”, receptores tipo NOD

NRAMP1: “Natural-resistance-associated macrophage protein 1”, proteína de macrófago asociada a la resistencia natural 1

PAMPs: Patrones moleculares asociados a patógenos

PBS: “Phosphate buffered saline”, tampón fosfato salino

PCR: “Polymerase chain reaction”, reacción en cadena de la polimerasa

PCR-REA: “Polymerase chain reaction-restriction enzyme analysis”, reacción en cadena de la polimerasa- análisis de restricción enzimática

PFGE: “Pulsed field gel electrophoresis”, electroforesis en gel de campos pulsantes

PPD: “Purified protein derivative”, derivado proteico purificado

PRR: “Pattern recognition receptor”, receptores de reconocimiento de patrones

RFLP: “Restriction fragment length polymorphism”, polimorfismo en la longitud de los fragmentos de restricción

S: Cepas tipo S u ovinas

SNP: “Single nucleotide polymorphism”, polimorfismo de nucleótido simple

Tc: Linfocitos T citotóxicos

TGF- β : “Transforming growth factor beta”, factor de crecimiento transformante beta

Th1: “Helper T lymphocytes type 1”, linfocitos T auxiliares tipo 1

Th2: “Helper T lymphocytes type 2”, linfocitos T auxiliares tipo 2

TLR: Receptores “toll-like”

TNF- α : “Tumor necrosis factor-alpha”, Factor de necrosis tumoral alfa

Treg: Linfocitos T reguladores

UFC: Unidades formadoras de colonias

ZN: Ziehl Neelsen

2. REVISIÓN BIBLIOGRÁFICA

LITERATURE REVIEW

2. La paratuberculosis

Las infecciones bacterianas crónicas del ganado bovino, ovino y caprino constituyen un grave problema productivo y además, en el caso de las de carácter zoonótico, un riesgo para el hombre. Su control y erradicación están basados en los programas oficiales de saneamiento ganadero y la acción de agrupaciones de defensa sanitaria ganadera. Los objetivos, procedimientos y resultados de estos programas varían según las características de la enfermedad y sus implicaciones productivas y sanitarias. Dentro de estas enfermedades, la paratuberculosis, también conocida como enfermedad de Johne, es una de las infecciones crónicas de los rumiantes de mayor importancia a nivel mundial, por su amplia distribución y su elevada prevalencia, y principalmente, por las pérdidas económicas que ocasiona en los rebaños.

La paratuberculosis está causada por *Mycobacterium avium* subespecies *paratuberculosis* (*Map*) y afecta fundamentalmente a los rumiantes domésticos y silvestres. Además, desde hace unos años, *Map* ha adquirido una importancia creciente en la salud pública debido a su posible implicación como agente causal de la enfermedad de Crohn en humanos (Chiodini, 1989; Mishina *et al.*, 1996; Greenstein, 2003) tras el aislamiento de dicha micobacteria en muestras de sangre y tejidos de personas con esta enfermedad (Naser *et al.*, 2004; Sechi *et al.*, 2005; Lee *et al.*, 2011) y suscitado un gran interés sobre el papel zoonótico de este agente. Consecuentemente, la industria alimentaria también se ha visto alertada y se han incrementado los estudios con el fin de garantizar la seguridad alimentaria, ante la posible transmisión por los alimentos (Eltholth *et al.*, 2009; NACMCF, 2010; Collins, 2011; Gill *et al.*, 2011).

2.1. Etiología

La implicación de una micobacteria como agente responsable de la paratuberculosis fue ya sugerida a finales del siglo XIX en Alemania al identificar la presencia de bacilos ácido-alcohol resistentes en el intestino de vacas que presentaban diarrea (Johne y Frothingham, 1895). Actualmente, se conoce como *Mycobacterium avium* subespecies *paratuberculosis* (*Map*), microorganismo que, desde un punto de vista taxonómico, se incluye dentro del género *Mycobacterium* (Lehman y Newman, 1896), único género de la Familia *Mycobacteriaceae* perteneciente al Orden Actinomycetales, del que también forman parte los agentes causales de la tuberculosis (*Mycobacterium tuberculosis*, *Mycobacterium bovis*, *Mycobacterium caprae*) y de la lepra (*Mycobacterium leprae*). Dentro de este género se encuadran micobacterias ambientales, micobacterias propias del ganado y de las aves, y otras subespecies que actúan como patógenos oportunistas (Glawischnig *et al.*, 2006; Turenne y Alexander, 2010; Rindi y Garzelli, 2014).

En un primer momento, el agente causal de la paratuberculosis se denominó *Mycobacterium paratuberculosis* (Bergey *et al.*, 1923), posteriormente, durante mucho tiempo, *Mycobacterium johnei* (Francis, 1943) y finalmente, *Map* (Thorel *et al.*, 1990). El hecho de mantener a *Map* como una subespecie de *M. avium* o una especie diferenciada del género *Mycobacterium* es aún objeto de gran controversia (Juste *et al.*, 2000a; Manning y Collins, 2001) ya que para algunos investigadores en el primer caso se quitaría importancia a la relevante naturaleza patógena de *Map*, frente a *M. avium*. En cualquier caso, el nombre oficial es el propuesto por Thorel *et al.* (1990), apoyándose en los estudios previos de caracterización genética y fenotípica, y en su exhaustivo trabajo de taxonomía numérica basada en similitudes morfológicas. Actualmente el complejo *Mycobacterium avium* (MAC) está formado por las subespecies *Map*, *M. avium* subsp. *avium*

(*Maa*), *M. avium* subsp. *hominissuis* (*Mah*) y *M. avium* subsp. *silvaticum* (*Mas*), garantizando así la representación de la homología observada entre ellas, pero sin olvidar las propiedades distintivas de cada una (Turenne y Alexander, 2010). *Mah* es la más recientemente incorporada para designar aislados de la especie humana y porcina, que también se han encontrado en otras especies de mamíferos (Mijs *et al.*, 2002; Turenne *et al.*, 2007).

2.1.1. Características generales de *Map*

El agente causal de la paratuberculosis es un bacilo de 1-2 μm de longitud y hasta 0,5 μm de anchura. *Map* es un microorganismo Gram positivo facultativo, ácido-alcohol resistente (muestra una tinción homogénea mediante la técnica de ZN), aerobio e inmóvil y de crecimiento lento (Juste *et al.*, 1991; Harris y Barletta, 2001; Manning y Collins, 2001). Su crecimiento en el laboratorio es lento y se precisan desde 8-16 semanas hasta 6 meses para poder visualizar la formación de colonias, en cultivos a base de huevo y medios sintéticos (Merkal *et al.*, 1981; Adúriz *et al.*, 1995; Harris y Barletta, 2001; Dimareli-Malli *et al.*, 2013; Whittington *et al.*, 2013), pero la mayoría de cepas requieren además la presencia de un factor de crecimiento, la micobactina, en el entorno para su multiplicación (Juste *et al.*, 2000a; Whittington *et al.*, 2013). La identificación tradicional de *Map* se ha basado en su capacidad para crecer *in vitro* en medios de cultivo con huevo y micobactina (Juste *et al.*, 1991; Stevenson, 2015) y en la detección de la secuencia de inserción IS900 o IS1331 (Collins *et al.*, 1989; Green *et al.*, 1989; Whittington *et al.*, 2001a; Stevenson *et al.*, 2002; Castellanos *et al.*, 2009).

2.1.2. Cepas de *Map*

A pesar de que se conoce, desde hace décadas, la existencia de diferentes cepas de *Map* (Taylor, 1951), el estudio de su variabilidad genética y su clasificación en tipos y subtipos, solo ha sido posible gracias al desarrollo

de las técnicas de biología molecular. La diferenciación entre *Map* y otras subespecies de *M. avium* se basa en la detección de secuencias de inserción específicas como la IS900 (Green *et al.*, 1989; Stevenson *et al.*, 2002; Castellanos *et al.*, 2009) o ISMav2 (Strommenger *et al.*, 2001) o en la identificación de poliformismos de IS1311 (Whittington *et al.*, 2001a). La tipificación de distintas cepas dentro de la subespecie *Map* se ha realizado también mediante pruebas genéticas como el análisis de polimorfismos de la longitud de fragmentos de restricción (RFLP) sobre la secuencia de inserción IS900, tras la digestión del ADN cromosómico con diferentes enzimas (IS900-RFLP) (Saunders *et al.*, 2003). También se ha empleado la técnica de electroforesis en gel de campo pulsado (PFGE), más sofisticada y que permite una mayor definición en la comparación de moléculas de ADN, gracias a su comportamiento en la electroforesis frente a campos eléctricos de voltaje variable (Stevenson *et al.*, 2002, 2009; Sevilla *et al.*, 2007; Biet *et al.*, 2012). Concretamente, para el estudio de la variabilidad de *Map* se ha utilizado la digestión con las enzimas *Sna*BI y *Spe*I previamente a la electroforesis (Stevenson *et al.*, 2002; de Juan *et al.*, 2005; Sevilla *et al.*, 2007). Para la diferenciación entre aislados, se ha utilizado la reacción en cadena de la polimerasa con endonucleasas de restricción (PCR-REA). En este caso, la tipificación de cepas se basa en el fragmento IS1311 presente en *Map* y en otras micobacterias, con polimorfismos en función de la cepa ovina, bovina y de bisonte (Marsh *et al.*, 1999; Sevilla *et al.*, 2007; Stevenson, 2015).

2.1.2.1. Tipos de cepas de *Map*

Mediante las técnicas moleculares citadas, se han identificado hasta el momento, dos grupos principales de cepas que, además de diferencias a nivel molecular, se relacionan con la especie a partir de la cual fueron aisladas: las cepas identificadas en ovinos conocidas como “Tipo S (Sheep-type u ovinas)”

y las “Tipo C (Cattle- type o bovinas)”, procedentes de bovinos (Collins *et al.*, 1990; Whittington *et al.*, 2001a; Stevenson, 2015).

Las cepas ovinas o Tipo S y las bovinas o Tipo C tienen, respectivamente, idéntica significación que las cepas Tipo I y Tipo II definidas con posterioridad mediante la técnica PFGE (Stevenson *et al.*, 2002; Stevenson, 2015). Otras cepas como las aisladas de camélidos (Ghosh *et al.*, 2012) se incluyen como un subtipo dentro de las cepas ovinas o Tipo S (Stevenson *et al.*, 2002). Un tercer grupo de cepas denominado “intermedio” o “Tipo III”, que se consideró en un principio intermedio entre los genotipos S y C, actualmente se clasifica como otro subtipo de las cepas Tipo S (Stevenson, 2015). Asimismo, se ha descrito un tercer genotipo o “Tipo B” (Bison-type), aislado en bisontes americanos (Whittington *et al.*, 2001a) y de la india (Sohal *et al.*, 2010). Sin embargo, hoy se considera que estos aislados son subtipos dentro del Tipo C o bovino (Thibault *et al.*, 2012; Stevenson, 2015) (Figura 1). En cabras, mediante PFGE, IS900 e IS1331- RFLP, se han identificado tanto cepas C (Tipo II) como cepas S (Tipo III) (de Juan *et al.*, 2005; Sevilla *et al.*, 2007).

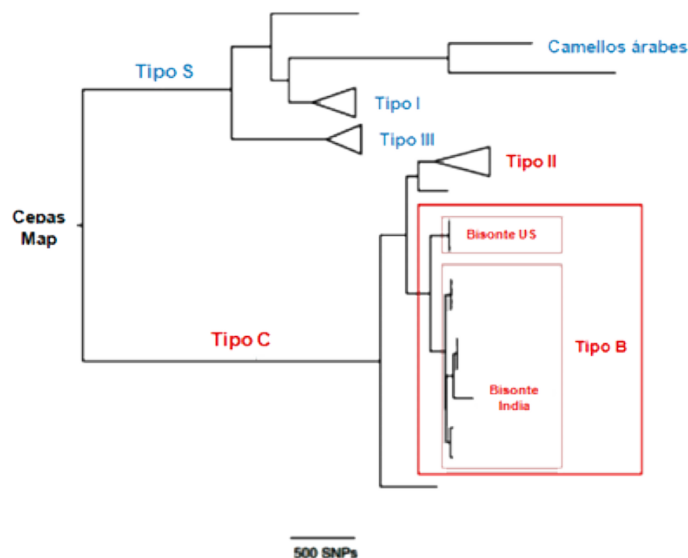


Figura 1: Esquema representativo de los diferentes tipos de cepas de *Map* (modificado de Stevenson, 2015).

Estas diferencias genéticas entre las cepas de *Map* se traducen en una variabilidad fenotípica en cuanto a sus características de crecimiento, rango de hospedadores, pigmentación de la cepa, virulencia y, en definitiva, en la presentación de la enfermedad (Manning y Collins, 2001; Stevenson, 2015). Generalmente, las cepas Tipo C son más fáciles de aislar y crecen relativamente rápido, produciendo colonias visibles en 4-6 semanas; por el contrario, las cepas Tipo S son más difíciles de aislar, más lentas en su crecimiento y necesitan entre 16 y 52 semanas para poderse observar algún crecimiento (Manning y Collins, 2001; Whittington *et al.*, 2011; Stevenson, 2015).

Aunque ambas cepas crecen en medio Middlebrook 7H9 ó 7H11, el medio más adecuado para su aislamiento primario es el 7H11, suplementado con micobactina J (Dimareli-Malli *et al.*, 2013). Al contrario que las cepas bovinas, las ovinas crecen con dificultad en el medio Herrold's e incluso, se puede inhibir dicho crecimiento en presencia de piruvato (Whittington *et al.*, 2011; Dimareli-Malli *et al.*, 2013). Para su aislamiento se ha recomendado el medio de Löwenstein-Jensen sin piruvato (Juste *et al.*, 1991; de Juan *et al.*, 2006; Whittington *et al.*, 2011).

El tamaño y color de la colonia depende del medio de cultivo utilizado y no varía entre los distintos tipos de cepas (Whittington *et al.*, 2011; Dimareli-Malli *et al.*, 2013). Se han aislado cepas ovinas que producen un pigmento brillante amarillento o anaranjado, tanto en cultivo como tras la infección en el animal vivo (Taylor, 1945; Benazzi *et al.*, 1996; Stevenson *et al.*, 2002). Inicialmente, la coloración de esta cepa se consideró como una característica de las cepas Tipo I pero, posteriormente se descartó ya que se han identificado otras no pigmentadas del mismo tipo (Stevenson, 2015) y también se han descrito cepas pigmentadas pertenecientes al Tipo III (Biet *et al.*, 2012).

2.1.2.2. Variabilidad epidemiológica de las cepas

Aparte de las propiedades anteriores, también se observan diferencias epidemiológicas, particularmente en la preferencia de las cepas por determinados hospedadores. Las cepas bovinas o Tipo C están presentes en un mayor rango de hospedadores, desde rumiantes domésticos o salvajes hasta otros no rumiantes (Motiwala *et al.*, 2004; Hutchings *et al.*, 2010). Asimismo, existen evidencias de la infección cruzada con cepas C entre especies de rumiantes domésticos en contacto con rumiantes silvestres (Stevenson *et al.*, 2009; Fritsch *et al.*, 2012) y entre grandes y pequeños rumiantes en la misma granja (Stevenson *et al.*, 2009; Dimareli-Malli, 2013). Las del subtipo B no solo se encuentran en bisontes sino que también se han aislado en otras especies domésticas e incluso en humanos (Sevilla *et al.*, 2005; Yadav *et al.*, 2008; Singh *et al.*, 2009). Las cepas Tipo S se han aislado preferentemente de pequeños rumiantes, aunque se ha demostrado experimentalmente que reproducen la enfermedad clínica en el ganado vacuno (Taylor, 1953) y en ciervos (O'Brien *et al.*, 2006). La transmisión natural de cepas Tipo S de ovejas a vacas se ha documentado en Australia e Islandia (Whittington *et al.*, 2001b; Whittington y Sergeant, 2001) a pesar de que se creía que el riesgo era mínimo y solo en casos de una dosis infectante elevada (Moloney y Whittington, 2008). Un estudio reciente ha sugerido que esta transmisión no sería tan infrecuente si ambas especies están en contacto en la misma granja (Verdugo *et al.*, 2014). Este estudio reflejó que las cepas Tipo S eran las predominantes entre el ganado vacuno de carne y ovino que compartían pastos en Nueva Zelanda.

2.1.2.3. Variabilidad en la virulencia de las cepas

Son escasas las referencias en la bibliografía en las que se relaciona el genotipo de la cepa con su virulencia y la patogenia de la enfermedad, en parte debido a la dificultad para valorar estos aspectos en condiciones

naturales, y por otro lado, a los diferentes criterios empleados en los modelos experimentales.

Ya en 1954 Stamp y Watt (Stamp y Watt, 1954), observando la gravedad de las lesiones inducidas, señalaron que las cepas ovinas pigmentadas tenían una virulencia mayor que las cepas ovinas no pigmentadas. Más recientemente, algunos estudios experimentales han puesto de manifiesto que las cepas Tipo C son más virulentas para el ciervo que las S, o que los ciervos son más resistentes a las cepas ovinas (O'Brien *et al.*, 2006). También se ha comunicado que, en condiciones experimentales, las cepas Tipo S serían más virulentas para los propios hospedadores ovinos, al compararlas con las cepas del Tipo C, también en la especie ovina (Stevenson, 2015). En otro estudio, si bien no se utilizaron cepas tipificadas, también se han documentado diferencias en la patogenicidad tras una infección experimental en corderos empleando cepas bovinas y ovinas. Las lesiones más graves las produjeron las cepas ovinas y dentro de las bovinas, aquellas aisladas en Argentina resultaron más patógenas que el aislado de campo de España (Verna *et al.*, 2007).

2.2. Epidemiología, diagnóstico y control

La paratuberculosis afecta principalmente a rumiantes, tanto domésticos como salvajes (Chiodini *et al.*, 1984; Motiwala *et al.*, 2004; Hutchings *et al.*, 2010; Stevenson, 2015). Con el paso de los años, se ha comprobado que el abanico de hospedadores es mucho mayor, incluyendo también a monogástricos (Kennedy y Benedictus, 2001; Beard *et al.*, 2001a; Maio *et al.*, 2011). Esta enfermedad adquiere mayor importancia en el ganado vacuno (*Bos taurus*), ovino (*Ovis aries*) y caprino (*Capra hircus*) donde se ha estudiado en profundidad, por tener ésta un mayor impacto económico en la producción animal (Chiodini *et al.*, 1984; García y Shalloo, 2015; Windsor, 2015). Los efectos económicos que origina, aunque variables, se

estima que son altos y se deben a la pérdida directa de los animales por muerte o sacrificio prematuro y a los descensos de la productividad del rebaño, tales como la reducción en la eficiencia de conversión, la disminución de la producción lechera y el incremento en la frecuencia de aparición de problemas de fertilidad y mamitis (Ott *et al.*, 1999; Johnson-Ifearulundu *et al.*, 2000; Lombard *et al.*, 2005; Raizman *et al.*, 2009; Richardson y More, 2009; García y Shalloo, 2015).

El contagio entre los animales se produce principalmente de forma fecal-oral (Stehman, 1996; Sweeney, 1996; Clarke, 1997), mediante la ingestión de la micobacteria presente en el medio, agua, leche o calostro y en general, en cualquier alimento contaminado por las heces de los animales infectados (Lambeth *et al.*, 2004; Diéguez *et al.*, 2008; Kudahl *et al.*, 2008; Lombard, 2011; Doré *et al.*, 2012; Pérez *et al.*, 2012) aunque tampoco puede descartarse la vía vertical a través del calostro o leche (Stabel *et al.*, 2014; McAloon *et al.*, 2016) y de la placenta (Sweeney, 1996; Kennedy y Benedictus, 2001; van Kooten *et al.*, 2006). La infección se produce principalmente en edades tempranas, en los lactantes, fundamentalmente en los primeros días de vida, cuando los animales ingieren los bacilos presentes en los pezones y la ubre o en el material de cama contaminados con heces de animales excretores (Clarke, 1997; Barkema *et al.*, 2009; Pérez *et al.*, 2012). Se ha demostrado que existe una resistencia a la enfermedad asociada a la edad, de forma que aunque los animales adultos pueden infectarse, en ellos la infección no progresa (Larsen *et al.*, 1975; Chiodini *et al.*, 1984; Clarke, 1997; Delgado *et al.*, 2012).

En algunos estudios se ha documentado el riesgo de transmisión entre los ovinos y bovinos, especies que padecen esta enfermedad con mayor frecuencia (Whittington *et al.*, 2001b; Moloney y Whittington, 2008; Verdugo *et al.*, 2014). Asimismo también se ha demostrado la infección interespecie

con el aislamiento de la misma cepa de *Map* en pequeños rumiantes y en animales monogástricos de la misma zona (Florou *et al.*, 2008) o al aislar cepas ovinas y bovinas en el intestino de ciervos en Nueva Zelanda (Verdugo *et al.*, 2014).

La paratuberculosis es una enfermedad con distribución mundial que puede alcanzar valores elevados de prevalencia, incluso superiores al 30 % en explotaciones bovinas (Juste *et al.*, 2000b; Balseiro, 2004; Diéguez *et al.*, 2007; Donat *et al.*, 2014) y ovinas (Adúriz *et al.*, 1994; Coelho *et al.*, 2007; Bauman *et al.*, 2016a) que varía entre los distintos países y regiones, depende de varios factores como son la aptitud del rebaño, la edad de los animales, el manejo y las condiciones del establo, los métodos de diagnóstico y las medidas llevadas a cabo para controlarla (Nielsen y Toft, 2009).

Los métodos de diagnóstico más utilizados en el diagnóstico de la paratuberculosis son aquellos basados en la detección e identificación de *Map* en los animales, en la identificación histológica de las lesiones características y en la detección de la respuesta inmunológica específica desencadenada por el hospedador frente a *Map*.

La presencia de *Map* en el animal infectado puede determinarse mediante el frotis a partir de muestras de heces o tejidos que permite observar la presencia de BAAR mediante la tinción de ZN (Weber *et al.*, 2009; Rawther *et al.*, 2012), aunque su especificidad es muy baja y su sensibilidad es escasa en animales no excretadores en las fases subclínicas (Zimmer *et al.*, 1999; Weber *et al.*, 2009). El cultivo bacteriológico de heces es un procedimiento muy específico pero que depende de si los animales están excretando o no micobacterias (Whittington *et al.*, 2000; Laurin *et al.*, 2015; Mortier *et al.*, 2015). Los medios de aislamiento de *Map* más utilizados son el HEYM (*Herrold egg yolk medium*) (Aly *et al.*, 2010; Pozzato *et al.*, 2011), el Löwenstein-Jensen (Juste *et al.*, 1991; de Juan *et al.*, 2006; Florou *et al.*, 2009)

y otros sintéticos como el Middlebrook 7H9 (Adúriz *et al.*, 1995; Whittington *et al.*, 2013), 7H10 (Damato y Collins, 1990) o 7H11 (Dimareli-Malli *et al.*, 2013).

Los avances en la biología molecular han permitido identificar la presencia de *Map* mediante la reacción en cadena de la polimerasa (PCR). Se trata de una técnica de elevada sensibilidad y especificidad que permite identificar segmentos muy pequeños de ADN (Laurin *et al.*, 2015) y cuantificar (Schönenbrücher *et al.*, 2008) la presencia de *Map* a partir de muestras de tejido, heces (Bauman *et al.*, 2016b), leche o calostro (Gilardoni *et al.*, 2016) y sangre periférica (Irengue *et al.*, 2009; Kaur *et al.*, 2010; Singh *et al.*, 2010). La reacción puede identificar diferentes fracciones genéticas específicas de micobacterias como la secuencia de inserción IS900 (Green *et al.*, 1989; Castellanos *et al.*, 2009; Münster *et al.*, 2013) y otras específicas de *Map* como la F57 (Bosshard *et al.*, 2006; Keller *et al.*, 2014), el gen HspX (Ellingson *et al.*, 2000, 2005), o las secuencias de inserción ISMav2 (Strommenger *et al.*, 2001) e ISMap02 (Stabel y Bannantine, 2005; Sevilla *et al.*, 2014).

El diagnóstico anatomopatológico, basado en la observación de lesiones macro y microscópicas, es un método bastante útil para establecer un diagnóstico de la enfermedad ya que permite detectar tanto casos clínicos como subclínicos (Pérez *et al.*, 1996; González *et al.*, 2005; Gilardoni *et al.*, 2012; Sonawane y Tripathi, 2016a). Se puede complementar con la demostración de la presencia de *Map* o sus antígenos mediante las tinciones de ZN o inmunohistoquímicas, así como de biología molecular (Verin *et al.*, 2016). Las muestras de elección para realizar el estudio microscópico e identificar las lesiones causadas por *Map* (apartado 2.5.2. de este capítulo de revisión bibliográfica) son aquellas que contienen tejido linfoide asociado al intestino, como la válvula ileocecal, las placas de Peyer ileales y yeyunales y los nódulos linfáticos intestinales asociados ya que es en estas localizaciones

donde se observan las lesiones granulomatosas iniciales o latentes de la paratuberculosis (Pérez *et al.*, 1996; Corpa *et al.*, 2000; García Marín *et al.*, 2000; González *et al.*, 2005; Delgado *et al.*, 2013).

En la actualidad, las pruebas más empleadas para el diagnóstico *in vivo* de la paratuberculosis son las que detectan la respuesta inmunitaria adaptativa, celular o humoral, desarrollada por el hospedador en respuesta a la infección por *Map*.

El test de liberación de interferón-gamma (IFN- γ) o "IGRA" es la prueba inmunológica *in vitro* más empleada actualmente para medir la respuesta inmunitaria de tipo celular. Esta técnica mide los niveles del IFN- γ liberados por las células sanguíneas tras su estimulación con un derivado proteínico purificado (*Purified Protein Derivative*, PPD) de *Map* (PPD johnina) o *M. avium* (PPD aviar), que serían más elevados si el animal está sensibilizado frente a *Map* (Billman- Jacobe *et al.*, 1992; Pérez *et al.*, 1999; Delgado *et al.*, 2012; Mohamed *et al.*, 2013; Vázquez *et al.*, 2013). Otra alternativa para evaluar la inmunidad celular *in vivo* frente a *Map* es la prueba de la intradermorreacción (IDR) que permite cuantificar la respuesta de hipersensibilidad retardada de tipo IV que desarrolla el ganado tras la inoculación intradérmica de la PPD johnina o de la PPD aviar (Garrido *et al.*, 2002; Benedictus y Kalis, 2003; Rawther *et al.*, 2012). La mayor respuesta a estas técnicas se encuentra en animales en fases iniciales o latentes de la enfermedad, disminuyendo el número de individuos positivos en las etapas clínicas (Pérez *et al.*, 1999; Storset *et al.*, 2001; Begg *et al.*, 2010; Köhler *et al.*, 2015; Dukkupati *et al.*, 2016).

Por su parte, la respuesta humoral frente a *Map* se valora generalmente mediante el test de ELISA cuantificando los niveles de anticuerpos específicos de *Map* en suero sanguíneo o muestras de leche (Nielsen y Toft, 2008). Es una técnica sencilla en su ejecución además de

barata y económica, capaz de automatizarse como herramienta de diagnóstico ordinario (Garrido, 2001). Si bien es cierto que la sensibilidad es elevada en animales en fases avanzadas de la enfermedad con lesiones difusas (espectro lepromatoso), signos clínicos o excretores (Pérez *et al.*, 1997; Nielsen y Toft, 2008; Mohamed *et al.*, 2013; Vázquez *et al.*, 2013), el rendimiento en la identificación de los animales en fases iniciales de la infección es menor (Harris y Barletta, 2001).

Las medidas de control habituales se centran en el establecimiento de medidas higiénico-sanitarias preventivas que eviten la propagación de la enfermedad en el rebaño evitando el contacto entre animales infectados con aquellos más susceptibles, en este caso, los recién nacidos y la recría (Groenendaal *et al.*, 2002; Bennett *et al.*, 2010; Dorshorst *et al.*, 2006; Ritter *et al.*, 2016). Dado que no existe un tratamiento quimioproláctico adecuado (Fecteau y Whitlock, 2011), para conseguir una mayor eficacia, se ha sugerido que las medidas de manejo higiénico-sanitarias deberían combinarse con el empleo de las técnicas diagnósticas disponibles para diagnosticar los animales infectados e identificar también aquellos excretores que suponen un mayor riesgo epidemiológico (Khol y Baumgartner, 2012; Geraghty *et al.*, 2014; Windsor *et al.*, 2014; Ritter *et al.*, 2016; Donat *et al.*, 2016). Sin embargo, el control basado en el empleo de pruebas diagnósticas tiene como principal limitación su reducida sensibilidad, puesto que los métodos empleados hasta el momento no son capaces de identificar a todos los animales infectados (Olsen *et al.*, 2002; More *et al.*, 2015).

Se ha demostrado que la vacunación es una herramienta muy eficaz como método de control de la paratuberculosis (Juste y Pérez, 2011). Más que evitar que el animal se infecte, permite un freno a la progresión de la infección lo que se traduce en una disminución en la aparición de nuevos casos clínicos, una reducción en la excreción fecal de *Map* y una mejora de los

parámetros productivos (Juste *et al.*, 1994; Juste y Pérez, 2011; Alonso-Hearn *et al.*, 2012; Thakur *et al.*, 2013). También se ha sugerido que la vacunación podría tener efectos terapéuticos en animales que ya estaban infectados (Corpa *et al.*, 2000; Alonso-Hearn *et al.*, 2012; Santema *et al.*, 2013; Singh *et al.*, 2013). Sin embargo, su empleo no está permitido en el ganado vacuno en la mayoría de países, debido a las interferencias con los programas de erradicación de la tuberculosis (Bezós *et al.*, 2012).

2.3. Patogenia

A pesar de que la paratuberculosis es una enfermedad conocida desde finales del siglo XIX (Johnes y Frothingham, 1895), todavía se desconocen muchos aspectos importantes de su patogenia (Stevenson, 2015). Entre los factores que obstaculizan su estudio se encuentran la complejidad para el aislamiento del agente, el elevado periodo de incubación de la enfermedad y los problemas para reproducir la paratuberculosis natural en condiciones experimentales (Chiodini *et al.*, 1984; Coussens, 2001; Hines II *et al.*, 2007; Begg y Whittington, 2008).

Aún así, son numerosas las infecciones experimentales que se han llevado a cabo (Hines II *et al.*, 2007; Begg y Whittington, 2008) y que han permitido estudiar la interacción que se produce entre *Map* y el hospedador, crucial para determinar la evolución de la infección (Clarke, 1997; Arsenault *et al.*, 2014; Koets *et al.*, 2015). En estos estudios, se ha podido determinar que la respuesta de los animales varía, de forma que hay individuos que acaban enfermando, en otros la infección persiste en forma latente durante años o incluso toda la vida del animal, e incluso hay animales que la superan, sin que se conozcan con exactitud qué factores condicionan que se desencadene uno u otro final (Clarke, 1997; Sweeney, 2011; Pérez *et al.*, 2012). Algunos de los propuestos han sido la virulencia de la cepa, la vía de infección, dosis infectiva, estado inmunitario del hospedador, desnutrición,

infecciones concomitantes, la edad o la raza (Clarke, 1997; Vir Singh *et al.*, 2013; Koets *et al.*, 2015).

2.3.1. Interacción patógeno-hospedador

Los animales jóvenes son más susceptibles a la infección, producida por vía oral fundamentalmente, penetrando en el hospedador a través del intestino (Momotani *et al.*, 1988; Sigurdardóttir *et al.*, 2004; Bannantine y Bermúdez, 2013). Una vez en la luz intestinal, y previamente a su entrada, *Map* es captada por las células epiteliales del intestino (Ponnusamy *et al.*, 2013; Koets *et al.*, 2015) especialmente por las células M, una población de células epiteliales especializadas que se localizan en el epitelio asociado a los folículos linfoides de las placas de Peyer del intestino (Momotani *et al.*, 1988; Sigurdardóttir *et al.*, 2001, 2004). Entre sus funciones destaca la captación y el transporte de los microorganismos desde la luz intestinal hasta el tejido linfoide subyacente mediante vacuolas de endocitosis, con el fin de desencadenar una respuesta inmunitaria frente a ellos (Miller *et al.*, 2007; Corr *et al.*, 2008).

La adherencia y el paso hasta alcanzar la submucosa ocurre de forma muy rápida (Sigurdardóttir *et al.*, 2001). Para ello, se ha descrito que *Map* presenta unas adhesinas de membrana entre las que destacan las “proteínas de acoplamiento a la fibronectina” (FAP) y el factor de elongación (EF-Tu), ubicadas en la superficie del bacilo y que parecen conferirle la capacidad de unirse a la fibronectina, proteína de la matriz extracelular de las células epiteliales (Secott *et al.*, 2002; Bannantine *et al.*, 2003; Lee *et al.*, 2009a; Viale *et al.*, 2014). Las células M presentan en su polo apical integrinas $\beta 1$, que actúan como receptores del puente de unión FAP-fibronectina (Secott *et al.*, 2002, 2004) (Figura 2). La eficiencia en la adhesión estaría directamente relacionada con la cantidad de FAP, y la unión FAP-fibronectina se vería favorecida por el paso del bacilo por un medio con pH ácido (Secott *et al.*,

2001, 2002). Esto explicaría la predilección de *Map* por entrar a través de estas células (Sigurdardóttir *et al.*, 2001). Se asume que esta vía de entrada no es exclusiva, ya que se ha demostrado el paso de la micobacteria a través de la invasión directa de los enterocitos (Pott *et al.*, 2009; Bermúdez *et al.*, 2010; Ponnusamy *et al.*, 2013) o por vía hematógena desde la luz intestinal (Chiodini, 1996; Sigurdardóttir *et al.*, 1999, 2001) aunque se estima que estas vías son poco frecuentes y no serían importantes.

Una vez atravesada la barrera del epitelio intestinal, el bacilo es transportado intacto por endocitosis dentro de vacuolas sin enzimas hidrolíticas y posteriormente fagocitado por macrófagos intraepiteliales y subepiteliales que han sido activados, adyacentes a las placas de Peyer (Sigurdardóttir *et al.*, 1999, 2001; Coussens, 2001; Tessema *et al.*, 2001). A continuación, *Map* es transportado hacia las zonas interfoliculares del tejido linfoide, donde sus antígenos son presentados por las células presentadoras de antígeno (CPA) a los linfocitos T, lo que desencadena una respuesta inmunitaria (García Marín *et al.*, 1992; Stabel, 2000a; Lee *et al.*, 2009a). Una vez dentro de los macrófagos, *Map* dispone de diversas estrategias para evitar su destrucción, poder replicarse y así diseminarse por el organismo.

En la mayoría de los casos, los macrófagos son activados rápidamente y disponen de una serie de mecanismos antimicrobianos capaces de eliminar o controlar la multiplicación de los patógenos fagocitados (Mills *et al.*, 2000; Sica y Mantovani, 2012; Martínez y Gordon, 2014; Davies y Taylor, 2015). Sin embargo, se ha demostrado que *Map* es capaz de evadir esta reacción defensiva, estableciéndose una infección latente (Sigurdardóttir *et al.*, 2001; Tessema *et al.*, 2001; Woo y Czuprynski, 2008). Entre las estrategias que confieren a la micobacteria esa propiedad de resistencia frente a la acción de macrófagos cabe destacar: a) la inhibición de la maduración de fagosoma a fagolisosoma (Hostetter *et al.*, 2003; Kang *et al.*, 2005; Arsenault *et al.*, 2014),

b) la disminución de la función bactericida de los macrófagos asociada a la complejidad de su pared bacteriana (Zhao *et al.*, 1997; Harris y Barletta, 2001; Tessema *et al.*, 2001), c) la inhibición de la acidificación del fagosoma-lisosoma por medio de la reducción de los sistemas oxidativos, en particular de la producción de óxido nítrico (NO) y de óxido nítrico sintasa (NOS) (Kuehnel *et al.*, 2001; Miller *et al.*, 2004; Weiss *et al.*, 2004; Woo y Czuprynski, 2008; Pakhomova *et al.*, 2009) d) la activación de la proteína quinasa mitógena-activa p38 (MAPkp38) (Souza, 2015), e) el bloqueo o alteración de la ruta normal de apoptosis (Weiss *et al.*, 2004; Kabara y Coussens, 2012; Abendaño *et al.*, 2013; Arsenault *et al.*, 2014) y f) la reducción de la expresión de antígenos inmunogénicos en su estructura, denominados formas de resistencia o formas L (formas de pared defectiva o esferoplastos) (Hines II y Styer, 2003; Beran *et al.*, 2006; Hines II *et al.*, 2007).

Además, se ha observado que *Map* es capaz de inhibir la presentación de antígenos a los linfocitos T (Weiss *et al.*, 2001) y tras la infección en el ganado ovino la expresión del complejo mayor de histocompatibilidad de tipo II (MHCII) y de integrinas tipo LFA-1 se ve reducida, lo que podría estar relacionado con la supervivencia intracelular de la micobacteria y con la latencia de la infección (Alzuherri *et al.*, 1997). Por lo tanto, el que la micobacteria sea destruida, va a depender principalmente de la acción de los **macrófagos**, en concreto de su grado de activación (García Marín *et al.*, 2000; Arsenault *et al.*, 2014), de manera que se produce entonces una compleja interacción entre los diferentes procesos inmunológicos, a veces contrapuestos, que va a tener como resultado que, o bien los macrófagos destruyan la micobacteria y por lo tanto el animal supere la infección, o que la micobacteria logre sobrevivir, lo que conducirá a que el animal desarrolle la enfermedad clínica o permanezca durante largos periodos de vida como portador asintomático de la infección, excretando o no bacilos (Chiodini *et al.*, 1984; Thorel *et al.*, 1992; Clarke, 1997; Storset *et al.*, 2001).

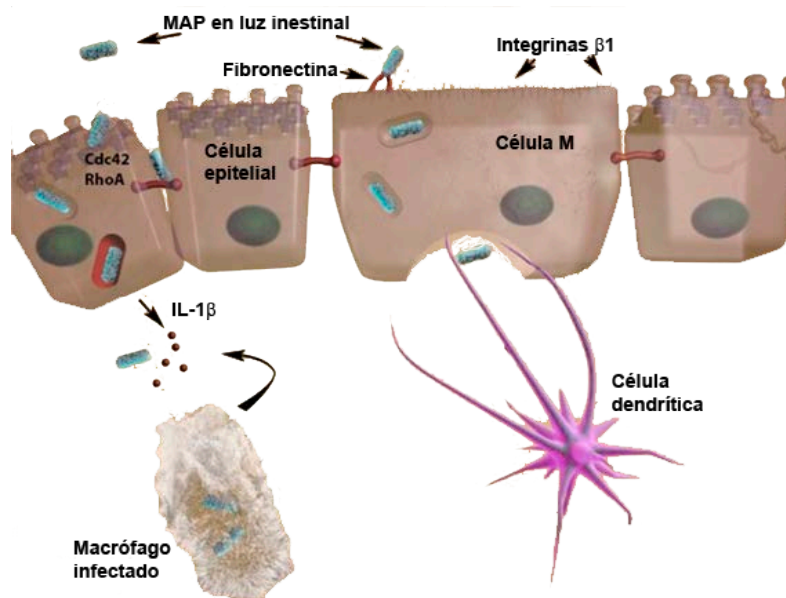


Figura 2: Interacción de *Map* con las células del epitelio intestinal y paso a la lámina propia de la mucosa donde es fagocitado por los macrófagos (tomado de Bannantine y Bermúdez, 2013).

2.3.2. Respuesta inmunitaria

Map es un patógeno intracelular que, como se ha detallado, tiene mecanismos para evadir la respuesta inmunitaria innata del hospedador, evitando los procesos que tienen lugar tras su fagocitosis por los macrófagos para lograr su destrucción (Cheville *et al.*, 2001; Kuehnel *et al.*, 2001; Hostetter *et al.*, 2002, 2003; Tooker *et al.*, 2002; Weiss *et al.*, 2004; Kang *et al.*, 2005; Koets *et al.*, 2015). La modulación inmunológica es, en parte, inducida por los diferentes antígenos de *Map*, entre los que parecen destacar el polisacárido LAM, las proteínas de choque térmico, que son presentadas por el MHCII a los linfocitos T (Stabel, 2000a) y la proteína de 35 kDa como principal factor de virulencia (Bannantine *et al.*, 2003). Se produce entonces una compleja interacción entre los diferentes procesos inmunológicos, en ocasiones contrapuestos, que va a tener como resultado que los macrófagos destruyan la micobacteria y por lo tanto el animal supere la infección, o que la micobacteria logre sobrevivir, lo que conducirá a que el animal desarrolle la

enfermedad clínica o permanezca como portador asintomático de la infección (Chiodini *et al.*, 1984; Thorel *et al.*, 1992; Whitlock y Buergelt, 1996; Clarke, 1997; Storset *et al.*, 2001).

En el control de la infección por *Map* participan las dos ramas principales de la respuesta inmunológica: la innata y la adquirida (Koets *et al.*, 2015). Durante varios años, se ha pensado que ambas respuestas ejercían sus funciones y desarrollaban sus mecanismos de manera totalmente separada e independiente; sin embargo, se ha demostrado que ambos tipos de respuesta actúan de forma conjunta, y no solo pueden ser concomitantes y solaparse, sino que también pueden interactuar entre sí para mejorar la eficiencia antimicrobiana, como sucedería en el caso de la paratuberculosis (Orme, 2004; Sohal *et al.*, 2008).

2.3.2.1. Respuesta inmunitaria de tipo innato

La respuesta inmunitaria de tipo innato ha suscitado un considerable interés durante los últimos años por ser la primera defensa efectora tras la interacción con cualquier microorganismo potencialmente patógeno. El objetivo de este tipo de respuesta no solo es contener la infección sino que es un mecanismo de regulación, para que la respuesta inmunitaria adaptativa se encamine hacia un tipo de respuesta concreta (Vasselon y Detmers, 2002; Kleinnijenhuis *et al.*, 2011; Arsenault *et al.*, 2014, Johnson *et al.*, 2014). En la paratuberculosis y tras la infección natural, comienza un periodo de tiempo variable en el que los animales permanecen en una fase asintomática (que puede alcanzar los dos años en el ganado bovino), en la que no es posible observar una respuesta inmunológica adaptativa diferenciada, ni detectar la excreción de la bacteria en heces (Clarke, 1997; Sweeney, 2011).

La respuesta inmunitaria innata comienza con el reconocimiento de moléculas básicas o estructurales denominadas patrones moleculares

asociados a patógenos (PAMP) como pueden ser los lipopolisacáridos de pared, lipoproteínas o proteínas transmembrana, presentes en la mayoría de los microorganismos (Uematsu y Akira, 2006). Este proceso tiene lugar gracias a una serie de receptores codificados genéticamente para el reconocimiento de patógenos (PRR), presentes en las células inmunitarias, que sirven para identificar los PAMPs y permiten que las bacterias sean fagocitadas una vez que entran en contacto con dichas células (Vasselon y Detmers, 2002; Uematsu y Akira, 2006; Kawai y Akira, 2007; Nalubamba *et al.*, 2008).

En el caso de la paratuberculosis, la respuesta inmunitaria innata se inicia con la fagocitosis llevada a cabo por los macrófagos subepiteliales, dotados de diversos receptores que participan en la respuesta innata como son los receptores de inmunoglobulinas (FcR), receptor de la manosa CD206, proteínas de membrana CD14 de unión a lípidos, receptores de transferrina, “scavenger receptors” y los receptores del complemento (CR), entre los que destaca el CR3, por ser uno de los participantes en la fagocitosis (Sohal *et al.*, 2008).

Uno de los principales grupos de PRR que participan en el reconocimiento de *Map* son los receptores “toll-like” (TLR) (Mucha *et al.*, 2009). Se trata de proteínas presentes en las células dendríticas y los macrófagos, principales CPA, y que a pesar de considerarse superficiales, unen el compartimento extracelular con el intracelular (Vasselon y Detmers, 2002). Tras la interacción de los lipopolisacáridos (LPS) y lipoproteínas (LPP) de las micobacterias con los TLR, tiene lugar una cascada de señales intracelulares que inducen la producción de citocinas así como de reactivos nitrogenados y oxidativos intermediarios, para intentar contener o eliminar la infección (Fewerda *et al.*, 2007). Además, y gracias a los productos derivados de esa respuesta innata, los TLRs también participarían en la activación y regulación de la respuesta de tipo adaptativo (Jo *et al.*, 2007; Kawai y Akira,

2007) ya que permitirían a las CPA reconocer a los patógenos e iniciar una adecuada respuesta inmunitaria específica (Stabel, 2006). En mamíferos se han identificado al menos 13 familias de TLRs que reconocen los principales PAMPs de patógenos (Tabeta *et al.*, 2004; Oshiumi *et al.*, 2008). De ellos, hay seis familias TLR1, TLR2, TLR4, TLR5, TLR 6 y TLR9, que reconocen componentes celulares bacterianos, fúngicos o protozoarios, entre ellos *Map* (Mucha *et al.*, 2009; Fisher *et al.*, 2011).

Sin embargo, el mecanismo, funcionamiento y la relevancia del sistema TLR en la defensa contra *Map* es complejo y aún existe incertidumbre sobre el papel preciso que puedan ejercer. Se sabe que los TLR2 reconocen lipoproteínas y lipopolisacáridos de la pared celular micobacteriana (Schwandner *et al.*, 1999) pero su funcionamiento aún es controvertido. Por un lado, su activación podría suprimir la respuesta inmunitaria y se asociaría con una mayor susceptibilidad frente a *Map* (Noss *et al.*, 2001; Weiss *et al.*, 2008; Mucha *et al.*, 2009) o, en cambio, ejercería un efecto protector frente a *Map* al favorecer aquellos mecanismos intracelulares antibacterianos proinflamatorios (Stenger y Modlin, 2002; Iwasaki y Medzhitov, 2004). En este sentido, también se ha demostrado que ciertos polimorfismos de nucleótido simple (SNP) en el receptor TLR4 estarían asociados con una mayor susceptibilidad a la infección por *Map* (Fewerda *et al.*, 2007; Sharma *et al.*, 2015). Asimismo, se ha demostrado que mutaciones en polimorfismos de estos receptores suponen una mayor susceptibilidad a la infección tanto en ganado bovino (Mucha *et al.*, 2009; Ruiz-Larrañaga *et al.*, 2011) como ovino (Bhide *et al.*, 2009). La activación de otros TLRs, como TLR9, parece que inicia respuestas que son críticas en la defensa contra *Map* (Bafica *et al.*, 2005). Específicamente, los TLR9 que reconocen y se unen al ADN micobacteriano (Vasselon y Detmers, 2002), se ha comprobado que muestran una mayor expresión en ovejas sin signos clínicos que en animales con paratuberculosis clínica (Nalubamba *et al.*, 2008). De forma similar, se ha descrito que en casos

de tuberculosis, TLR9 desempeñaría un papel importante en la transición de la respuesta innata y adaptativa, ya que su activación favorecería la secreción de IL-12, principal citocina inductora de la respuesta inmunitaria de tipo Th1 (Pompei *et al.*, 2007).

En la respuesta innata frente al LPS de *Map* también intervienen unas proteínas denominadas NOD-like receptors -NOD1, NOD2 y RP105-, que se asemejan estructural y funcionalmente a los TLRs (Vasselon y Detmers, 2002). Son proteínas citosólicas y podrían funcionar como activadoras de la respuesta inmunitaria para un amplio rango de patógenos (Vasselon y Detmers, 2002). Estos receptores intracelulares serían los encargados de reconocer diferentes moléculas procedentes de agentes patógenos y desencadenar una respuesta por parte de la célula, es decir, actuarían como equivalentes funcionales intracelulares de los TLRs (Vasselon y Detmers, 2002). De hecho, ambos receptores pueden actuar de forma conjunta, como el caso del receptor RP105, que es expresado principalmente por células B periféricas maduras (Miyake *et al.*, 1995) y se cree que se asociaría a TLR4 para desarrollar una respuesta humoral frente al LPS de *Map* (Ogata *et al.*, 2000, Subharat *et al.*, 2012). En la especie humana, estas moléculas intracelulares parece que intervienen en la patogenia de las inflamaciones crónicas del aparato digestivo, ya que mutaciones en el receptor NOD2 se han relacionado con la susceptibilidad a padecer la enfermedad de Crohn (Hugot *et al.*, 2001; Elguezábal *et al.*, 2012).

Otra proteína con un importante papel en la inmunidad innata frente a micobacterias es la “proteína de macrófago asociada a la resistencia natural” (Natural resistance-associated macrophage protein 1 o NRAM1) y cuya alteración se asociaría a una mayor susceptibilidad a la infección (Bellamy, 1999; Pinedo *et al.*, 2009). Tras la fagocitosis de *Map* por macrófagos y neutrófilos, NRAM1 es reclutada desde el citosol hacia la

membrana del fagosoma e interviene en su maduración participando de forma activa en la eliminación del agente (Frehel *et al.*, 2002). Se cree que esta proteína influye en la replicación intracelular de las micobacterias ya que modifica el pH del fagosoma (Hackam *et al.*, 1998) e impide su maduración (Frehel *et al.*, 2002). Además NRAMP1 transporta hierro (Fe^{2+}) a través de la membrana del fagosoma y favorece su depleción en el interior, lo cual podría privar a la micobacteria de este micronutriente, esencial en su metabolismo (Blackwell *et al.*, 2001, 2003). Esta proteína también favorece la producción de NO, molécula con actividad antimicrobiana (Fritsche *et al.*, 2003).

Los linfocitos T $\gamma\delta$ son otras células que ejercen un papel fundamental en las primeras fases de la respuesta innata en infecciones por agentes que circulan por el intestino de rumiantes jóvenes (Sohal *et al.*, 2008; Baquero y Plattner, 2016). Estos linfocitos se acumulan principalmente en los epitelios, lo que les permite actuar de una forma inmediata frente a los microorganismos (Corpa *et al.*, 2001; Koo *et al.*, 2004). Dentro de esta población de linfocitos, el subtipo “workshop cluster 1” (WC1+) expresaría PRRs, proteínas para identificar moléculas asociadas con patógenos microbianos (Hedges *et al.*, 2005) y no dependerían del MHCII para el reconocimiento antigénico (Hayday, 2000). Además, se ha sugerido que las altas concentraciones de células T $\gamma\delta$ WC1+ presentes en terneros permiten producir citocinas de tipo Th1 como la IL-12, TNF- α o IFN- γ que favorecen la respuesta inmunitaria celular adaptativa (Baldwin *et al.*, 2000; Baquero y Plattner, 2016).

También se ha propuesto que los receptores de IFN- γ expresados por los macrófagos y los linfocitos T $\gamma\delta$ puedan jugar un papel, puesto que su deficiencia genética o su disminución inducida podría explicar los niveles basales elevados de IFN- γ en sangre de animales con paratuberculosis (Geijo, 2007) y en pacientes con enfermedad de Crohn (Juste, 2010). No obstante,

otros autores atribuyen a las células T $\gamma\delta$ un papel inmunoregulador, que prevalece sobre el protector, y una actividad citotóxica para las células T CD4+ con la consiguiente inhibición de la respuesta adaptativa, favoreciendo la progresión de la infección paratuberculosa (Chiodini y Davis, 1992; Koets *et al.*, 2002).

2.3.2.2. Respuesta inmunitaria de tipo adaptativo

Una vez que la infección intracelular se ha instaurado, comienza la activación de una respuesta inmunitaria adquirida, de tipo específico y duradera, denominada respuesta inmunitaria adaptativa, mediada por los linfocitos T y B (Medzhitov y Janeway, 1997; Stabel, 2006). Las células T se clasifican en linfocitos T citotóxicos (Tc) y linfocitos T colaboradores (Th) (Kaufmann, 1991). Los linfocitos Tc presentan el marcador CD8 en su superficie y reconocen antígenos asociados al complejo mayor de histocompatibilidad de clase I (MHCI). Los linfocitos Th presentan el marcador CD4 en su superficie, reconocen antígenos presentados por el MHCII y su principal función consiste en amplificar la respuesta inmunitaria mediante la secreción de numerosas citocinas. Por su parte, los linfocitos B son los encargados de la producción de anticuerpos.

En particular, los linfocitos Th CD4+ se clasifican según los distintos fenotipos de producción de citocinas, entre los que destacan los denominados Th1 y Th2 por ser los más ampliamente estudiados (Stabel, 2006). Por un lado, los linfocitos Th1 secretan fundamentalmente TNF- α , IFN- γ , IL-2 y el factor estimulador de colonias de granulocitos-macrófagos (granulocyte-macrophage colony stimulating factor o GM-CSF), bajo la regulación de la IL-12 (Lee *et al.*, 2001; Sohal *et al.*, 2008; Sica y Mantovani, 2012). Las citocinas producidas por las células linfocitarias de perfil Th1 participan en la respuesta inmunitaria de tipo celular frente a microorganismos intracelulares, que son respuestas de tipo inflamatorio y

citotóxico, mediadas por células. En cambio, las células Th2 producen principalmente IL-4, IL-5, e IL-10 y estimulan la producción de anticuerpos por los linfocitos B, siendo los responsables de la respuesta humoral (Stabel, 2000a, 2006; Coussens, 2001; Kidd, 2003; Sohal *et al.*, 2008; Koets *et al.*, 2015).

La primera fase de la respuesta inmunitaria adaptativa tiene lugar una vez que *Map* ha sido fagocitada por los macrófagos, situados en relación con las células M, y sus antígenos presentados a los linfocitos T intraepiteliales y subepiteliales del intestino mediante su unión al MCHII (Chiodini, 1996; Sigurdardóttir *et al.*, 2001; Koets *et al.*, 2015). El antígeno sería reconocido por los linfocitos Th (Lugton, 1999), que a su vez se especializarían hacia una respuesta inmunitaria de tipo Th1 o celular, encargados de producir citocinas para estimular a los macrófagos y limitar así la proliferación micobacteriana. Por otro lado, estos linfocitos activados también pueden estimular, mediante la producción de diferentes mediadores celulares, la diferenciación y reclutamiento de nuevos linfocitos T para detener la proliferación bacteriana (Stabel, 2000a; Coussens, 2001; Coussens *et al.*, 2004).

Clásicamente se ha relacionado la respuesta de tipo celular con las primeras fases de la infección y la respuesta humoral con la etapa clínica de la paratuberculosis (Pérez *et al.*, 1997, 1999; Ostrowski *et al.*, 2003; Stewart *et al.*, 2004; Verna *et al.*, 2007; Begg *et al.*, 2010; Delgado *et al.*, 2012). Sin embargo, en otros trabajos se señala que el cambio entre respuesta Th1 y Th2 no sería tan marcado, desarrollándose ambas independientemente de la progresión de la enfermedad (Waters *et al.*, 2003; Begg *et al.*, 2011; Vázquez *et al.*, 2013).

A continuación se explican, de forma más detallada, los dos tipos principales de respuesta en que se divide la inmunidad de tipo adaptativo: la respuesta celular y humoral.

2.3.2.2.1. Respuesta inmunitaria celular

Esta rama de la respuesta inmunitaria se caracteriza por un microambiente en el que predominan citocinas de acción proinflamatoria, como son el IFN- γ , TNF- α , la IL-1 β , IL-6 e IL-17 (Alzuherrri *et al.*, 1996; Dinarello, 1996; Coussens *et al.*, 2004). Según el modelo de respuesta inmunitaria asociado a la infección paratuberculosa, ampliamente consensuado, en las primeras fases de la infección el animal desarrollaría una respuesta fundamentalmente de tipo celular sin producción de anticuerpos (Chiodini *et al.*, 1984), siendo las células T CD4+ Th1 y CD8+ las primeras en ofrecer protección (Kaufmann, 1991; Koo *et al.*, 2004). En esta fase, se ha descrito en los bovinos y ovinos una polaridad poblacional en la que prevalecen los linfocitos T CD4+ Th1 y $\gamma\delta$ WC1+, encargados de secretar las citocinas IFN- γ , TNF- α e IL-2, efectoras de la respuesta inmunitaria celular de carácter proinflamatorio, mientras que la población de linfocitos B sería residual (Begara-McGorum *et al.*, 1998; Weiss *et al.*, 2006). Se puede considerar al IFN- γ como la principal citocina efectora de tipo Th1. Además de participar en la diferenciación de las células que intervienen en este tipo de respuesta, es un potente inductor de la activación de los macrófagos (Stabel, 2000b, 2006; Koo *et al.*, 2004; Arsenault *et al.*, 2012). En el caso de la tuberculosis se ha demostrado que la administración o bloqueo exógeno de IFN- γ podría conferir, respectivamente, resistencia a la infección o favorecer el crecimiento micobacteriano (Cooper *et al.*, 1993, 1995), sugiriendo su importante papel en la inhibición del crecimiento de las micobacterias.

A pesar de que se considera una citocina esencial en la patogenia de la paratuberculosis, su verdadero papel no termina de esclarecerse. Se considera que una marcada secreción de IFN- γ en fases iniciales de la infección paratuberculosa se relaciona con el control de la enfermedad (Storset *et al.*, 2001; Begg *et al.*, 2009), de forma que se ha observado una

mayor secreción de IFN- γ en animales con infección paratuberculosa subclínica, mientras que cuando la infección progresa a una fase clínica, la producción periférica y local de esta citocina disminuye (Sweeney *et al.*, 1998; Stabel, 2000a, 2006; Koets *et al.*, 2015). De hecho, en pruebas de estimulación linfocitaria, la secreción de IFN- γ se utiliza como marcador en el diagnóstico de la respuesta inmunitaria celular, para la detección de animales positivos en fases tempranas tras la infección (Delgado *et al.*, 2012; Buendía *et al.*, 2013). Sin embargo, hay estudios que han descrito elevados niveles de IFN- γ en sangre que no serían suficientes para controlar la infección por *Map* (Billman-Jacobe *et al.*, 1992; Storset *et al.*, 2001; Ganusov *et al.*, 2015). Tampoco se ha observado una asociación entre los niveles en sangre de esta citocina, la intensidad lesional y el aislamiento micobacteriano en infecciones naturales bovinas (Vázquez *et al.*, 2013). Además, mediante pruebas *in vitro*, se ha demostrado que los macrófagos infectados con *Map* son incapaces de destruir las micobacterias después de la incubación con IFN- γ (Weiss *et al.*, 2001). El papel del IFN- γ , principal citocina efectora de la respuesta inmunitaria celular, se amplía detalladamente en el apartado 2.3.3.1.1.

Junto al IFN- γ , existen otras citocinas y mediadores de la inflamación importantes en la patogenia de la enfermedad, como la enzima iNOS que es un elemento fundamental en la polarización de la respuesta inmunitaria Th1 (Sonawane y Tripathi, 2016b). También el TNF- α , considerado como una de las citocinas básicas en las fases subclínicas de la paratuberculosis, implicado directamente en la formación de granulomas (Kaneko *et al.*, 1999; Palmer *et al.*, 2015). La citocina IL-1 es esencial para la expansión clonal de las células T, mientras que la IL-6 está implicada en la producción de proteínas de fase aguda (Alzuhherri *et al.*, 1996; Dinarello, 1996).

Como parte de esta respuesta inmunitaria celular, también participa un subtipo de células T CD4+ que en presencia de citocinas como la IL-6 o el

TFG- β , se diferencia a células Th17, con capacidad de producir y liberar IL-17. Una vez secretada, esta molécula de carácter proinflamatorio actuará sobre células del sistema inmunitario, activándolas para que produzcan citocinas pro-inflamatorias como la IL-1, IL-6, TNF- α y GM-CSF. Estas citocinas inducen y mantienen una respuesta protectora frente a las micobacterias (Curtis y Way, 2009; Park *et al.*, 2014).

Sin embargo, y a pesar del papel protector que tienen en un primer momento, las citocinas proinflamatorias pueden ejercer un efecto adverso para el propio hospedador, debido al efecto citotóxico de una respuesta inmunitaria prolongada o exagerada (Clarke, 1997; Stabel, 2006). Para evitarlo, la respuesta celular de tipo Th2 y en particular las citocinas asociadas a dicha respuesta, desempeñan un papel fundamental en la regulación de las respuestas excesivas de tipo Th1. Principalmente se han estudiado las citocinas IL-4 e IL-10 que ejercen un efecto inmunosupresor sobre el IFN- γ (Ito *et al.*, 1999; Saraiva y O'Garra, 2010; Magombedze *et al.*, 2015). Adicionalmente, dentro de la inmunidad celular también participa otra subpoblación de linfocitos T, las células T reguladoras (Treg). Estas células tienen una función inmunosupresora y expresan los marcadores de superficie CD4+ y CD25+, además del factor de transcripción "forkhead box P3" (FoxP3) (Hori *et al.*, 2003). Diferentes estudios, sugieren que en fases subclínicas de la infección, la población de Treg aumentaría en respuesta a *Map*, de tal forma que inhibirían la respuesta inmune celular (Stabel, 2006; Weiss *et al.*, 2006; de Almeida *et al.*, 2008; Sohal *et al.*, 2008; Roussey *et al.*, 2014).

En algunas infecciones crónicas, se ha señalado que podría existir un agotamiento de la respuesta inmunitaria de tipo Th1 (Wherry, 2011) que, en el caso de la paratuberculosis, se caracteriza fenotípicamente por la sobreexpresión del receptor PD-1 ("programmed death 1") y LAG-3 ("lymphocyte activation gene 3") en la superficie de las células Th1. Una vez

unidos a sus ligandos, PD-L1 y MHCII respectivamente, bloquearían las rutas de activación de la respuesta inmunitaria celular (Okagawa *et al.*, 2015). Estos resultados sugieren que la disminución de la respuesta inmunitaria celular, que se observa en los animales con lesiones multibacilares, podría deberse al comienzo del deterioro general de la respuesta inmunitaria, es decir, un agotamiento de las células T que afectaría en primer lugar a la respuesta celular (Begg *et al.*, 2011; Okagawa *et al.*, 2015).

2.3.2.2.2. Respuesta inmunitaria humoral

En la mayor parte de animales que están en las fases clínicas o avanzadas de la enfermedad paratuberculosa donde el animal muestra signos clínicos y excreta micobacterias en heces, se ha señalado que la respuesta humoral sería la predominante (Clarke, 1997; Pérez *et al.*, 1997; Storset *et al.*, 2001). Conforme evoluciona la enfermedad, de la fase subclínica a la clínica, se produciría un cambio en el perfil predominante de respuesta inmunitaria desde Th1 a Th2 (Stabel, 2000a; Koets *et al.*, 2015).

Esta respuesta inmunitaria humoral se caracteriza por la producción de anticuerpos mediada por linfocitos B, escasa producción de citocinas proinflamatorias como IFN- γ (Chiodini *et al.*, 1984; Pérez *et al.*, 1999, 2012) y el predominio de las de tipo Th2 (Stabel, 2000a, 2006), principalmente IL-4 e IL-10, ejercen un efecto supresor sobre la secreción IFN- γ y con ello, permiten la diseminación de las micobacterias y que la enfermedad progrese hacia fases avanzadas (Khalifeh y Stabel, 2004; Sohal *et al.*, 2008; Koets *et al.*, 2015). El TGF- β es otra citocina importante en la inmunomodulación de la respuesta inmunitaria por su efecto supresor de la IL-2, MHCII e IFN- γ y catalizadora de la activación de la IL-10 (Khalifeh y Stabel, 2004; Sonowane y Tripathi, 2016b).

Además, también se ha comprobado una mayor expresión de IL-10, TGF- β (Khalifel y Stabel, 2004) y de IL-2, IL-4 e IL-10 (Tanaka *et al.*, 2005; de Silva *et al.*, 2011) en lesiones multibacilares (alta carga micobacteriana) frente a las paucibacilares en tejidos de vacas infectadas por *Map*. Este hecho se ha comprobado en bovinos infectados experimentalmente con *Map*, en los que se han detectado altos niveles de TGF- β en animales con lesiones difusas y alta carga bacteriana coincidiendo con muy bajos niveles de IFN- γ (Muñoz *et al.*, 2009).

Una vez activados hacia un perfil Th2, estos linfocitos estimulan la diferenciación de los linfocitos B para que produzcan anticuerpos, IgM y fundamentalmente IgG1, específicos frente a los antígenos de *Map* (Sohal *et al.*, 2008). A su vez, las células B estarían implicadas en la activación de las células CD4+ hacia un perfil Th2 (Stabel y Khalifeh, 2008). Esto se ha confirmado en diversos estudios, tanto de infección natural como experimental, en los que se ha observado una elevada presencia de linfocitos B en sangre periférica (Waters *et al.*, 1999; Lee *et al.*, 2001) y de niveles de anticuerpos específicos frente a *Map* conforme la enfermedad avanza y progresa hacia la fase clínica (Pérez *et al.*, 1997; Burrells *et al.*, 1998; Storset *et al.*, 2001; Begg *et al.*, 2011).

Según Waters *et al.* (2003) el inicio de la producción de anticuerpos tras la infección con *Map* estaría directamente relacionado con la dosis y la vía de infección. Diversos ensayos experimentales en corderos han demostrado que los títulos de anticuerpos comienzan a elevarse a los 80 (Juste *et al.*, 1994) ó 110 días postinfección (dpi) (Delgado *et al.*, 2012), con picos de mayor producción a los 9 meses en esta misma especie (Begg *et al.*, 2005). En caprinos, hay estudios que han situado esta respuesta a los 180 dpi (Munjal *et al.*, 2005). La administración de dosis elevadas de bacilos por vía intratonsilar en terneros favorece la producción de anticuerpos a los 134 dpi,

60 días antes de encontrarse repuesta celular en estos animales (Waters *et al.*, 2003), de modo que la respuesta humoral puede observarse en fases tempranas e incluso adelantarse a la celular. Algo similar sucede tras la vacunación frente a *Map* donde se pueden identificar anticuerpos poco tiempo después de ser vacunados (Juste *et al.*, 1994; Muñoz, 2014), posiblemente debido a la elevada cantidad presente en el inóculo vacunal.

Hay que tener en cuenta que los resultados observados en relación a la respuesta inmunitaria humoral dependen mucho de los antígenos de *Map* utilizados para la detección de anticuerpos así como del isotipo de inmunoglobulina a detectar (Ridge *et al.*, 1991; Hilbink *et al.*, 1994; Koets *et al.*, 2001; Bannantine *et al.*, 2008). Cuando se comparan distintos anticuerpos (IgG1, IgG2, IgM e IgA) se han encontrado diferencias en la dinámica de su producción (Koets *et al.*, 2001). Así, el paso de una respuesta Th1 a Th2 se acompañaría de un incremento en los niveles de IgG1 en respuesta al antígeno PPD de *Map* (Abbas *et al.*, 1988; Koets *et al.*, 2001), mientras que las IgG2 podrían tener relación con la respuesta Th1 (Chiodini, 1996; Clark, 1997; Koets *et al.*, 2001). La detección de IgM e IgA no es constante por lo que no serían buenos indicadores de la transición de una respuesta Th1 a una Th2 (Koets *et al.*, 2001).

El hecho de que las respuestas celular y humoral se desarrollen de forma conjunta pone en duda la hipótesis sobre la transición de una respuesta de tipo Th1 a la Th2 (Begg *et al.*, 2011; Vázquez *et al.*, 2013). Incluso, se ha descrito una mayor proliferación de linfocitos B en respuesta a diferentes antígenos de *Map* en las fases subclínicas en comparación con la fase clínica de la infección (Waters *et al.*, 1999). Así, una de las hipótesis propuestas para explicar la progresión de la infección, implicaría, por un lado, la alteración del fenotipo de los linfocitos B y, por otro, la inhibición de su capacidad proliferativa en respuesta a los antígenos de *Map* en las fases

avanzadas de la paratuberculosis (Waters *et al.*, 1999; Stabel y Khalifeh, 2008).

Hasta hace pocos años, se había aceptado de forma general que la presencia de anticuerpos frente a *Map* en fases avanzadas de la paratuberculosis, no sería eficaz para controlar la multiplicación de la bacteria y evitar el progreso de la infección (Beggara-McGorum *et al.*, 1998; Stabel, 2000a; Sohal *et al.*, 2008). Sin embargo, estudios más recientes otorgan una mayor relevancia a la respuesta humoral en el control de las micobacteriosis (Balu *et al.*, 2011; Achkar y Casadevall, 2013) ya que se ha demostrado que algunos anticuerpos pueden potenciar la respuesta inmunitaria, tanto innata como celular, frente a las micobacterias (de Vallière *et al.*, 2005).

2.3.3. Establecimiento y desarrollo de las lesiones

La respuesta del hospedador a la infección por *Map* se caracteriza, desde el punto de vista de la lesión, por una inflamación granulomatosa, conformada por la acumulación local de células del sistema fagocítico-mononuclear (Koets *et al.*, 2015). Un vez que la micobacteria ha sido fagocitada por el macrófago, y sus antígenos presentados en superficie a los linfocitos, mediante la secreción de diferentes citocinas y mediadores de la inflamación por ambas poblaciones celulares, se desencadenará una respuesta inflamatoria caracterizada por el reclutamiento de macrófagos y linfocitos T hacia el lugar de infección, los cuales forman el granuloma (Ramakrishnan, 2012; Koets *et al.*, 2015).

Los granulomas pueden estar compuestos por diferentes poblaciones celulares, como macrófagos espumosos, células epitelioides con abundante citoplasma y células gigantes multinucleadas (células de Langhans), además de los linfocitos T y B (Ramakrishnan, 2012). Los granulomas se han considerado tradicionalmente como un mecanismo de defensa propio para

contener la micobacteria, prevenir su multiplicación y difusión hacia otras zonas del organismo y evitar que la respuesta inmunitaria sea desmesurada (Saunders y Cooper, 2000; Guirado y Schlesinger, 2013). Sin embargo, como se ha señalado anteriormente, la eliminación completa de la micobacteria es muy difícil de conseguir y pueden permanecer latentes en el tejido durante largos periodos de tiempo o incluso reactivarse y colonizar zonas no relacionadas con el granuloma inicial (Sandor *et al.*, 2003). En otras infecciones granulomatosas como la tuberculosis se ha sugerido, por el contrario, que los granulomas contribuirían a la proliferación micobacteriana temprana y podrían favorecer una expansión local o diseminación sistémica a través de los macrófagos y células dendríticas (Davis y Ramakrishnan, 2009).

La progresión de la infección determina el desarrollo de los granulomas. De forma general se han descrito dos tipos de lesiones en función del estadio de la infección paratuberculosa: de tipo “tuberculoide” y de tipo “lepromatoso”. Las lesiones iniciales que aparecen en fases tempranas de la infección, las de tipo focal y multifocal, son de tipo “tuberculoide” y se componen de escasas células epitelioides, macrófagos, escasos linfocitos y una respuesta inmunitaria de perfil celular, con baja presencia de bacilos. Conforme progresa la enfermedad, se establecen lesiones menos organizadas de tipo “lepromatoso”, que se corresponderían con lesiones difusas multibacilares, con gran cantidad de macrófagos y células epitelioides que contienen numerosos bacilos y provocan una fuerte respuesta inmunitaria humoral (García Marín *et al.*, 1995, 2000; Pérez *et al.*, 1996, 1997, 1999; Burrells *et al.*, 1998; Tanaka *et al.*, 2005).

En el intestino, una vez que la micobacteria es fagocitada por los macrófagos, se inicia la formación de los granulomas en los espacios interfoliculares de las placas de Peyer (Valheim *et al.*, 2002; Sweeney *et al.*, 2006) donde son capaces de contener la multiplicación de *Map*, por lo que se

observan en las fases latente y subclínica de la enfermedad (Whitlock y Buergelt, 1996, Sweeney *et al.*, 2006). Posteriormente, las lesiones comienzan a observarse e zonas de mucosa intestinal bien asociadas o no al tejido linfoide y finalmente, en las fases clínicas, aparecen de forma difusa en amplios tramos del intestino delgado (Juste *et al.*, 1994; Kurade *et al.*, 2004; Verna *et al.*, 2007; Delgado *et al.*, 2013; Köhler *et al.*, 2015). En función de las características y distribución de los granulomas, se distinguen formas lesionales que guardan una estrecha relación con la progresión de la enfermedad y que se explican más detalladamente en el apartado 2.5.2.

2.3.3.1. Influencia de la respuesta inmunitaria local en el desarrollo de las lesiones

Uno de los aspectos más importantes para entender la patogenia de la paratuberculosis es la relación que existe entre las lesiones presentes en los tejidos y la respuesta inmunitaria desarrollada por el hospedador. La mayor parte del conocimiento sobre la interacción entre *Map* y las células del sistema inmunitario (linfocitos T, B y macrófagos), se ha logrado mediante el estudio de la respuesta inmunitaria periférica (Weiss y Souza, 2008; Bannatine y Talaat, 2010; Thirunavukkarasu *et al.*, 2015). Sin embargo, no siempre estos resultados pueden extrapolarse a lo que ocurre a nivel local, en el lugar de infección donde se produce la interacción patógeno- hospedador de forma que existirían diferencias sustanciales entre la respuesta inmunitaria local, en la mucosa intestinal, en comparación con lo que ocurre en la sangre, a nivel periférico (Begara-McGorum *et al.*, 1998; Weiss *et al.*, 2006; Shu *et al.*, 2011).

La respuesta inmunitaria en la mucosa intestinal está controlada por una serie de células y mediadores, para asegurar que sea efectiva en la eliminación de patógenos pero, que a su vez, no sea exagerada y evitar así el daño tisular (Mills, 2004). Esta respuesta, puede verse alterada por la

interferencia de los diversos mecanismos de supervivencia de *Map* (Sigurdardóttir *et al.*, 2001; Tessema *et al.*, 2001; Woo y Czuprynski, 2008), expuestos en el apartado 2.3.1. Entre los mediadores encargados de dirigir la respuesta inmunitaria son fundamentales las citocinas, ya que el balance de las mismas puede influir en el devenir de la respuesta inmunitaria frente a *Map* (Begara-McGorum *et al.*, 1988; Hostetter *et al.*, 2002; Tanaka *et al.*, 2005; Bormann *et al.*, 2011). Los macrófagos, tras la infección, liberan IL-8, factor quimiotáctico de linfocitos T (Orme y Cooper, 1999; Orme y Basaraba, 2014) que una vez reclutados y activados, mediante la presentación de antígenos, secretan IFN- γ para estimular a otros macrófagos adicionales., por lo que juega un papel principal en la activación de los macrófagos y en la eliminación de las micobacterias (Flesch y Kaufmann, 1988; Gessani *et al.*, 1998; Sica y Mantovani, 2012; Martínez y Gordon, 2014). Junto a esta citocina, el TNF- α producido por los macrófagos infectados, juega un papel importante en la salida de nuevos monocitos sanguíneos hacia el foco de infección y diferenciación posterior de macrófagos a células epitelioides, con una marcada actividad bactericida (Fitzgerald *et al.*, 2014). Además, el TNF- α es necesario para el mantenimiento de la estructura del granuloma y reclutamiento de las células inflamatorias del mismo, y por tanto, esencial para el control de la infección (Roach *et al.*, 2002; Marino *et al.*, 2007). Los macrófagos infectados por la micobacteria también producen cantidades significativas de IL-6, la cual participa activamente en la diferenciación de macrófagos hacia células epitelioides y células gigantes (Fitzgerald *et al.*, 2014).

Por otro lado, existen citocinas encargadas de controlar la acción de los macrófagos ya que, como se ha indicado, estas células pueden causar daño tisular como consecuencia de una respuesta exacerbada. Dentro de ellas, se considera que la IL-10 ejerce un efecto supresor en la expresión de citocinas Th1, en la inflamación y en la activación inmunitaria (inhibe la

activación de linfocitos T) (Weiss *et al.*, 2005) y regula negativamente la expresión de MHC II, atenuando la presentación antigénica de los macrófagos (de Silva *et al.*, 2011). La IL-13, citocina de tipo Th2, también posee características antiinflamatorias que regularía la función de los macrófagos en infecciones por micobacterias (Shu *et al.*, 2011). En estas infecciones, la mayor parte de los estudios no observan un perfil de citocinas Th1 o Th2 estricto, por lo que se considera que puede haber una transición gradual en la respuesta inmunitaria conforme progresa la enfermedad hacia formas lesionales más graves (Coussens *et al.*, 2004; Begg *et al.*, 2011; Shu *et al.*, 2011). En animales con lesiones graves de paratuberculosis se ha observado un perfil mixto de citocinas Th1 y Th2, junto a una mayor expresión de IL-10 de efectos antiinflamatorios e inmunosupresores (Coussens *et al.*, 2004; Shu *et al.*, 2011). Este variado perfil de citocinas supondría, según estos autores, un posible mecanismo de evasión de la respuesta inmunitaria del hospedador por parte de *Map* y debido a ello, una menor eficiencia en la destrucción de la micobacteria.

En cuanto a la relación entre la expresión de citocinas y las lesiones de la paratuberculosis, en las lesiones difusas multibacilares de bovinos y ovinos se ha detectado mediante técnicas inmunohistoquímicas, una elevada expresión de la citocina antiinflamatoria TGF- β mientras que en los animales con lesiones focales y multifocales, que además expresaban niveles elevados de IFN- γ en sangre, fue inapreciable (Muñoz *et al.*, 2009). Mediante RT-PCR se comprobó que las lesiones multibacilares de ovinos infectados con *Map* mostraban una reducción en la expresión de IFN- γ e iNOS y una elevación de TGF- β respecto de los animales control (Sonawane y Tripathi, 2016b). En vaca un estudio similar reflejó que la transcripción génica de IL-1 α , IL-1 β , IL-6 e IFN- γ era mayor en los animales infectados que en los no infectados (Alzuhherri *et al.*, 1996; Lee *et al.*, 2001; Smeed *et al.*, 2007). En esta misma

especie se observó un incremento de la transcripción de citocinas proinflamatorias, TNF- α e IFN- γ , en lesiones iniciales (Palmer *et al.*, 2015).

2.3.3.1.1. El IFN- γ

El IFN- γ es una citocina fundamental en la defensa frente a una amplia variedad de patógenos intracelulares, incluyendo las micobacterias y participa activamente en la patogenia de la paratuberculosis (Dorman y Holland, 1998). En la respuesta inmunitaria de tipo Th1, que se observa en los estadios más tempranos de esta enfermedad, se produce una marcada secreción de IFN- γ por lo que se considera que esta citocina es esencial para el control de la infección (Pérez *et al.*, 1999; Stabel y Robbe-Austerman, 2011; Arsenault *et al.*, 2014). De hecho, se ha demostrado que tras una infección micobacteriana, el IFN- γ es necesario para el desarrollo y formación de los granulomas y que, en su ausencia, se produce un infiltrado celular mixto desorganizado (Ehlers y Ritcher, 2001).

El IFN- γ es sintetizado principalmente por los linfocitos Th1 CD4+ y por las células NK; su función principal es activar, por la vía clásica, a los macrófagos, lo que confiere protección frente a *Map* a través de la fagocitosis de la micobacteria (Cooper *et al.*, 2002; Arsenault *et al.*, 2014). La liberación del IFN- γ activa el sistema fagocítico del macrófago a través de la liberación de reactivos oxigenados y nitrogenados, producción de citocinas y maduración del fagosoma, acciones dirigidas a la eliminación de la bacteria (Cooper *et al.*, 2002; Sica y Mantovani, 2012).

Diversos estudios, realizados en la especie humana y en el ratón han demostrado que una deficiencia en el reconocimiento o expresión del IFN- γ , provoca una mayor susceptibilidad a la infección por patógenos intracelulares (Cooper *et al.*, 1993; Dupuis *et al.*, 2000). También son varios los estudios que resaltan la importancia del IFN- γ en la patogenia de la paratuberculosis. Así,

en vacas infectadas, se han identificado *in vitro*, niveles más elevados de IFN- γ a partir de células mononucleares aisladas de sangre periférica en comparación con los observados en animales control (Coussens *et al.*, 2004). En animales infectados experimentalmente con *Map* se aprecian, en fases tempranas tras la infección, niveles de IFN- γ significativamente superiores respecto de los controles no infectados (Reddacliff *et al.*, 2003; Waters *et al.*, 2003; Begg *et al.*, 2010; Delgado *et al.*, 2013; Dukkipati *et al.*, 2016). De estos estudios se puede concluir que esta citocina no solo se produce en una fase temprana frente a la infección por *Map*, sino que dicha producción continúa durante el transcurso de la misma (Vázquez *et al.*, 2013).

Respecto al papel del IFN- γ a nivel local, gran parte de los trabajos se han centrado en la cuantificación de la transcripción génica de esta citocina en el intestino y nódulos linfáticos mesentéricos en casos de infección por *Map* en vaca (Lee *et al.*, 2001, Coussens *et al.*, 2004; Shu *et al.*, 2011) y en oveja (Begara-McGorum *et al.*, 1998; Smeed *et al.*, 2007). En bovinos con enfermedad subclínica, se observa una mayor transcripción génica de esta citocina en los nódulos linfáticos ileal y cecal (Sweeney *et al.*, 1998). Asimismo, los niveles de IFN- γ se hallan incrementados tras la estimulación de linfocitos de los nódulos linfáticos mesentéricos un mes después de la infección con *Map* (Määttänen *et al.*, 2013).

Sin embargo, aún no se ha establecido una relación entre los niveles de transcripción de ARNm de IFN- γ y el tipo de lesión histológica. Algunos estudios no han encontrado diferencias en cuanto a la expresión génica de esta citocina a nivel local, entre lesiones multibacilares y paucibacilares, en vaca (Tanaka *et al.*, 2005) u oveja (Gillan *et al.*, 2010). En cambio en otros, se ha comprobado una mayor secreción de IFN- γ en ovejas con lesiones paucibacilares respecto de las multibacilares (Burrells *et al.*, 1999), si bien este estudio se realizó a partir de linfocitos del intestino o nódulos linfáticos

asociados después de la estimulación con johnina-PPD. En la misma línea, también se han observado mayores niveles de transcripción de IFN- γ asociados a lesiones paucibacilares (Smeed *et al.*, 2007) o a formas graves en general, sin considerar el tipo lesional (Shu *et al.*, 2011). En cuanto al empleo de técnicas inmunohistoquímicas para valorar la expresión local de IFN- γ en paratuberculosis, solamente hay un estudio previo que valora muestras de ovejas subclínicamente infectadas por *Map* y sin lesiones microscópicas (Reddacliff *et al.*, 2004) que no ofreció datos concluyentes, ya que los resultados obtenidos no se pudieron comparar con animales control.

2.4. Signos clínicos y curso de la enfermedad

Como se ya se ha señalado en el apartado 2.2. (Epidemiología, diagnóstico y control), los animales se infectan a edades tempranas pero los signos clínicos de la enfermedad no se observan hasta la edad adulta, a partir de los 2 años, una vez iniciado el periodo de lactación (Chiodini *et al.*, 1984; Radostis *et al.*, 2007; Dennis *et al.*, 2011). Algunos animales permanecen infectados de forma subclínica a lo largo de toda su vida (Whitlock y Buergelt, 1996; Pérez *et al.*, 2000; Sweeney, 2011; Koets *et al.*, 2015). Debido al curso lento y crónico que caracteriza a esta enfermedad, se diferencian varias fases desde un punto de vista clínico: periodo silente, fase subclínica y fase clínica (Buergelt *et al.*, 1978; Sweeney, 2011; Koets *et al.*, 2015).

La presencia de la enfermedad en el rebaño se asemeja a la disposición de un iceberg: existe un pequeño número de animales con signos clínicos (parte visible), y un porcentaje elevado de animales infectados, potencialmente excretores, pero no detectables en el examen clínico, es decir, en las fases silentes o subclínicas de la enfermedad (Sweeney, 2011; Pérez *et al.*, 2012). De hecho, se ha descrito que por cada vaca con signos clínicos de paratuberculosis, existen entre 10 y 25 infectadas que no los muestran (Whitlock y Buergelt, 1996; Sweeney, 1996). Se calcula que la

manifestación clínica de la enfermedad aparece entre el 5 y el 10%, pero puede llegar a ser del 50% del total de animales infectados (Pérez *et al.*, 2000, 2012; González *et al.*, 2005; Espejo *et al.*, 2012; Windsor, 2015).

Tras la infección, los animales pueden permanecer en la fase subclínica o silente de 2 a 10 años (Whitlock y Buergelt, 1996; Espejo *et al.*, 2012). Durante la misma se puede observar un aumento descenso de la producción láctea, alteraciones reproductivas y susceptibilidad a padecer mamitis (Richardson y More, 2009; García y Shalloo, 2015). Puede haber una excreción intermitente de micobacterias en las heces, aunque no se manifiestan signos característicos de la paratuberculosis, como diarrea y pérdida de peso (Rebhun, 1995; Pérez *et al.*, 2012; Bryant *et al.*, 2012; Stabel *et al.*, 2014). La fase clínica de la paratuberculosis se desencadena generalmente por un episodio de estrés, como por ejemplo tras el parto, en estados de desnutrición, manejo inadecuado, patologías concomitantes, parasitosis o condiciones ambientales lesivas (Chiodini *et al.*, 1984; Pérez *et al.*, 2000; Brown *et al.*, 2007; Radostits *et al.*, 2007).

El signo clínico más característico de la paratuberculosis es la progresiva pérdida de peso y condición corporal, a pesar de que los animales reciban una alimentación adecuada y sigan manteniendo el apetito (Pérez *et al.*, 2000, 2012; Kudahl y Nielsen, 2009; Bryant *et al.*, 2012; Stabel *et al.*, 2014). Esta pérdida de peso sería consecuencia de la malabsorción y pérdida de proteínas asociados a la inflamación del intestino (Madge, 1971; Scott *et al.*, 1995; Sweeney, 2011; Fecteau *et al.*, 2016). Otro signo clínico que se pueden encontrar es el edema hipoproteínémico en las partes declives, siendo muy típico el edema submandibular, que suele preceder incluso a otros síntomas (Chiodini *et al.*, 1984; Whitlock y Buergelt, 1996).

En el ganado bovino la pérdida de peso se acompaña frecuentemente de una profusa diarrea líquida, no sanguinolenta, en ocasiones maloliente,

que no responde a tratamiento con antibióticos (Fecteau y Whitlock, 2011). Se estima que en esta fase los animales infectados pueden llegar a excretar más de 10^4 UFC/g de heces de *Map* (Mitchell *et al.*, 2015). Estos episodios de diarrea pueden ser crónicos, pero también es frecuente que en algunos animales puedan recuperarse o, al menos, remitir transitoriamente a pesar de que el cuadro clínico retorne de forma más grave en la siguiente lactación (Pérez *et al.*, 2000, 2012; Espejo *et al.*, 2012). La mortalidad anual de un rebaño oscilaría entre el 3 y el 10% de los animales adultos (Chiodini *et al.*, 1984; Lombard, 2011).

A diferencia del ganado bovino, la diarrea no es un signo característico y constante de la paratuberculosis en las especies ovina y caprina, en las que frecuentemente, el único signo clínico observado es la pérdida progresiva de condición corporal, que suele manifestarse generalmente después del parto (García Marín y Pérez, 1994; Valentin- Weigand y Goethe, 1999; Pérez *et al.*, 2012). Además, también varía el curso clínico de la enfermedad, que puede prolongarse durante largos periodos en el ganado vacuno si bien éste suele ser mucho más corto en los pequeños rumiantes (Chiodini *et al.*, 1984).

2.5. Lesiones

2.5.1. Lesiones macroscópicas

La paratuberculosis, en fase clínica avanzada, se acompaña de lesiones macroscópicas comunes a los procesos caquetizantes como la marcada depleción de depósitos grasos, incluso atrofia serosa de la grasa, pérdida de masa muscular, presencia de edema subcutáneo, ascitis y acumulación de líquidos serosos en otras cavidades (Clarke y Little, 1996).

Sin embargo, las lesiones más específicas de la paratuberculosis se relacionan con el aparato digestivo, principalmente las que afectan al íleon, yeyuno, válvula ileocecal, incluso al ciego, primera parte del colon y a los

nódulos linfáticos mesentéricos regionales (Chiodini *et al.*, 1984; Carrigan y Seaman, 1990; Pérez *et al.*, 2012). El engrosamiento de la pared intestinal, principalmente del íleon, es el rasgo característico de la enfermedad, especialmente frecuente en los bovinos. En esta localización la mucosa aparece edematosa, tumefacta, con aspecto carnosos y forma gruesos pliegues, que pueden presentar áreas congestivas, petequias, pequeñas fisuras o ulceraciones (Pérez *et al.*, 2000; González *et al.*, 2005; Pérez *et al.*, 2012).

El intestino grueso, en concreto el ciego y primeros tramos de colon, también puede verse afectados macroscópicamente de forma similar. No obstante, en casos avanzados, las lesiones pueden extenderse de forma difusa desde el duodeno hasta el recto (Chiodini *et al.*, 1984; Radostits *et al.*, 2007). En ocasiones los vasos linfáticos que conectan la serosa con los nódulos linfáticos pueden presentar un grado variable de linfangiectasia, visible a modo de cordón retorcido con aspecto blanquecino (Carrigan y Seaman, 1990; Pérez *et al.*, 2000; González *et al.*, 2005; Sweeney, 2011; Pérez *et al.*, 2012). Los nódulos linfáticos mesentéricos (ileales, yeyunales e ileocecales) aparecen aumentados de tamaño, tumefactos y aspecto edematoso (Whitlock y Buergelt, 1996; González *et al.*, 2005).

En los pequeños rumiantes con paratuberculosis clínica, el engrosamiento de la pared intestinal suelen ser menos evidente y puede pasar desapercibido (García Marín y Pérez, 1994; Brown *et al.*, 2007; Pérez *et al.*, 1996, 2012). En cambio, una de las características que se pueden observar con relativa frecuencia es la presencia de linfangitis y linfangiectasia, especialmente en el ganado caprino (Corpa *et al.*, 2000). En ocasiones, es la única alteración macroscópica apreciable que permite el diagnóstico presuntivo de paratuberculosis (Brown *et al.*, 2007). Los vasos linfáticos de la pared intestinal presentan un recorrido tortuoso y se observan como un

cordón blanquecino incluso semitransparente, discurriendo por la serosa intestinal o incluso por el mesenterio en los casos de caquexia extrema (García Marín *et al.*, 1994; Pérez *et al.*, 2000; Kurade *et al.*, 2004; Brown *et al.*, 2007).

En ovino y caprino, los nódulos linfáticos (yeyunales, mesentérico caudal e ileocecal) presentan un aspecto similar al de los bovinos, pero aparecen caseificaciones y calcificaciones con mayor frecuencia, sobre todo en cabras (Carrigan y Seaman, 1990; Clarke y Little, 1996, Pérez *et al.*, 1996, 2012; Corpa *et al.*, 2000). En algunos casos en la especie ovina, el intestino puede aparecer coloreado de un tono amarillento, debido a la presencia masiva de bacilos pertenecientes a cepas pigmentadas de *Map* (Clarke y Little, 1996; Stevenson *et al.*, 2002).

En numerosas ocasiones, la intensidad de los signos clínicos no está directamente relacionada con la presencia de lesiones, sobre todo cuando se trata de pequeños rumiantes o de animales en la fase subclínica de la infección. Se pueden encontrar lesiones macroscópicas mínimas en animales que sin embargo presentaban signos clínicos graves o viceversa (Clarke, 1997; Pérez *et al.*, 2000; Radostits *et al.*, 2007; Brady *et al.*, 2008). Por este motivo, el estudio microscópico del intestino es fundamental ya que es el único que permite conocer en profundidad los tipos de lesión que se pueden presentar en las diferentes fases de la infección paratuberculosa.

2.5.2. Lesiones microscópicas

Histológicamente la paratuberculosis cursa con una enteritis y linfadenitis de tipo granulomatosa, que se caracteriza por la presencia de un infiltrado focal o difuso de macrófagos, células epitelioides, células gigantes y linfocitos, que se agrupan y organizan en granulomas (Pérez *et al.*, 1996, 2000; Brown *et al.*, 2007; Delgado *et al.*, 2013; Vázquez, 2014).

En las fases subclínicas de la enfermedad, por lo general, las lesiones son de tipo focal o multifocal, formadas por pequeños granulomas bien definidos localizados en el espacio interfolicular del tejido linfoide adyacente a las placas de Peyer o en la lámina propia intestinal, sin alterar gravemente su morfología (Pérez *et al.*, 1996; Sigurdardóttir *et al.*, 1999; Kurade *et al.*, 2004; Verna *et al.*, 2007; Delgado *et al.*, 2013; Vázquez *et al.*, 2013). Las formas focales se observan inicialmente tras la infección por *Map* en las placas de Peyer, pero existen diferencias en cuanto al tramo intestinal afectado (Valheim *et al.*, 2002). En el ganado bovino el íleon es la parte donde se observa con más frecuencia este tipo de lesión, que se extiende a los nódulos linfáticos mesentéricos asociados (Clarke, 1997; González *et al.*, 2005). En pequeños rumiantes, se ha comprobado que las placas de Peyer ileocecales y yeyunales son las localizaciones más habituales de las lesiones focales en la fase subclínica de la enfermedad (Corpa *et al.*, 2000; Storset *et al.*, 2001; Valheim *et al.*, 2002; Delgado *et al.*, 2013; Koets *et al.*, 2015).

A medida que progresa la enfermedad y aparecen los signos clínicos, la inflamación se va extendiendo hacia otras zonas de la mucosa, dando lugar a lesiones difusas, más graves, en las que se observa ya el engrosamiento macroscópico de la mucosa intestinal debido a la existencia de un infiltrado de células epiteloides, células gigantes, linfocitos en cantidad variable, células plasmáticas y algún eosinófilo, que se extiende desde la mucosa hasta la submucosa y provoca engrosamiento de las vellosidades intestinales así como distorsión y obliteración de las criptas de Lieberkühn, debido a la acumulación de restos celulares (Buergelt *et al.*, 1978; Pérez *et al.*, 1996; Corpa *et al.*, 2000; González *et al.*, 2005; Brown *et al.*, 2007). La presencia de células gigantes de tipo Langhans, caracterizadas por presentar numerosos núcleos periféricos, es un hallazgo frecuente en la especie bovina (González *et al.*, 2005). En la mayoría de animales que muestran este tipo de lesiones difusas son muy abundantes las micobacterias, identificadas mediante la

tinción de ZN o técnicas inmunohistoquímicas (Chiodini *et al.*, 1984; Pérez *et al.*, 2000; González *et al.*, 2005; Brown *et al.*, 2007; Lee *et al.*, 2009b). Sin embargo, en animales con signos clínicos y engrosamiento de la pared intestinal, existen otro tipo de lesiones difusas, denominadas lesiones paucibacilares o linfocíticas, en las que el infiltrado de la lámina propia está compuesto fundamentalmente por linfocitos y células plasmáticas entre los que aparecen agregados de macrófagos, células gigantes y micobacterias en muy escaso número, o que incluso son indetectables (Chiodini *et al.*, 1984; Pérez *et al.*, 1996; González *et al.*, 2005).

Otras lesiones microscópicas que se pueden observar en casos clínicos de paratuberculosis son las linfangitis, caracterizadas por un infiltrado inflamatorio linfoplasmocitario, acompañado en ocasiones de alguna célula epitelioides, en la pared de los vasos linfáticos del intestino, que puede invadir y obstruir la luz de los mismos y provocar su dilatación o linfangiectasia (Carrigan y Seaman, 1990; Pérez *et al.*, 2000; Delgado *et al.*, 2013). En los nódulos linfáticos mesentéricos se observa una linfadenitis granulomatosa en la que destaca la presencia de grupos de macrófagos e incluso células gigantes, tanto en las zonas cortical (senos subcapsulares y peritrabeculares) y paracortical como en la medular, alterando la arquitectura normal de estos órganos (Chiodini *et al.*, 1984; Pérez *et al.*, 1996; González *et al.*, 2005; Brown *et al.*, 2007).

2.5.2.1. Clasificación de las lesiones

A pesar de ser la paratuberculosis una enfermedad muy estudiada en el ámbito de la sanidad animal, no hay un criterio homogéneo establecido para su clasificación lesional. Se han llevado a cabo distintos intentos para clasificar las lesiones microscópicas, teniendo en cuenta su extensión y gravedad, en animales que se encuentran en las fases finales de la infección (Buergelt *et al.*, 1978; Carrigan y Seaman, 1990). La clasificación más

completa es la propuesta por Pérez *et al.* (1996) en la especie ovina, que permite asociar las lesiones a las distintas fases de la enfermedad, y tiene también en cuenta las formas observadas en la fase subclínica. Esta clasificación ha servido de base para otras propuestas en las especies bovina (González *et al.*, 2005) y caprina (Corpa *et al.*, 2000).

- Clasificación de las lesiones en la especie ovina:

Son numerosos los trabajos realizados sobre paratuberculosis en la especie ovina (Stamp y Watt, 1954; Carrigan y Seaman, 1990; Pérez, 1992, 1996; Verna *et al.*, 2007; Delgado, 2010; Dukkipati *et al.*, 2016), los cuales han permitido no solo caracterizar de forma exhaustiva las lesiones asociadas a esta enfermedad, sino que han servido como base para el estudiar el resto de especies afectadas. La clasificación lesional de la paratuberculosis ovina propuesta por Pérez *et al.* (1996) tiene en cuenta una serie de criterios, como son: a) presencia de lesiones granulomatosas características de paratuberculosis; b) localización intestinal de los granulomas y su relación con las placas de Peyer; c) intensidad y extensión de las lesiones; d) composición celular predominante en el infiltrado inflamatorio y e) cantidad de micobacterias presente en el tejido. Según estos criterios, se distinguen 3 tipos lesionales:

Lesiones de tipo 1: Son lesiones focales, presentes en las fases subclínicas de la enfermedad que no se aprecian macroscópicamente y que no alteran la estructura normal de la mucosa intestinal. Histológicamente, se trata de granulomas, formados por macrófagos y linfocitos, de localización exclusiva en el tejido linfoide interfolicular de las placas de Peyer intestinales y ocasionalmente, en los nódulos linfáticos relacionados, sobre todo en el mesentérico caudal. En este tipo de lesión la presencia de micobacterias es infrecuente.

Lesiones de tipo 2: Son lesiones de mayor gravedad que las de tipo 1, aunque no producen alteraciones macroscópicas. Los granulomas se sitúan en la parte basal de la zona interfolicular de las placas de Peyer, en la lámina propia adyacente o en las vellosidades, pero siempre en zonas relacionadas con el tejido linfoide. Estos granulomas, bien delimitados y de forma redondeada, nunca se encuentran en número suficiente para desestructurar la mucosa y provocar una enteritis difusa. En los nódulos linfáticos regionales se aprecian granulomas de características similares, aunque en menor tamaño y número.

Lesiones de tipo 3: Se subdividen en 3 subtipos que tienen como característica común la presentación de lesiones de forma difusa y la presencia de *Map* asociada a estas lesiones. Estos tres subtipos son:

- *Tipo 3a:* En este tipo de lesión los granulomas, bien delimitados, se localizan en la mucosa intestinal, relacionada o no con la placa de Peyer, tanto en la parte basal como en las vellosidades y entre las criptas de Lieberkühn, del íleon y a veces del yeyuno. Al igual que la lesión de tipo 2, estos granulomas no alteran excesivamente la estructura normal de las vellosidades. Sin embargo, algunos animales con este tipo de lesión presentan lesiones macroscópicas, consistentes en una linfangitis y linfangiectasia apreciable en la serosa de algunos tramos de íleon. En la submucosa y serosa pueden aparecer, de forma ocasional, infiltrados focales de linfocitos y macrófagos en relación con vasos linfáticos y sanguíneos. Igualmente, en el nódulo linfático yeyunal caudal, y con menor frecuencia en los ileocecales, aparecen lesiones granulomatosas similares a las descritas. En este tipo de lesión pueden detectarse BAAR en las lesiones de la mucosa, y en menor número, en las relacionadas con tejido linfoide.

- *Tipo 3b*: Los ovinos con este tipo lesional muestran engrosamiento macroscópico de la pared intestinal, con presencia de abundantes pliegues en tramos del íleon y de yeyuno, así como linfangiectasias en la serosa. Se trata de animales emaciados que en algunos casos, muestran edema en la región submandibular y en otros, aunque con menos frecuencia, diarrea. Los nódulos linfáticos mesentéricos e ileocecales aparecen aumentados de tamaño y edematosos. Microscópicamente se aprecia una enteritis granulomatosa difusa en yeyuno, íleon y válvula ileocecal, formada fundamentalmente por grupos de células epitelioides que dan la apariencia de mosaico a la mucosa intestinal. En el tejido linfoide local se encuentran lesiones granulomatosas, tanto en áreas interfoliculares como en los folículos y cúpulas de las placas de Peyer con alteración de su conformación normal. En las zonas de lámina propia intestinal no relacionada con el tejido linfoide el infiltrado difuso, compuesto principalmente de macrófagos, algunos linfocitos y células gigantes de pequeño tamaño, altera la morfología de las vellosidades. Además, se observa un número elevado de BAAR. El infiltrado de tipo linfoplasmocitario, similar al observado en las lesiones de tipo 3a, puede extenderse hasta la capa muscular. Los vasos linfáticos presentan lesiones inflamatorias similares a las descritas para las lesiones de tipo 3a. En los nódulos linfáticos mesentéricos e ileocecales aparece una linfadenitis granulomatosa, de multifocal a difusa, con pérdida de su estructura normal.

- *Tipo 3c*: El aspecto macroscópico de estas lesiones coincide con lo señalado en las lesiones de tipo 3b. Histológicamente se observa una enteritis granulomatosa difusa, pero en este caso las células predominantes en la lesión de la mucosa intestinal son los linfocitos, aunque se pueden apreciar algunos macrófagos formando pequeños

granulomas bien delimitados y, en ocasiones, células gigantes multinucleadas de tipo Langhans. En las placas de Peyer las lesiones son similares a las descritas en el tipo 3b, pero con un mayor número de macrófagos picnóticos y células gigantes en el granuloma. La submucosa presenta frecuentemente edema y un número variable de linfocitos y células plasmáticas dispuestas en grupos. En la serosa, la lesión es similar a la descrita para la lesión del tipo 3b. En los nódulos linfáticos regionales se aprecian granulomas de distribución multifocal, principalmente en la región paracortical y en las áreas interfoliculares, con numerosas células gigantes provistas de un elevado número de núcleos. En los granulomas se observan pequeños focos necróticos, en ocasiones calcificados. En la serosa de los nódulos linfáticos se aprecian macrófagos picnóticos e infiltrados perivasculares. La cantidad de BAAR en estos casos es escasa o nula.

- Clasificación de las lesiones en la especie bovina:

Aunque se han seguido llevando a cabo estudios recientes en el ganado bovino que han relacionado las formas lesionales con los tipos de respuesta inmunitaria y la presencia de micobacterias, clasificándolas en patentes o latentes (Vázquez, 2014) o con los polimorfismos genéticos (Juste *et al.*, 2016), la primera clasificación de lesiones en esta especie fue realizada por Buergelt *et al.* (1978), si bien solo consideraba animales en fases relativamente avanzadas de la enfermedad. González *et al.* (2005) llevan a cabo una clasificación que toma como referencia los criterios empleados por Pérez *et al.* (1996) para la especie ovina. De este modo se establecen 3 tipos principales de lesiones: *focales*, *multifocales* y *difusas*, estas últimas subdivididas en las de tipo *multibacilar*, *linfocítico* e *intermedio*.

Lesiones focales: Son lesiones pequeñas formadas por granulomas bien delimitados, constituidos por un número variable de macrófagos de

citoplasma abundante, pálido y espumoso, así como por alguna célula gigante, formando parte del granuloma o como células aisladas. Estas lesiones se ubican exclusivamente en el tejido linfoide adyacente a las placas de Peyer intestinales y en los nódulos linfáticos ileales y yeyunal caudal. La presencia de BAAR es nula o escasa, aunque se pueden demostrar mediante técnicas inmunohistoquímicas.

Lesiones multifocales: Los granulomas bien delimitados, formados por un pequeño número de macrófagos y rodeados por escasos linfocitos y células plasmáticas, aparecen en el tejido linfoide intestinal y también en la lámina propia de la mucosa intestinal. En ocasiones, se observan células gigantes, generalmente en mayor número que en las lesiones focales, como elementos aislados en la lámina propia o formando parte de los granulomas. Estas alteraciones se localizan en el ápice de la vellosidad y aunque provocan un cierto engrosamiento de la mucosa intestinal, no modifican significativamente su arquitectura y no son visibles macroscópicamente. Las lesiones multifocales, al igual que las formas focales, se observan en animales con infección subclínica.

Lesiones difusas: Se caracterizan por una enteritis granulomatosa grave, cuyo infiltrado inflamatorio, que se extiende por las diferentes capas del intestino, provoca un marcado engrosamiento de la pared intestinal visible macroscópicamente. Los animales que presentan estas lesiones muestran signos clínicos con diferente grado de intensidad. En función de la población celular predominante y de la presencia de BAAR, estas lesiones se dividen en tres subtipos diferentes:

- *Difusa multibacilar:* Las células predominantes son los macrófagos y células epitelioides, junto con escasos linfocitos y células gigantes, que infiltran la pared intestinal de forma difusa. En la lámina propia el infiltrado adopta el aspecto de un mosaico y causa un engrosamiento

grave de la pared intestinal. Las vellosidades aparecen frecuentemente fusionadas debido al infiltrado, si bien en general, la parte más basal de la lámina propia suele aparecer menos afectada. Las glándulas intestinales se encuentran dilatadas, con presencia de material necrótico en su interior. En el citoplasma de los macrófagos y células epitelioides se observan numerosas micobacterias, fácilmente detectables mediante las tinciones de ZN o inmunohistoquímicas. La submucosa también se encuentra afectada en la mayoría de los animales debido a la presencia de un infiltrado inflamatorio de composición similar al de la lámina propia, siendo frecuente el edema en esta capa, y en ocasiones, una vasculitis granulomatosa, con formación de trombos. En este tipo de lesión difusa, el tejido linfoide intestinal se encuentra afectado. Es frecuente observar granulomas en las zonas interfoliculares así como un intenso infiltrado inflamatorio difuso que invade los folículos linfoides y que se extiende a la capa muscular y también a la serosa. En esta última capa los infiltrados multifocales granulomatosos se encuentran generalmente asociados a la pared de los vasos linfáticos, que pueden contener abundantes macrófagos en su luz (linfangitis granulomatosa). Las lesiones difusas multibacilares se extienden desde el yeyuno proximal hasta la válvula ileocecal, con afectación ocasional del ciego. En ellas no se observan necrosis. Los nódulos linfáticos yeyunales e ileales presentan una linfadenitis granulomatosa difusa donde destacan, en número moderado a elevado, los macrófagos y células gigantes, tanto en la zona cortical y como paracortical. Tanto los vasos linfáticos aferentes como la arquitectura normal de estos nódulos linfáticos suelen estar gravemente afectados en este tipo de lesión. Los macrófagos y células gigantes del intestino, vasos linfáticos y nódulos linfáticos contienen

un gran número de BAAR, positivos también a la técnica inmunohistoquímica frente a *Map*, pero con intensidad variable.

- *Difusa linfocítica*: En este tipo de lesión, la población celular predominante son los linfocitos que infiltran la lámina propia intestinal, aunque también pueden aparecer algunos macrófagos y células gigantes que en ocasiones, llegan a formar granulomas aislados bien definidos. Al igual que en las formas difusas multibacilares la mucosa intestinal muestra acortamiento y engrosamiento de las vellosidades, debido a la presencia masiva de células inflamatorias. La submucosa, por el contrario, se encuentra menos alterada que en el caso anterior, aunque puede contener algún granuloma esporádico, siempre rodeado de linfocitos. En la serosa se puede observar un moderado infiltrado granulomatoso y en los nódulos linfáticos asociados es característica la linfadenitis granulomatosa difusa, con presencia esporádica de células gigantes en su entorno. La particularidad de esta lesión, aparte de su carácter linfocítico, radica en la escasa o nula presencia de micobacterias.
- *Difusa intermedia*: El infiltrado inflamatorio que causa en engrosamiento de las vellosidades y la separación de las glándulas intestinales, está formado por una población mixta de linfocitos y macrófagos y algunas células gigantes, sin que exista un predominio claro de uno u otro tipo celular, que varía según el animal, la zona afectada y el curso de la infección. La submucosa puede aparecer edematosa y con un infiltrado mononuclear en relación con granulomas y vasos linfáticos. El tejido linfoide intestinal del yeyuno e íleon (zonas más afectadas) también puede presentar granulomas similares a los descritos anteriormente. La presencia de micobacterias

suele estar relacionada con la cantidad de macrófagos presentes en la inflamación granulomatosa.

2.5.3. Espectro inmunopatológico de la paratuberculosis

Los factores que determinan que los animales presenten un tipo de lesión u otro no han sido aún esclarecidos. Se ha señalado que la respuesta inmunitaria del hospedador juega un importante papel en la evolución de la enfermedad y presumiblemente en la aparición de las lesiones (Pérez *et al.*, 1997, 1999; Kurade *et al.*, 2004; Vázquez *et al.*, 2013).

Tomando como referencia lo descrito en la lepra humana (Orme, 1993) se ha propuesto la existencia de un espectro inmunopatológico en la paratuberculosis y en otras micobacteriosis como la tuberculosis, que relaciona los distintos tipos de lesión con la respuesta inmunitaria adaptativa del hospedador y el desarrollo de la enfermedad clínica (Chiodini *et al.*, 1984; Chiodini, 1996; Clarke, 1997; Pérez *et al.*, 1997, 1999, 2012; Delgado *et al.*, 2013; Koets *et al.*, 2015).

En el extremo “tuberculoide” del espectro, los animales mostrarían lesiones de tipo focal, formadas por pequeños grupos de células epitelioides, bien delimitados, con ausencia de BAAR y asociados a una intensa respuesta inmunitaria de base celular Th1. La prueba del IFN- γ actuaría como indicador de esta lesión, que se asocia a un control de la multiplicación del patógeno y la ausencia de signos clínicos (Brown *et al.*, 2007; Pérez *et al.*, 1999, 2012; Vázquez *et al.*, 2013; Koets *et al.*, 2015). De esta fase o grupo serían características las lesiones de tipo 1 y 2 en la especie ovina y las focales y multifocales en los bovinos (Pérez *et al.*, 1999; González *et al.*, 2005; Vázquez *et al.*, 2013).

Próximo a este perfil inmunopatogénico se encuentran las lesiones difusas linfocíticas o tipo 3c, que se considerarían formas intermedias-

tuberculoides, donde ya existirían signos clínicos y una respuesta inflamatoria difusa, no controlada.

En el otro extremo estarían las formas intermedias “lepromatosas”, en las que los granulomas, menos organizados y asociados a fases terminales de la infección, estarían compuestos por numerosos macrófagos y células epitelioides repletos de abundantes BAAR, y normalmente asociados a una fuerte respuesta inmune humoral frente a una respuesta celular débil Th2 (Pérez *et al.*, 1996, 1997, 1999; Tanaka *et al.*, 2005). En este perfil se encuadran lesiones de tipo difuso multibacilar o tipo 3b en la especie bovina u ovina respectivamente. Las lesiones difusas intermedias y de tipo 3a, se situarían entre ambas formas, inclinándose hacia una u otra según el componente celular y la respuesta inmunitaria predominantes.

2.5.4. Los macrófagos en la respuesta inflamatoria

Las lesiones granulomatosas en el intestino y nódulos linfáticos asociados, compuestas por agrupaciones de macrófagos y linfocitos en diferentes estados de desarrollo y activación, son el signo distintivo de la paratuberculosis (Clarke y Little, 1996; Sweeney, 2011). Aunque el predominio de uno u otro componente celular está correlacionado con el estado de la infección y la respuesta inmunitaria del hospedador (Stabel, 2000a; Coussens, 2001; Sohal *et al.*, 2008; Sweeney, 2011), se considera que los macrófagos son la principal población celular implicada en la patogenia de esta enfermedad, jugando un papel fundamental en la interacción con el patógeno (Momotani *et al.*, 1988; Kabara *et al.*, 2012; Koets *et al.*, 2015). Estas células son las que están principalmente implicadas en el control del crecimiento e incluso en la destrucción de *Map*, pero también esta micobacteria, a través de diferentes mecanismos, puede reducir la capacidad bactericida de los macrófagos y así evadir la respuesta inmunitaria del

hospedador, lo que facilita su multiplicación y diseminación (Sigurdardóttir *et al.*, 2004; Valheim *et al.*, 2004; Weiss y Souza, 2008).

Los macrófagos fueron descritos por primera vez por Ilya Metchnikoff en 1908 al descubrir que ciertas células digerían partículas que introducían en el tubo digestivo de peces (Nathan, 2008). Los macrófagos son la célula funcionalmente más diversa del sistema hematopoyético, están presentes en todos los tejidos, son esenciales en la respuesta inmunitaria innata y juegan un papel fundamental en la modulación de la respuesta adaptativa mediante el procesado y presentación de antígenos (Davies *et al.*, 2013; Labonte *et al.*, 2014). Asimismo, intervienen en la generación y resolución de la inflamación, reparación de la matriz tisular y en la organización de funciones metabólicas (Gordon y Martínez, 2010; Sica y Mantovani, 2012; Davies *et al.*, 2013). Además de las funciones de defensa, los macrófagos son necesarios para mantener la homeostasis, al fagocitar células apoptóticas y restos celulares (Mosser y Edwards, 2008).

Los macrófagos derivan de los monocitos que se forman en la médula ósea a partir de células pluripotenciales que se comprometen en la diferenciación de granulocitos y monocitos (UFC-granulocito-monocito), gracias al factor de crecimiento GM-CSF y otras citocinas como la IL-3 (Sica y Mantovani, 2012; Jaguin *et al.*, 2013). Los monocitos alcanzan la circulación periférica sanguínea y al cabo de unos días migran a los tejidos, gracias a moléculas de adhesión al endotelio, quimiocinas, integrinas y citocinas que estimulan su reclutamiento, como el TNF- α y ahí contribuyen al mantenimiento de la homeostasis e intervienen en procesos inflamatorios (Stefater *et al.*, 2011; Gerhardt y Ley, 2015). En ese momento, tras la exposición y estimulación con factores de crecimiento locales, citocinas proinflamatorias y componentes microbianos, se diferencian en macrófagos y células dendríticas (Tacke y Randolph, 2006).

Los macrófagos, que están habitualmente en estado de reposo, pueden ser activados por gran variedad de estímulos durante la respuesta inmunitaria, entre los que destacan, por su eficacia, el reconocimiento de PAMPs o la propia fagocitosis de antígenos, pero hay otros como la secreción IFN- γ por linfocitos Th o el contacto con los propios agentes infecciosos, a través de la interacción de diferentes receptores celulares (Steinman e Idoyaga, 2010).

Es la célula principal que interviene en la inflamación crónica, donde contribuye a la reacción inflamatoria segregando citocinas y factores de crecimiento y activando otras células como linfocitos T; en particular, en la inflamación crónica de tipo granulomatoso, se transforman en células epitelioides y en células gigantes al fusionarse varios macrófagos (Clarke y Little, 1996; Brady *et al.*, 2008; Davies *et al.*, 2013). Las micobacterias como *Mtb* y *Map* capaces de resistir la fagocitosis por los macrófagos originan granulomas de tipo inmunitario como respuesta del hospedador al estímulo persistente. En esa circunstancia, los macrófagos activan las células T para producir citocinas como la IL-2, que a su vez activa otras células T, prolongando a su vez esta respuesta, e IFN- γ que a su vez activa nuevos macrófagos (Sica y Mantovani, 2012).

2.5.4.1. Polarización M1 y M2

Una característica común de los macrófagos es su plasticidad y diversidad morfológica y funcional, ya que según el mecanismo de activación o estado de polarización, estas células son capaces de adquirir distintos fenotipos con consecuencias funcionales distintas (Mills *et al.*, 2000; Sica y Mantovani, 2012; Davies *et al.*, 2013; Martínez y Gordon, 2014).

El término de activación macrofágica (activación clásica) fue utilizado por primera vez para describir la acción bactericida de los macrófagos frente

a *Listeria* spp. y al bacilo Calmette-Guerin de la tuberculosis (Mackaness, 1962). Para diferenciar los diferentes tipos de respuesta que desarrollan los macrófagos se han propuesto los conceptos de activación clásica y alternativa, denominadas respectivamente M1 y M2, de forma similar a la nomenclatura utilizada para los linfocitos T auxiliares (Th1 y Th2) (Martínez y Gordon, 2014). Este modelo de dos clases de macrófagos activados, con un fenotipo y funciones específicas, permite diferenciar mejor a las células de la línea monocito-macrófago, que son las más pleiotrópicas del sistema inmunitario (Geissmann *et al.*, 2010).

En los tejidos, la aparición de los distintos fenotipos sería consecuencia de la respuesta de los macrófagos a diferentes estímulos presentes en el medio (productos microbianos, células dañadas, linfocitos activados, citocinas, etc.) (Sica y Mantovani, 2012; Davies y Taylor, 2015). Cuando en estos estímulos predomina la acción de los receptores TLR, la citocina IFN- γ , o lipopolisacáridos bacterianos, los macrófagos pueden experimentar una activación clásica, en cuyo caso son denominados macrófagos M1. Si los estímulos externos están dominados por las interleucinas IL-10 o IL-13 se considera que los macrófagos se activan de forma alternativa y muestran un fenotipo M2 (Sica y Mantovani, 2012; Martínez y Gordon, 2014). También se ha descrito, en estudios *in vitro* en la especie humana, que la incubación de monocitos con GM-CSF los polarizaría hacia macrófagos tipo M1 mientras que el tratamiento con M-CSF (macrophage- colony stimulating factor) favorecería la expresión de citocinas de carácter antiinflamatorio por los macrófagos M2 (Sica y Mantovani, 2012; Jaguin *et al.*, 2013).

Los macrófagos con fenotipo M1 se caracterizan por la expresión de altos niveles de citocinas proinflamatorias como iNOS, TNF- α , IL-6 e IL-12 y reactivos tóxicos nitrogenados e intermediarios del oxígeno, de forma que

muestran una intensa actividad antimicrobiana y antitumoral y promueven una respuesta inmunitaria Th1 (Mantovani *et al.*, 2004; Barros *et al.*, 2013; Martínez y Gordon, 2014).

Por su parte, los macrófagos M2 actúan en la contención de la invasión parasitaria, en la reparación y remodelación tisular, facilitan la progresión tumoral y son moduladores de autoinmunidad (Sica y Mantovani, 2012). Este fenotipo M2 lleva a cabo una fagocitosis eficaz, por ejemplo de células apoptóticas, muestra una elevada expresión de receptores “scavenger” CD163, que participan en la eliminación de sustancias extrañas o de desecho, produce citocinas antiinflamatorias como TGF- β o receptores de manosa y galactosa, que intervienen en la fagocitosis de micobacterias (Mantovani *et al.*, 2004; Sica y Mantovani, 2012; Barros *et al.*, 2013; Martínez y Gordon, 2014).

De esta forma, los macrófagos clásicamente activados son unos efectores celulares importantes de la respuesta inmunitaria celular de tipo Th1, mientras que los macrófagos alternativamente activados M2 parecen estar involucrados en la inmunosupresión y en la respuesta inmunitaria de tipo Th2 (Gordon y Taylor, 2005; Biswas y Mantovani, 2010; Martínez y Gordon, 2014). Sin embargo, hay que precisar que, aunque esta diferenciación sea útil, subestima la complejidad *in vivo* donde estas células deben adaptarse a diferentes necesidades y situaciones, para responder a estímulos y factores ambientales muy diversos (Mosser y Edwards, 2008).

Fenotipo M1

Los LPS y la principal citocina efectora de tipo Th1, el IFN- γ , polarizan al macrófago hacia el fenotipo M1, de acción bactericida y proinflamatoria (Sica y Mantovani, 2012; Davies *et al.*, 2013; Liu *et al.*, 2014; Martínez y Gordon, 2014). Los macrófagos M1 expresan factores proinflamatorios como

TNF- α , IL-12 e IL-23, además de iNOS (inducible nitric oxide synthase) precursor de NO (nitric oxide), principal sustancia bactericida (MacMicking *et al.*, 1997). Estas citocinas proinflamatorias, producidas en respuesta a infecciones bacterianas, por ejemplo en el intestino, favorecen la diferenciación de linfocitos Th1 y Th17 (Gordon y Martínez, 2010).

En la Tabla 1 aparecen reflejados los marcadores expresados por los macrófagos activados M1, así como las citocinas proinflamatorias que producen. También se incluyen otras proteínas producidas por estos macrófagos denominadas quimiocinas que dirigen la migración y activación leucocitaria.

Fenotipo M2

En ocasiones la eliminación de agentes infecciosos puede causar daño tisular colateral, debido a la actividad tóxica y a los reactivos oxigenados secretados por las células inflamatorias en el foco de infección de manera que la respuesta inflamatoria, que debería ser beneficiosa, se vuelve descontrolada y dañina para el propio hospedador (Benoit *et al.*, 2008; Sica y Mantovani, 2012; Liu *et al.*, 2014). En este momento, destaca la función de los macrófagos M2, por su acción antiinflamatoria e inhibidora de la respuesta Th1 (Mantovani *et al.*, 2004).

Los macrófagos de fenotipo M2 son activados por citocinas de tipo Th2, como la IL-4 (Martínez y Gordon, 2014). Estos macrófagos alternativamente activados secretan niveles elevados de IL-10 y del receptor antagonista de la IL-1 (IL-1RA) y baja expresión de IL-12 (Sica y Mantovani, 2012; Martínez y Gordon, 2014). Las células M2 intervienen en la eliminación de parásitos extracelulares, disminuyen la inflamación, promueven la remodelación tisular y regulan la respuesta inmunitaria, reduciendo su intensidad para evitar los daños perjudiciales de una respuesta

proinflamatoria descontrolada (Benoit *et al.*, 2008; Martínez y Gordon, 2014). En su superficie, los macrófagos M2 expresan numerosos receptores “scavenger” (depuradores), receptores de manosa y galactosa (Sica y Mantovani, 2012). Concretamente, la expresión del receptor de la manosa se incrementa por acción de las citocinas de tipo Th2, IL-4 e IL-13, y su activación induce una mayor expresión de la molécula MHC de tipo II (Stein *et al.*, 1992; Doyle *et al.*, 1994).

Los macrófagos M2 a su vez se dividen en cuatro subtipos: 2a, 2b, 2c y 2d según el perfil de estímulos que provocan su activación (Mantovani *et al.*, 2004; Martínez y Gordon, 2014; Davies y Taylor, 2015). El subtipo M2a es estimulado por la IL-4 o IL-13, participa en los procesos de alergias y en la destrucción de parásitos. La activación del subtipo M2b depende de la exposición a ligandos IL-1R (agonistas de los TLRs) o del contacto con inmunocomplejos (Martínez y Gordon, 2014). Ambos subtipos M2a y M2b promueven una respuesta adaptativa Th2 (Mantovani *et al.*, 2004; Martínez y Gordon, 2014). El subtipo M2c, es estimulado por la IL-10, TGF- β y glucocorticoides que participan en la resolución de la inflamación y remodelación tisular, respectivamente (Mantovani *et al.*, 2004; Hao *et al.*, 2012; Martínez y Gordon, 2014). El subtipo M2d o macrófagos asociados a tumores (TAMs), activados por la IL-6 y productores de TNF- α , contribuye a la progresión y metástasis de tumores (Biswas y Mantovani, 2010). Aunque su fenotipo es M2, también se ha sugerido que pueden tener una función anticancerígena al liberar radicales libres de oxígeno (ROS) y óxido nítrico sintetasa (NOS), citotóxicos para las células tumorales (Mantovani *et al.*, 2004; Martínez y Gordon, 2014). En general, los subtipos de los macrófagos M2 combinan altos niveles de IL-2, IL-10 e IL-23 así como de receptores de la manosa y galactosa. En la Tabla 1 se incluyen los marcadores que expresan estas células así como las proteínas (citocinas y quimiocinas) que producen.

	M1	M2a	M2b	M2c	M2d
Activación	IFN-gamma LPS GM-CSF	IL4 IL-13 Infecciones fúngicas y helmintos	ICs IL-1R	IL-10 TGF-beta GCs	IL-6 LIF Adenosina
Marcadores expresados	CD68 CD86 CD80 MHC II IL-1R TLR2 TLR4 iNOS SOCS3	CD163 MHC II SR MMR/CD206 CD200R TGM2 DecoyR IL-1R II <i>Ratón:</i> <i>Ym1/2</i> <i>Fizz1</i> <i>Arg-1</i>	CD86 MHC II	CD163 TLR1 TLR8	VEGF
Citoquinas producidas	TNF IL-1beta IL-6 IL-12 IL-23	IL-10 TGF-beta IL-1ra	IL-1 IL-6 IL-10 TNF-alpha	IL-10 TGF-beta	IL-10 IL-12 TNF-alpha TGF-beta
Quimiocinas producidas	CCL10 CCL11 CCL5 CCL8 CCL9 CCL2 CCL3 CCL4	CCL17 CCL22 CCL24	CCL1	CCR2	CCL5 CXCL10 CXCL16

Tabla 1. Fenotipo de los macrófagos clásicamente (M1) y alternativamente (M2) activados. (Fuente: Röszer, 2015).

2.5.4.2. Macrófagos e infecciones por micobacterias

En la actualidad, la mayor parte de los conocimientos sobre la relación entre el macrófago y las micobacterias se debe mayoritariamente a estudios realizados *in vitro* (Pai *et al.*, 2003; Zur Lage *et al.*, 2003; Bormann *et al.*, 2011; Abendaño *et al.*, 2013; Huang *et al.*, 2015). Algunos de ellos han puesto de manifiesto que la polarización de los macrófagos no es permanente sino que puede variar a lo largo de la misma en respuesta a las citocinas presentes el medio (Davies *et al.*, 2013; Davies y Taylor, 2015) de forma que su evolución se ha asociado, con frecuencia, a los cambios dinámicos de la activación macrofágica (Benoit *et al.*, 2008). Habitualmente, se considera que las formas M1 serían responsables de la resistencia frente a diversos patógenos (Jouanguy *et al.*, 1999; Shaughnessy y Swanson, 2007) entre los que destacan la infecciones por micobacterias. Concretamente, desempeñarían un papel fundamental en las fases tempranas de infecciones producidas por *M. tuberculosis* (Chacon-Salinas *et al.*, 2005), *M. ulcerans*, *M. avium* y *Map*

(Murphy *et al.*, 2006; Thirunavukkarasu *et al.*, 2015). En este contexto, el cambio de M1 a M2 se observaría durante la transición de la infección aguda a crónica, como parte de la estrategia del organismo de controlar una respuesta inflamatoria desmedida, debida a la activación continua de los macrófagos M1 (Mantovani *et al.*, 2004). Este cambio en el fenotipo podría favorecer las estrategias de evasión de la respuesta inmunológica que han desarrollado los microorganismos (Benoit *et al.*, 2008). En la tuberculosis humana, los macrófagos M1 de los granulomas, que se observan en las primeras fases de la infección, se han asociado con una respuesta de carácter protector frente a la multiplicación de las micobacterias, mientras que los macrófagos M2 que aparecen en las fases avanzadas de la enfermedad, sugieren una respuesta menos efectiva frente a la infección (Huang *et al.*, 2015; Marino *et al.*, 2015). En la paratuberculosis, se ha comprobado que los monocitos sanguíneos de vacas con la infección subclínica, se diferencian tanto hacia macrófagos de fenotipo M1 como a M2 (Thirunavukkarasu *et al.*, 2015).

Como ya se ha indicado previamente, gran parte de la información sobre la polarización M1 o M2 de los macrófagos en infecciones por micobacterias se ha obtenido de estudios *in vitro* que, probablemente, no reflejan adecuadamente la compleja respuesta inmunitaria desarrollada a nivel local *in vivo*, en el microambiente de los granulomas, en concreto en las lesiones, donde se presume que existe una interconexión, directa o por medio de interleucinas, entre las diferentes células que las forman, así como un continuo reclutamiento de nuevas células inflamatorias al foco de infección (Orme y Cooper, 1999; Tanaka *et al.*, 2005; Koets *et al.*, 2015).

En la mayoría de estos estudios, la caracterización fenotípica de los macrófagos se ha realizado mediante la detección del ARNm de diferentes citocinas o su expresión empleando técnicas inmunohistoquímicas (Barros *et*

al., 2013; Huang *et al.*, 2015; Marino *et al.*, 2015). En paratuberculosis, el único estudio realizado (Thirunavukkarasu *et al.*, 2015) únicamente valora macrófagos en sangre periférica mediante estudios de transcripción génica.

2.6. Infecciones experimentales con *Map*

Los modelos de infección experimental son una herramienta útil en el estudio de la paratuberculosis, ya que permiten investigar en su patogenia, eficacia de vacunas, rendimiento de los métodos de diagnóstico o los cambios inmunológicos del hospedador, entre otros aspectos (Begg *et al.*, 2005; Hines II *et al.*, 2007; Begg y Whittington, 2008). Este tipo de estudios, a diferencia de los realizados en condiciones de campo, ofrecen un mayor control sobre las variables que influyen sobre la interacción patógeno-hospedador (Begg y Whittington, 2008).

La mayor parte de infecciones experimentales realizadas hasta el momento se han desarrollado en rumiantes (Hines II *et al.*, 2007; Begg y Whittington, 2008; Koets *et al.*, 2015) en los que la inoculación experimental de *Map* logra reproducir la infección en un alto porcentaje de animales, que muestran patrones similares a los observados en la infección natural, como son el desarrollo de una respuesta inmunitaria específica adaptativa frente a *Map*, lesiones idénticas a aquellas halladas en casos naturales (Juste *et al.*, 1994; Delgado *et al.*, 2012, 2013) y el aislamiento e identificación de la micobacteria en los sujetos infectados (Whittington y Sergeant, 2001; Begg *et al.*, 2005; Verna *et al.*, 2007; Delgado *et al.*, 2013). Otras ventajas de estos estudios es que se puede conocer o es posible determinar el momento en el que el animal entra en contacto con *Map* y la cantidad o tiempo de exposición a la micobacteria (Begg y Whittington, 2008; Delgado *et al.*, 2013; Mortier *et al.*, 2013; Dukkipati *et al.*, 2016). Además, si se consideran los principios generales de la utilización de modelos animales (Davidson *et al.*, 1987), el empleo de rumiantes domésticos como animales experimentales

facilita la extrapolación de la información obtenida, ya que son hospedadores naturales.

Por otro lado, la utilización de animales de laboratorio tiene una serie de ventajas ya que garantiza la uniformidad genética, disminuye la variabilidad individual además de tener un menor coste y ser de fácil manipulación (Davidson *et al.*, 1987; Mapara *et al.*, 2012). Existe un amplio abanico de modelos experimentales empleados en función de la especie animal, raza, cepa, vía de infección, dosis, número y momento de la infección (Hines II *et al.*, 2007; Begg y Whittington, 2008). En el caso de *Map*, mediante la utilización de animales de laboratorio se ha buscado disminuir el periodo de incubación de la enfermedad, si bien en la mayoría de los estudios no se ha conseguido reproducir el cuadro característico de la paratuberculosis, a nivel clínico o lesional (Begg y Whittington, 2008). Dentro de este tipo de animales, el empleo de conejos el que parece ofrecer resultados más satisfactorios, habiendo sido útil para el estudio de eficacia vacunal o vías de administración de vacunas frente a paratuberculosis (Arrazuria *et al.*, 2016a, 2016b).

El largo periodo de incubación de la enfermedad, la falta de estandarización de los modelos experimentales y la variabilidad de los diseños experimentales hacen que exista una gran disparidad entre los hallazgos patológicos y microbiológicos de los distintos estudios, lo que dificulta la comparación objetiva de los resultados (Sweeney *et al.*, 2006; Hines II *et al.*, 2007; Begg y Whittington, 2008). Desafortunadamente, a día de hoy, no hay consenso en un modelo animal único para la reproducción experimental de la paratuberculosis.

Además de los factores intrínsecos a la especie animal, existen diferentes variables que pueden influir en los resultados del experimento (Begg y Whittington, 2008). A continuación, se revisan los principales factores

que juegan un papel importante en el desarrollo de los modelos experimentales empleados en el estudio de la paratuberculosis.

2.6.1. Cepas de *Map*

Se ha demostrado que, en infecciones experimentales dentro de la misma especie, se producen diferencias en la tasa de infección, respuesta inmunitaria o en la intensidad de las lesiones en función de la cepa utilizada, C ó S (Stewart *et al.*, 2004, 2006; O'Brien *et al.*, 2006; Verna *et al.*, 2007).

Sin embargo, es preciso destacar que el número de estudios en los que se tipifican las cepas empleadas son escasos (Reddacliff y Whittington, 2003; Stewart *et al.*, 2004, 2006; Begg *et al.*, 2005, O'Brien *et al.*, 2006; Verna *et al.*, 2007; Dukkupati *et al.*, 2016), lo que impide realizar una adecuada comparación e interpretación de los resultados entre ellos. En los estudios en los que se han empleado cepas tipificadas, se ha evidenciado que las cepas aisladas de bovinos y tipificadas como Tipo C, utilizadas en infecciones experimentales en ovejas, producen lesiones menos intensas, de tipo focal, localizadas en el tejido linfoide intestinal, en comparación con las cepas ovinas, que originan lesiones de mayor entidad, de tipo multifocal o difuso (Verna *et al.*, 2007).

Además del espectro lesional, también se han identificado diferencias en la respuesta inmunitaria según el tipo de cepa. Así, en infecciones experimentales con cepas Tipo S y Tipo C en ganado bovino, ovino y caprino las cepas Tipo C fueron más patógenas que las S, independientemente de la especie, en cuanto a una mayor respuesta inmunitaria, tanto celular como humoral, así como mayor presencia de *Map* en los tejidos (Stewart *et al.*, 2004, 2006, 2007). También en cérvidos infectados experimentalmente con cepas bovinas se ha observado una elevada respuesta inmunitaria, así como una mayor detección de *Map* en tejidos y en heces que cuando son

infectados con cepas ovinas (O'Brien *et al.*, 2006; Mackintosh *et al.*, 2007). La infección experimental por *Map* con aislados ovinos en corderos induce el desarrollo de una respuesta inmunitaria celular sin presencia de lesiones en animales examinados a los 3-4 mpi (Reddacliff y Whittington, 2003). Sin embargo, en otro estudio con sacrificios más tardíos (13 mpi) sí se observaron lesiones asociadas. (Begg *et al.*, 2005).

La mayoría de los estudios experimentales con bovinos han utilizado cepas bovinas, tanto tipificadas (Sweeney *et al.*, 2006; Mortier *et al.*, 2014) como aislados procedentes de animales enfermos (Stabel *et al.*, 2003; Stewart *et al.*, 2007) (Tabla 3). También se han comprobado diferencias en la respuesta inmunitaria celular desarrollada por terneros infectados con cepas de bisonte (subtipo de las cepas C) respecto a los bisontes infectados con esas mismas cepas (Stabel *et al.*, 2003). En cabras, se han empleado cepas Tipo C en infecciones experimentales (Storset *et al.*, 2001; Stewart *et al.*, 2006; Köhler *et al.*, 2015; Krüger *et al.*, 2015) y se apreció un incremento significativo respecto de los controles en la respuesta inmunitaria celular entre las 7 y 11 semanas post infección y en la respuesta humoral entre las 15 y 20 semanas, que se mantuvo durante al menos un año (Storset *et al.*, 2001; Krüger *et al.*, 2015). En otra infección experimental en cabras donde se emplearon tanto cepas ovinas como bovinas se observó que los animales infectados con cepas Tipo C desarrollaban una respuesta inmunitaria celular y humoral más fuerte, así como lesiones más graves y excreción continua de *Map* respecto al grupo infectado con las cepas Tipo S (Stewart *et al.*, 2006).

2.6.2. Tipo de inóculo

En las experiencias realizadas hasta el momento, se han utilizado principalmente dos tipos de inóculo: micobacterias purificadas a partir de homogeneizados de tejido intestinal procedente de animales infectados de forma natural y cultivos laboratoriales de micobacterias aisladas a partir de

heces o tejidos (Hines II *et al.*, 2007; Begg y Whittington, 2008). Para valorar las diferencias en la patogenicidad entre ambos tipos de inóculo se han evaluado la respuesta inmunitaria, las lesiones histológicas y la identificación de la micobacteria (Verna *et al.*, 2007; Delgado *et al.*, 2013). El uso directo del mismo inóculo a partir de homogeneizado intestinal, en sucesivos experimentos es limitado ya que depende de la cantidad de material disponible (Begg y Whittington, 2008). Además, tiene el inconveniente de que no se conocen sus características, hecho que se agrava cuando se hace necesario emplear material de otro animal, ya que podría contener cepas diferentes o distinta concentración de micobacterias (Reddacliff y Whittington, 2003; Begg y Whittington, 2008).

Sin embargo, se ha comprobado que la inoculación de homogeneizado intestinal reproduce más fácilmente la infección paratuberculosa en el animal atendiendo al desarrollo de la respuesta inmunitaria, excreción fecal y presencia de lesiones en comparación con el inóculo elaborado con micobacterias tras su cultivo laboratorial (Stewart *et al.*, 2004, 2006, 2007; Begg *et al.*, 2005, 2010). Hay que destacar que en esos estudios las cepas cultivadas empleadas en el inóculo fueron aisladas de diferentes ovejas, distintas aquellas a partir de las cuales se elaboró el homogeneizado intestinal, por lo que los resultados deben ser considerados con cuidado.

En diversos trabajos se ha señalado que la adaptación de *Map* al crecimiento en condiciones laboratorias se acompaña en un cambio de fenotipo (Whittington *et al.*, 1999; Begg *et al.*, 2005). En este sentido, se ha demostrado una reducción en la expresión de la proteína de membrana MAP4336, participante en la virulencia de *Map*, en la cepa estandarizada K-10 tras 16 pases por cultivo en comparación con la cepa bovina 187 aislada tras dos pases por cultivo, donde esa expresión fue mucho mayor (Radosevich *et*

al., 2007). Estos hallazgos sugieren que los países por cultivo laboratorial podrían disminuir la virulencia o su antigenicidad.

Se han empleado micobacterias purificadas a partir de homogeneizados intestinales con éxito en la reproducción de la paratuberculosis en bovinos (Muñoz, 2014; Stabel *et al.*, 2009), ovinos (Begg *et al.*, 2005, 2010) y caprinos (Stewart *et al.*, 2006), habiéndose llegado a reproducir la enfermedad clínica en algunos casos (Gwozdz *et al.*, 2001; Kurade *et al.*, 2004; Stewart *et al.*, 2004; Begg *et al.*, 2010; Eisenberg *et al.*, 2011). Los animales infectados con el homogeneizado intestinal excretaron micobacterias en heces, mostraron lesiones características y desarrollaron signos clínicos típicos en ocasiones. Además, en cabras, la respuesta inmunitaria humoral fue más temprana en aquellos animales en los que se utilizó el homogeneizado intestinal como inóculo (Stewart *et al.*, 2006). Por su parte, la gran ventaja de emplear cultivo bacteriano como inóculo infectante es que no tiene limitaciones para reproducir nuevos experimentos, se controla la dosis y el tiempo de exposición y se conoce las características de la micobacteria que se administra (Reddacliff y Whittington, 2003; Begg y Whittington, 2008). Las infecciones experimentales en ovinos a partir de este tipo de inóculos han reflejado resultados dispares en relación a la tasa de infección, desde escasa hasta casi el 100 % de los animales (Thorel *et al.*, 1992; Hines II *et al.*, 2007; Begg y Whittington, 2008) (Tabla 2).

De forma opuesta, en el estudio de Verna *et al.* (2007) se comprobó que los animales inoculados a partir de cepas bovinas cultivadas presentaban lesiones más graves y una respuesta inmunitaria más intensa que aquellos infectados a partir de homogeneizado intestinal procedente de vacas enfermas. Las variaciones en la patogenicidad entre los diferentes tipos de inóculo (Stewart *et al.*, 2007; Verna *et al.*, 2007; Begg y Whittington, 2008)

podrían explicar las diferencias observadas entre los animales infectados (Hines II *et al.*, 2007; Begg y Whittington, 2008).

2.6.3. Dosis infectiva y vía de administración

Hasta el momento no hay un criterio establecido para estandarizar la dosis necesaria para reproducir experimentalmente la paratuberculosis. Se considera que debe ser lo suficientemente alta como para reproducir la infección en los animales diana pero no excesiva, para que la respuesta del hospedador no se aleje de lo que sucedería tras la infección en condiciones naturales (Hines II *et al.*, 2007; Begg y Whittington, 2008). El número de inoculaciones y su frecuencia también deben tenerse en cuenta, puesto que existe una gran diversidad en los estudios realizados, desde 1 a 25 inoculaciones. También es aconsejable que el tiempo entre ellas sea corto, para que el animal no desarrolle una respuesta inmunitaria efectiva (Begg y Whittington, 2008). Así, se han descrito diferencias en los resultados de infecciones experimentales en función de la dosis infectiva (Delgado *et al.*, 2013). En ese estudio, únicamente en los animales infectados con la dosis alta (McGregor *et al.*, 2012; Delgado *et al.*, 2013) se aisló *Map* mediante cultivo y se identificaron lesiones compatibles con paratuberculosis.

Por último, se debe tener en cuenta la vía de administración del inóculo para garantizar que la micobacteria entre en contacto con el hospedador, por la ruta adecuada y en cantidad suficiente, aspectos que se detallan en los siguientes apartados y en las Tablas 2 y 3. La administración oral es la más empleada por ser la que mejor simularía la infección natural (Begg y Whittington, 2008), si bien requiere una mayor cantidad de micobacterias que las vías parenterales como la intravenosa o intraperitoneal (Johnson *et al.*, 1977; Reddacliff y Whittington *et al.*, 2003; Allen *et al.*, 2009). La comparación entre experimentos que utilizan diferentes vías de inoculación es compleja, puesto que no se puede calcular la pérdida de

micobacterias ni la virulencia en función de cómo *Map* entra en contacto con el hospedador. A continuación se detallan las características de las principales infecciones experimentales en rumiantes y otras especies realizadas más recientemente.

2.6.4. Modelos experimentales ovinos

El ganado ovino presenta una serie de ventajas como modelo de elección para una infección experimental: son hospedadores naturales de *Map*, tienen un menor coste económico y son más manejables que el ganado vacuno (Begg *et al.*, 2005; Beeg y Whittington, 2008). Además permiten la expresión de patrones de la enfermedad extrapolables a otras especies animales (Begg *et al.*, 2005). Las infecciones experimentales con el ganado ovino se han llevado a cabo fundamentalmente en zonas donde la paratuberculosis es un problema en esta especie, Oceanía y Europa principalmente (Tabla 2).

El objetivo de los distintos estudios ha sido variable. Mientras que unos casos se enfocan a comprobar si los animales pueden infectarse experimentalmente por las propias cepas presentes en una zona geográfica determinada, otros se dirigen a estudiar la respuesta inmunitaria del animal frente a *Map* y la patogenia de la infección (Begg y Whittington, 2008). Como inóculo infeccioso se han utilizado tanto aislados de vaca como de oveja (Begg y Whittington, 2008). Sin embargo, son escasos los trabajos en los que se han empleado cepas tipificadas para llevar a cabo la infección (Begg *et al.*, 2005; Stewart *et al.*, 2004; Begg *et al.*, 2010; Dukkipati *et al.*, 2016). Existen estudios experimentales en ovinos donde se han utilizado tanto cepas cultivadas Tipo S (Begg *et al.*, 2005; Dukkipati *et al.*, 2016) como Tipo C (Stewart *et al.*, 2004), así como homogeneizados procedentes de ovinos enfermos (Verna *et al.*, 2007; Delgado *et al.*, 2013). En ellos se han obtenido resultados variables en cuanto a la tasa de infección y a la

presentación clínica de la enfermedad (McGregor *et al.*, 2012; Delgado *et al.*, 2013; Dukkipati *et al.*, 2016).

Esta gran variabilidad de resultados podría estar relacionada con los diferentes diseños experimentales empleados. Por ejemplo, la variabilidad observada en la respuesta inmunitaria desarrollada por las ovejas tras la infección puede explicarse por las diferencias existentes entre las cepas utilizadas en el inóculo, puesto que se emplean tanto cepas virulentas para la oveja como otras que en condiciones naturales no infectarían a esta especie (Begg y Whittington, 2008). También se ha comprobado que la genética individual del animal participa de forma determinante en el desarrollo de la enfermedad, puesto que los ovinos infectados en los que se detecta una mayor producción de IgG e IgA a nivel de la mucosa intestinal superan mejor o sobreviven a la infección con una cepa Tipo S (Begg *et al.*, 2015). Incluso, se han señalado diferencias dentro de una misma raza, como la Merina, posiblemente relacionadas con factores ambientales (Dukkipati *et al.*, 2016).

Por lo que se refiere a las vías de infección, la vía oral es la más comúnmente utilizada (Tabla 2). Sin embargo, también se han empleado rutas alternativas como la intratonsilar (Begg *et al.*, 2005), endoestomacal (Gwozdz *et al.*, 2000 y 2001) o intravenosa (Thorel *et al.*, 1992). Todas ellas han reproducido la infección y la enfermedad clínica aunque con diferentes respuestas inmunológicas y signos clínicos. Los animales inoculados por vía intravenosa no mostraron signos clínicos pero el porcentaje de infectados fue muy variable, desde el 0% (Thorel *et al.*, 1992) hasta el 81 % (Brotherson *et al.*, 1961).

Tabla 2: Principales infecciones experimentales realizadas en ovinos.

Referencia	Raza	Cepa utilizada	Tipo de Inóculo	Vía de inoculación	Edad	Duración	Signos clínicos	Tasa de Infección
Thorel <i>et al.</i> , 1992	Grivette	Ovina	Cultivo	I.V	<1 m	2 años	0	0
Juste <i>et al.</i> , 1994	Rasa	Bovina	Cultivo	Oral	50 d	220 d	n/d	n/d
Beggara-McGorum <i>et al.</i> , 1998	Dorset	Ciervo	n/d	Oral	5 d	700 d	0 %	100%
Beard <i>et al.</i> , 2000	Suffolk-Texel	Ciervo	n/d	Oral	8-19 d	28 d	0 %	0 %
Gwozdz <i>et al.</i> , 2001	n/d	Ovina	HI	Estomacal	1-4 s	108 d	50 %	50 %
Reddacliff y Whittington, 2003	Merino	Ovina*	Cultivo	Oral	3-4 m	14 s	0 %	0 %
Kurade <i>et al.</i> , 2004	Cruzada	Ovina	HI	Oral	8-12 s	330 d	15 %	35 %
Stewart <i>et al.</i> , 2004	Merino	Ovina*	Cultivo	Oral	10 m	35 m	20 %	n/d
Stewart <i>et al.</i> , 2004	Merino	Bovina*	Cultivo	Oral	6 m	54 m	20 %	n/d
Begg <i>et al.</i> , 2005	Merino	Ovina*	Cultivo	Oral	3 m	22 m	33 %	53 %
Begg <i>et al.</i> , 2005	Merino	Ovina*	Cultivo	Intratonsilar	3 m	16 m	0 %	66 %
Reyes, 2007	Churra	-	-	S.C	1 m	15- 75 d	n/d	n/d
Verna <i>et al.</i> , 2007	Churra	Bovina*	Cultivo	Oral	1 m	150 d	n/d	100 %
Verna <i>et al.</i> , 2007	Churra	Bovina	HI	Oral	1 m	150 d	n/d	100 %
Verna <i>et al.</i> , 2007	Churra	Ovina	HI	Oral	1 m	150 d	n/d	100 %
Begg <i>et al.</i> , 2010	Merino	Ovina*	Cultivo	Oral	3 m	23 m	48 %	72 %
Delgado <i>et al.</i> , 2013	Churra	Ovina*	Cultivo	Oral	1,5m; <11 y	120- 220 d	0 %	92,3%
Dukkipati <i>et al.</i> , 2016	Merino	Ovina*	Cultivo	Oral	4 m	63 s	30 %	92 %

n/d: no disponible; C: cultivo; HI: homogeneizado intestinal. I.V: intravenosa. d: días; s: semana; m: meses; y; año. *Cepa tipificada

2.6.5. Modelos experimentales bovinos

Las infecciones experimentales en el ganado bovino se han realizado con mayor frecuencia que en el ovino, sobre todo en Europa y América del Norte. La mayoría se han llevado a cabo utilizando aislados bovinos propios y solo algunos trabajos han tenido como objetivo la infección cruzada con cepas Tipo S (Tabla 3). En los primeros, se han observado diferencias significativas en la virulencia entre las diferentes cepas de *Map* aisladas de bovinos (Simutis *et al.*, 2005; Sweeney *et al.*, 2006). También se ha documentado que los terneros son susceptibles a cepas aisladas de bisonte (Tipo B, subtipo dentro del Tipo C) infectándose la totalidad de los animales expuestos y que las crías de bisontes lo son a las cepas bovinas Tipo II (Stabel *et al.*, 2003). Stewart *et al.* (2007) infectaron terneros con cepas ovinas y bovinas procedentes de cultivo laboratorial y a partir de homogeneizado intestinal. En este estudio, el inóculo elaborado a partir de la purificación del homogeneizado intestinal bovino resultó ser el más patógeno, con una respuesta inmunitaria más fuerte y excreción continua de *Map*.

Generalmente, tras la inoculación experimental, los índices de infección en el bovino son elevados aunque, en los experimentos realizados, muy pocos animales llegan a desarrollar signos clínicos, al contrario de lo que ocurre en los ovinos. La hipótesis más aceptada para explicar este hecho es que los animales utilizados en estudios experimentales son sacrificados antes de que la enfermedad se manifieste en su forma clínica, que tiene lugar, aproximadamente, transcurridos unos 2 años tras la inoculación (Whitlock y Buergelt, 1996).

Al igual que en el modelo experimental ovino, se han probado diversas vías de inoculación como la oral (Sweeney *et al.*, 2006), intratonsilar (Waters *et al.*, 2003), subcutánea (Simutis *et al.*, 2005), intravenosa (Johnson *et al.*, 1977), intrauterina (Merkal *et al.*, 1982) e intraperitoneal (Stabel *et al.*, 2009 y

2011). Estos estudios han demostrado una influencia clara de la vía de inoculación sobre la patogenia de la enfermedad (Begg y Whittington, 2008). Las vías de administración parenterales utilizadas (Johnson *et al.*, 1977; Waters *et al.*, 2003; Stabel y Robbe- Austerman, 2011) han demostrado tener tasas de infección cercanas al 100 % de los animales infectados. Sin embargo, en esos mismos estudios no se han reproducido los signos característicos de la enfermedad, hecho que si se ha observado en infecciones experimentales por vía oral (Eisenberg *et al.*, 2011).

A continuación (Tabla 3) se muestran los estudios experimentales desarrollados en la especie bovina durante los últimos años:

Tabla 3: Principales infecciones experimentales realizadas en la especie bovina.

Referencia	Raza	Cepa utilizada	Tipo de inóculo	Vía de inoculación	Edad	Duración	Signos clínicos	Tasa de Infección
Johnson <i>et al.</i> , 1977	Holstein	Bovino	Cultivo	I.V	21 d	153 d	n/d	100 %
Johnson <i>et al.</i> , 1977	Holstein	Bovino	Cultivo	S.C	21 d	153 d	n/d	100 %
Beard <i>et al.</i> , 2001b	Holstein	Bovina*	Cultivo	Oral	1-5 d	6 m	0%	75 %
Stabel <i>et al.</i> , 2003	Cruzada	Bovino	Cultivo	Estomacal	2 s	6 m	0 %	83 %
Stabel <i>et al.</i> , 2003	Cruzada	Bisonte	Cultivo	Estomacal	2 s	6 m	0 %	100%
Uzonna <i>et al.</i> , 2003	Holstein	Bovino	Cultivo	Oral	28 d	21 d	0 %	100 %
Waters <i>et al.</i> , 2003	Holstein	Bovino	HI	Intratonsilar	2 s	320 d	0 %	100 %
Simutis <i>et al.</i> , 2005	Holstein	Bovina*	Cultivo	Subcutánea	4-5 s	150 d	n/d	0 %
Sweeney <i>et al.</i> , 2006	Holstein	Bovina*	Cultivo	Oral	2 d	44 d	0 %	100 %
Stewart <i>et al.</i> , 2007	Holstein	Bovina/Ovina	Cultivo	Oral	4 s	14 m	0 %	50 %
Stabel <i>et al.</i> , 2009	Holstein	Bovina*	Cultivo	Oral /I.P	2 s	360 d	n/d	n/d
Allen <i>et al.</i> , 2011	Holstein	Humana	Cultivo	Intraileal	2 s	18 m	0 %	25 %
Eisenberg <i>et al.</i> , 2011	Holstein	Bovina*	Cultivo	Oral/Intranasal	3 s	12 m	16 %	25 %/20 %
Stabel y Robbe-Austerman, 2011	Holstein	Bovina*	Cultivo	Oral/I.P	1 s	12 m	0 %	50 %/100%
Santema <i>et al.</i> , 2012	Holstein	Bovina	HI	Oral	3 s	606 d	0 %	n/d
Mortier <i>et al.</i> , 2014	Holstein	Bovina*	Cultivo	Oral	2 s	17 m	0 %	75%
Muñoz, 2014	Holstein	Bovina*	H.I	Oral	2 m	330 d	-	-

n/d: no disponible; HI: homogeneizado intestinal. I.V: intravenosa. S.C: subcutánea d: días; s: semana; m: meses. *Cepa tipificada

2.6.6. Infecciones experimentales en otras especies

En los últimos años, también se han llevado a cabo infecciones experimentales en otras especies empleando cepas cultivadas u homogeneizado purificado tomado de animales enfermos. Entre ellos destacan los realizados en cabras con cepas bovinas y ovinas (Stewart *et al.*, 2006) o cepas bovinas (Hines II *et al.*, 2014; Köhler *et al.*, 2015; Krüger *et al.*, 2015), en ciervos (O'Brien *et al.*, 2006; Mackintosh *et al.*, 2010) o en bisontes (Stabel *et al.*, 2003). Particularmente en cabras, las infecciones se han llevado a cabo con cepas bovinas estandarizadas (K-10) y son en la actualidad, uno de los modelos animales más utilizados, debido al desarrollo de una respuesta inmunitaria y lesional semejante al ganado vacuno (Krüger *et al.*, 2015). En ciervos se han observado diferencias considerables en función de la cepa utilizada, con una tasa de infección y respuesta inmunitaria más elevada al utilizar cepas bovinas en comparación con los animales infectados con cepas ovinas (O'Brien *et al.*, 2006).

Además de las especies de interés ganadero, también se han empleado animales de laboratorio como modelos experimentales, siendo los ratones (Koets *et al.*, 2000; Tanaka *et al.*, 2000; Koc *et al.*, 2014) y los conejos (Vaughan *et al.*, 2005; Arrazuria *et al.*, 2016b) las principales especies utilizadas. La razón para su empleo reside en el amplio conocimiento inmunológico y microbiológico de estos animales, desarrollo rápido de la infección, manejo más sencillo y costes menores que en otras especies (Davidson *et al.*, 1987; Mokresh y Butler, 1990; Begg y Whittington, 2008).

Los conejos infectados experimentalmente de forma oral, a pesar de que no desarrollan signos clínicos, sí muestran lesiones granulomatosas en tramos intestinales y es posible aislar la micobacteria mediante cultivo e identificación con PCR (Arrazuria *et al.*, 2016b). Dado que los conejos muestran una respuesta inmunitaria específica tras la infección por *Map*,

similar a lo que sucede en los rumiantes, hospedadores naturales, podrían utilizarse como modelo animal para pruebas vacunales o diagnósticas (Arrazuria *et al.*, 2016b). A pesar de las ventajas, también existen inconvenientes para su uso ya que las vías de infección habituales, frecuentemente distintas a la oral, alterarían la respuesta inmunitaria o el desarrollo de la enfermedad que tiene lugar en condiciones naturales (Mokresh y Butler, 1990; Begg y Whittington, 2008). Además, la microflora presente en el intestino de los conejos podrían contribuir a dichas diferencias (Arrazuria *et al.*, 2015).

En el caso de los ratones, se ha demostrado que los son más resistentes a la infección cuando se infectan por vía oral que cuando la inoculación es intraperitoneal (Mutwiri *et al.*, 1992). Además, su diferente metabolismo y respuesta inmunológica respecto a especies animales de interés doméstico (bovino y ovino) puede alterar la reproducción de la enfermedad, y por tanto, los resultados obtenidos no tendrían relación con lo observado en condiciones naturales (Hein y Griebel, 2003).

3. JUSTIFICACIÓN Y OBJETIVOS

JUSTIFICATION & OBJECTIVES

A pesar de ser una enfermedad conocida ya desde finales del siglo XIX, la paratuberculosis sigue teniendo una gran repercusión económica mundial principalmente porque no se han logrado establecer procedimientos de control eficaces. Esto se debe, entre otras causas, a que aún se desconocen muchos de los aspectos de la patogenia de esta enfermedad como los factores que, en la interacción hospedador-patógeno, determinan la evolución que van a seguir los animales infectados, que no siempre acaban desarrollando la enfermedad clínica (Stabel, 2000a; Gillan *et al.*, 2010; Arsenault *et al.*, 2014; Koets *et al.*, 2015).

El **planteamiento** general de esta Tesis Doctoral se enmarca dentro de la línea de investigación sobre patogenia de la paratuberculosis que lleva el grupo de trabajo donde se ha realizado. En estudios previos, se ha determinado que los animales infectados por *Map* desarrollan distintos tipos de lesión que están estrechamente asociados a las fases que aparecen en el curso de la enfermedad (Pérez *et al.*, 1996, 1997, 1999; González *et al.*, 2005; Brady *et al.*, 2008; Koets *et al.*, 2015). El conocimiento de los factores que puedan tener relación con la presentación de dichas lesiones puede contribuir a elucidar aspectos importantes de la patogenia de la paratuberculosis.

La *hipótesis* que sustenta este trabajo surge de las observaciones previas ya expuestas que sugieren que el desarrollo de las diferentes lesiones asociadas a la paratuberculosis podría estar relacionado con distintos factores, entre ellos algunos debidos al agente etiológico y otros al hospedador, como la respuesta inmunitaria local. Por todo lo indicado anteriormente, el **objetivo general** que se persigue en este trabajo de Tesis Doctoral es **contribuir al conocimiento de la patogenia de la paratuberculosis, en concreto al estudio de las formas de lesión asociadas y su relación con factores que pueden contribuir a su aparición.**

Como ya se ha señalado en el capítulo previo, desde hace ya unos años se conoce la existencia de distintas cepas de *Map*, clasificadas en dos grandes grupos o genotipos: por un lado, las cepas Tipo S (Tipo I y III), aisladas por primera vez a partir de muestras ovinas, y por otro, las cepas Tipo C (Tipo II) procedentes de ganado bovino (Collins *et al.*, 1990; Whittington *et al.*, 2011; Stevenson *et al.*, 2002; Sevilla *et al.*, 2005; Castellanos *et al.*, 2009). A pesar de esa fuerte dependencia del hospedador, se han descrito casos de infección cruzada entre distintas especies animales tanto con cepas S como C (Whittington *et al.*, 2001b; Moloney y Whittington, 2008; Fritsch *et al.*, 2012; Dimarelli-Malli *et al.*, 2013; Verdugo *et al.*, 2014). Hay estudios previos que apuntan a que pudieran existir variaciones en la respuesta inmunitaria (Janagama *et al.*, 2006; Borrmann *et al.*, 2011; Abendaño *et al.*, 2013) o en las lesiones (Verna *et al.*, 2007) que desarrollan los animales infectados por *Map* en función del tipo de cepa, si bien en algunos de estos estudios los inóculos utilizados no habían sido completamente tipificados y caracterizados. El **primer objetivo** de este trabajo fue **evaluar la influencia de la utilización de diferentes cepas estandarizadas de *Map* en la patogenia de la paratuberculosis, en concreto en el desarrollo de lesiones y la respuesta inmunitaria asociada, sobre un modelo experimental ovino.**

En la reproducción experimental de la paratuberculosis, herramienta fundamental para el conocimiento de la enfermedad, y en concreto en la aparición de lesiones, son varios los factores que influyen, muchos de ellos posiblemente aún desconocidos. Para llevar a cabo infecciones experimentales en la especie ovina se recomienda la utilización de cepas Tipo S para aproximar ese estudio experimental a lo que sucedería en condiciones naturales (Hines II *et al.*, 2007; Begg y Whittington, 2008). Sin embargo, las dificultades que este tipo de cepa entraña para su cultivo y crecimiento (Whittington *et al.*, 2011) ha hecho que en la mayor parte de los estudios experimentales se hayan empleado micobacterias directamente obtenidas a

partir de homogeneizados intestinales de ovejas enfermas (Stewart *et al.*, 2004; Verna *et al.*, 2007; Begg y Whittington, 2008; Delgado *et al.*, 2013) en los cuáles no se conoce con exactitud la naturaleza del material infectante administrado ni la dosis. En estudios previos se han encontrado diferencias en patogenicidad, y por lo tanto en el desarrollo de lesiones, según el inóculo fuera un homogeneizado intestinal o una cepa obtenida tras su aislamiento y multiplicación en medios de cultivo (Begg *et al.*, 2005; Begg y Whittington, 2008). Sin embargo, en estos trabajos se han empleado cepas distintas, obtenidas de diferentes animales, y no se ha comprobado si la misma cepa de *Map*, tras su aislamiento en medios de cultivo, sufre cambios en su patogenicidad. Por ello, el **segundo objetivo** fue **valorar la influencia que ejerce el cultivo y procesado laboratorial de una cepa Tipo S de *Map* sobre la patogenicidad del inóculo en una infección experimental en la especie ovina, atendiendo a las lesiones y a la respuesta inmunitaria observada.**

Con la realización de los estudios diseñados para dar respuesta a los dos objetivos anteriores se pretende contribuir también, como objetivo adicional, a un mejor conocimiento de algunos de los factores que deben considerarse a la hora de realizar infecciones experimentales de paratuberculosis en la especie ovina.

Otros factores más relacionados con el hospedador, como la respuesta inmunitaria local, también podrían relacionarse con la aparición de las distintas formas lesionales de la paratuberculosis. Los macrófagos son el componente celular más importante de la lesión granulomatosa, lugar donde se produce la interacción patógeno-hospedador (Sigurdardóttir *et al.*, 2004). Esto va a determinar la evolución de la infección por *Map*, de forma que puede ser controlada, persistiendo en forma latente durante tiempo prolongado, o evolucionar hacia formas graves, dependiendo de una serie de mecanismos que se ponen en marcha en los macrófagos y que pueden bien

inhibir o facilitar la multiplicación de *Map* (Sigurdardóttir *et al.*, 2004; Valheim *et al.*, 2004).

Diversos estudios recientes han puesto de manifiesto que una de las características singulares de los macrófagos, y que se conserva entre especies, es su elevada diversidad y plasticidad funcional, lo que se ha denominado polarización de los macrófagos, con distintas poblaciones o fenotipos de estas células según la función que estén desempeñando (Sica y Mantovani, 2012; Davies *et al.*, 2013; Marino *et al.*, 2015). La caracterización de estas poblaciones se ha llevado a cabo mediante la valoración de la expresión diferencial, en estas células, de distintas moléculas con acción sobre la respuesta inmunitaria o inflamatoria (Mantovani *et al.*, 2004; Sica y Mantovani, 2012; Martínez y Gordon, 2014). En el caso de la paratuberculosis, este aspecto apenas ha sido investigado (Thirunavukkarasu *et al.*, 2015) y nunca en los macrófagos presentes en las lesiones. Teniendo en cuenta estos antecedentes, el **tercer objetivo** fue **caracterizar mediante técnicas inmunohistoquímicas las poblaciones de macrófagos presentes en distintos tipos de lesiones granulomatosas asociadas a la infección por *Map*.**

Se conoce que existe una estrecha relación entre las formas lesionales de la paratuberculosis y la respuesta inmunitaria periférica, en concreto con la producción de INF- γ por las células sanguíneas (Pérez *et al.*, 1997, 1999; Burrells *et al.*, 1998; Sohal *et al.*, 2008; Koets *et al.*, 2015). Sin embargo, apenas se ha investigado su asociación con la respuesta inmunitaria local, aunque algunas evidencias sugieren que la producción de INF- γ a nivel local (intestino y nódulos linfáticos) no se correspondería directamente con la periférica (Lee *et al.*, 2001, Reddacliff *et al.*, 2004; Smeed *et al.*, 2007). La mayor parte de trabajos han estudiado los niveles de transcripción génica de INF- γ en tejidos de animales en distintas fases de la enfermedad, con resultados contradictorios entre ellos (Tanaka *et al.*, 2005; Gillan *et al.*, 2010).

Además no se ha valorado la expresión *in situ* de IFN- γ sobre las lesiones empleando métodos inmunohistoquímicos. Únicamente Reddacliff *et al.* (2004) utilizaron este tipo de técnicas para valorar la expresión local de esta citocina en ovinos infectados experimentalmente pero que no mostraban lesiones macro o microscópicas y en los que no pudieron realizarse comparaciones con los animales control no infectados.

Teniendo en cuenta la importancia que podría tener la expresión local de IFN- γ en el lugar primario de la infección -el intestino- sobre las lesiones que se observan en esta localización, el **cuarto objetivo** que se planteó fue **caracterizar la expresión local de IFN- γ , principal citocina que interviene en la respuesta inmunitaria en paratuberculosis, en los diferentes tipos de lesión asociados a la infección por *Map*.**

Para la consecución de los dos últimos objetivos se han empleado muestras de tejido procedentes de animales de la **especie bovina**, con infección natural o infectados experimentalmente, debido a la disponibilidad comercial, en esta especie, de un mayor surtido de anticuerpos capaces de reconocer las moléculas a estudiar que en pequeños rumiantes.

4. METODOLOGÍA Y RESULTADOS

METHODOLOGY & RESULTS

4.1. PRIMER ESTUDIO

FIRST STUDY



Fernández M, Benavides J, Sevilla IA, Fuertes M, Castaño P, Delgado L, García-Marín JF, Garrido JM, Ferreras MC, Pérez V. **Experimental infection of lambs with C and S-type strains of *Mycobacterium avium* subspecies *paratuberculosis*: immunological and pathological findings.** *Vet Res.* 2014; 45:5.

Factor de impacto 2,815

Veterinary Sciences 3/133

4.1. Experimental infection of lambs with C and S-type strains of *Mycobacterium avium* subspecies *paratuberculosis*: immunological and pathological findings

Miguel Fernández¹, Julio Benavides¹, Iker A. Sevilla², Miguel Fuertes¹, Pablo Castaño¹, Laetitia Delgado¹, J. Francisco García Marín¹, Joseba M. Garrido², M. Carmen Ferreras¹ and Valentín Pérez^{1*}

¹Departamento de Sanidad Animal, Instituto de Ganadería de Montaña (CSIC-ULE), Facultad de Veterinaria, Universidad de León, Campus de Vegazana s/n, León 24071, Spain.

²Departamento de Sanidad Animal, NEIKER-Tecnalia, Berreaga 1, Derio, Bizkaia 48160, Spain.

* Corresponding author: Valentín Pérez (vperp@unileon.es)

Received: 9 September 2013. Accepted: 8 January 2014

Published: 16 January 2014

Abstract

The two main genotypes of recognized isolates of *Mycobacterium avium* subsp. *paratuberculosis* (*Map*) are cattle (C) and sheep (S) strains. An experimental infection was conducted to establish the effect of *Map* strain on the pathogenesis of ovine paratuberculosis. Twenty-four out of thirty 1.5-month-old Assaf lambs were divided into 4 groups of 6 and infected orally with three low passage field isolates, two of S- (22G and the pigmented Ovicap49) and one of C- (764) type, and the reference K-10 strain (C type). The remaining six animals were unchallenged controls. Animals were euthanized at 150 and 390 days post-infection (dpi). Throughout the experiment, the peripheral immune response was assessed and histological

and molecular (PCR) studies were conducted on samples of intestine and related lymphoid tissue. Specific antibody and IFN- γ production was significantly higher in animals infected with the C strains, while no consistent IFN- γ responses were observed in the S-type strain infected groups. A positive intradermal skin test response was detected in all infected groups. Lambs infected with S-type strains had granulomatous lesions restricted to the lymphoid tissue with no differences in the lesion intensity over time. In both C-type strain groups, lesions were more severe at 150 dpi while at 390 dpi lesions, characterized by well-demarcated granulomas with fibrosis, decreased in severity. Only infected lambs were positive to PCR. These results suggest that the strain of *Map* has a strong influence over the immune and pathological responses developed by the host. Lesions induced by C-type strains in lambs show a regressive character and tend to decrease as the infection progresses.

4.1.1. Introduction

Paratuberculosis or Johne's disease, caused by *Mycobacterium avium* subspecies paratuberculosis (*Map*), is a chronic infection of domestic and wild ruminants characterized by granulomatous enteritis and lymphadenitis. It occurs worldwide and causes high economic losses to domestic livestock. Clinical disease results in a progressive loss of weight, usually with chronic diarrhoea, and eventual death of the infected animals.

Pathogenesis of paratuberculosis is still poorly understood. It is assumed that animals become infected early in life and can develop a variety of responses: resistance to infection, an asymptomatic status in which animals remain subclinically infected for life, or clinical disease (Clarke, 1997; Gillan *et al.*, 2010; Whittington *et al.*, 2012). Different pathological responses have also been detected among infected animals, both in natural and experimental cases depending on the intensity, location, cellular types and

number of acid-fast bacilli present in the granulomas (Nisbet *et al.*, 1962; Pérez *et al.*, 1996; González *et al.*, 2005). Briefly, these lesions are divided into focal forms, characterized by the presence of small granulomas restricted to the Peyer's patches; multifocal lesions with granulomas present in the intestinal mucosa regardless of its association with lymphoid tissue, and diffuse forms, related to clinical signs, characterized by a widespread and diffuse granulomatous enteritis.

It has been suggested that these differences could be related to the immune response mounted by the host in such a way that a great number of asymptomatic animals with focal or multifocal lesions show an intense cell-mediated immune response, while the detection of the humoral immunity would be related to clinical disease (Clarke *et al.*, 1996; Pérez *et al.*, 1997; Pérez *et al.*, 1999). There is also evidence suggesting that these variations in pathogenesis could be due to differences in the microorganism (Stewart *et al.*, 2004; O'Brien *et al.*, 2006; Bormann *et al.*, 2011).

The existence of distinct strains of *Map* based on phenotypic differences has been recognised for some time (Taylor, 1951). Recently the use of IS900 restriction fragment length polymorphism (RFLP) and IS1311 PCR-restriction enzyme analysis (PCR-REA) methods, has led to the classification of *Map* strains into two main genotypes: sheep or ovine isolates (also called "S-type" or "type-I and III") and cattle or bovine isolates (also called "C-type" or "type II") (Collins *et al.*, 1990; Marsh *et al.*, 1999; Stevenson *et al.*, 2002). Although not common, cross-species infections have been documented (Moloney and Whittington, 2008; Whittington *et al.*, 2011; Dimarelli-Malli *et al.*, 2013). Besides the genotypic distinctions between C and S strains of *Map*, phenotypic differences have been found in in vitro experiments, where infected macrophages exhibit different inflammatory responses depending on the type of isolate (Janagama *et al.*, 2006; Bormann

et al., 2011; Abendaño *et al.*, 2013). Variations in the peripheral immune response have also been reported after the infection of sheep with C and S strains of *Map* (Stewart *et al.*, 2004). Furthermore, in contrast to C-type isolates, the growth of S-type *Map* strains in culture media is slower and more fastidious (Juste *et al.*, 1991; Whittington *et al.*, 2011). The existence of pigmented isolates among S-type strains is also well documented (Taylor, 1951; Stevenson *et al.*, 2002).

Concerning the role of *Map* strains in the development of the different pathological responses, a previous study (Verna *et al.*, 2007) showed that S-type strains cause diffuse and more severe lesions than C strains in experimentally infected lambs. However, in that study, the ovine *Map* inoculum was an intestinal mucosa homogenate from a field case of paratuberculosis and no molecularly typed strains were employed. Furthermore, the presence of lesions was only assessed at 150 days post-infection (dpi).

The aim of this study was to evaluate the influence of the different strains of *Map* on the pathogenesis of paratuberculosis, through the evaluation of lesion development and peripheral immune responses in lambs experimentally infected with molecularly typed C and S strains obtained from pure cultures.

4.1.2. Materials and methods

Inocula preparation

The strains used for the challenge were the reference strain of *Map* K-10 (ATCC® BAA-968™) and three low passage field isolates maintained as glycerol stocks at -80 °C obtained from different species and samples. The latter strains represent the most widespread C and S genotypes found in

Spain as previously reported (Sevilla *et al.*, 2007). More detailed information on the strains is shown in Table 1.

Table 1. Origin of the strains used in the infection

Strain ID	Host	Breed	Isolated	Location	IS1311 PCR	<i>SnaBI-SpeI</i> PFGE
22G	Sheep	Latxa	intestinal	Gipuzkoa	S	69-50 Type III
Ovicap49	Sheep	Latxa	intestinal	Navarra	S	57-57 Type III
764	Cattle	Holstein	feces	Bizkaia	C	2-1 Type II
K-10	Cattle		feces	USA	C	1-1 Type II

All strains were propagated in Middlebrook 7H9 broth (Elguezabal *et al.*, 2011) supplemented with OADC (oleic acid, albumin, dextrose, catalase) enrichment (Becton Dickinson and Company, MD, USA), Tween 80 (Panreac Quimica SA, Barcelona, Spain), glycerol and mycobactin J (Allied Monitor, Inc., Fayette, MO, USA). After 4–5 weeks at 37 °C, cultures were harvested by centrifugation at 2800 × g for 15 min. Bacterial pellets were washed twice in phosphate buffered saline (PBS), resuspended in PBS and the presence of clumps minimized by making the liquid flow up and down through a fine needle (26G3/8) several times. Turbidity (McFarland units) of suspensions was measured using a Densimat (bioMérieux, Marcy l’Etoile, France). Expected cell concentration was estimated considering one McFarland unit as 10⁸ cells/mL according to a previous study (Hughes *et al.*, 2001) but taking into account that this equivalence could be one log lower as reported elsewhere (Elguezábal *et al.*, 2011). Suspensions were adjusted to 2 × 10⁹ cells/mL with PBS and each challenge whole-dose prepared using one mL of these suspensions as explained below.

Ten-fold serial dilutions were prepared and plated onto agar-solidified 7H9 with OADC, glycerol and mycobactin J in quadruplicate to assess the number of colony forming units (CFU) per mL in the inocula. Since bacteria were administered to animals in several aliquots and on separate days during 2 weeks, the unused aliquots of diluted inocula were kept at 4 °C until

required. In order to assess any potential loss of viability during this time, the plating procedure was repeated the last challenge day when all aliquots were administered. The material used to assess the potential reduction in CFU/mL numbers was a separate aliquot prepared and kept under the same conditions as those of the administered doses.

Experimental animals

A total of thirty 1.5-month-old lambs of the Assaf breed were used in this study. They were randomly selected from a flock in which no clinical cases of paratuberculosis had been reported in the last 5 years. Antibody ELISA and IFN- γ release test was performed in all the dams of the lambs, and all were negative to both assays. After a period of adaptation in the experimental facilities of the “Instituto de Ganadería de Montaña CSIC- ULE”, the lambs were allocated in separate pens and randomly divided into the following five groups, each composed of six lambs, according to the strain of *Map* inoculated: 22G and Ovicap49 sheep strains; 764 and K-10 cattle strains and a fifth group of uninfected control animals challenged with saline solution. All the animals followed a diet based on fed grass hay *ad libitum* and a conventional compound feed appropriate for each age.

Experimental design

The experimental procedures carried out in this study were performed in accordance with Spanish Royal Decree 1201/2005 for the protection of animals used for experimental and other scientific purposes, and were approved by the “Instituto de Ganadería de Montaña CSIC-ULE” Animal Ethics Committee.

Each experimentally infected lamb was orally inoculated using an automatic syringe with a total amount of 2×10^9 mycobacteria diluted in 40 mL of PBS that was divided into four doses of 10 mL, administered at 3-day

intervals. On day 150 after infection, two lambs from each group were humanely culled by the intravenous injection of a veterinary euthanasia drug (T61[®], Intervet, Salamanca, Spain), followed by exsanguination. The remaining animals were killed at 390 dpi.

Blood samples were collected from the jugular vein into 10 mL evacuated tubes (Venoject[®], Terumo Europe N.V., Leuven, Belgium) containing lithium heparin or without anticoagulant for IFN- γ and antibody (Ab) determination studies respectively. Blood samples were taken at monthly intervals from day 0 up to 390 dpi.

Cell mediated immune response determination Interferon- γ (IFN- γ) release assay (IGRA)

For the IFN- γ test, whole blood samples taken in heparinized tubes were used. They were always processed within 3 h from the time of collection. Two separate aliquots of 1.5 mL blood were mixed with either 100 μ L of sterile PBS (negative control) or an avian purified protein derivative (PPD) Ag (CZ Veterinaria, Porriño, Spain) at a final concentration of 30 μ g/ mL. Wholeblood cultures were incubated for 20 h at 37 $^{\circ}$ C in a humidified atmosphere. The tubes were then centrifuged and plasma supernatant was removed and frozen at -20° C until required. Plasma samples were then assayed in duplicate for the IFN- γ determination using a commercial immunoassay kit ("BOVIGAM[®]" Mycobacterium bovis Gamma Interferon Test Kit for cattle, Prionics AG, Switzerland) that has been widely used for testing ovine samples (Pérez *et al.*, 1999; Stewart *et al.*, 2004; Verna *et al.*, 2007; Delgado *et al.*, 2012), according to the manufacturer's instructions. For avoiding inter-plate variations, all the O.D. values were adjusted by dividing the sample O.D. minus the negative control O.D., from each plate. Once the raw values were standardized, the results were expressed as a quotient between the mean O.D. of the avian PPD stimulated plasma and the mean

O.D. of the sample plasma incubated with PBS. An animal was considered as positive when the quotient was higher than 2 (Pérez *et al.*, 199; Delgado *et al.*, 2012).

Single intradermal skin test (IDT)

One month before sampling (120 and 360 dpi), all the lambs were injected intradermally in the skin fold of the tail with 0.1 mL of avian PPD (CZ Veterinaria, Porriño, Spain) at a 0.5 mg/mL concentration. Skin-fold thickness was measured at the injection site with a calliper before injection and 72 h later. The results were expressed as the increase in millimeter of skin thickness. When used for diagnostic purposes, an animal was considered as positive when the increase in skin thickness was \geq than 2 mm (Pérez *et al.*, 1999).

Humoral immune response determination by indirect ELISA (Ab ELISA)

Blood samples without anticoagulant were allowed to clot and the serum was stored at -20 °C until required. The production of antibodies (Ab) against *Map* was determined by an indirect ELISA, using a protoplasmic antigen of *Map* (PPA-3; Allied Monitor Lab. Inc., Fayette, USA) and horseradish peroxidase conjugate protein G as a secondary Ab (Biorad, Hercules, USA). The technique was performed as previously described (Verna *et al.*, 2007). The absorbance values were measured spectrophotometrically at 450 nm using an ELX800 ELISA reader (Bio-Tek Instruments, Winooski, USA). The results were expressed as a quotient between the mean O.D. of each sample sera and the mean O.D. of the positive control serum in each plate. An animal is considered positive when this quotient is higher than 0.9 (Pérez *et al.*, 1997).

Pathological studies

Complete necropsies were performed in all the animals. Gross examination was carried out, with special attention to the gut and related lymph nodes. Samples from the ileocecal valve (ICV), ileum (IL) (three 5-cm samples, taken 20, 40 and 60 cm from the ileocecal valve), jejunum (JJ) and jejunal Peyer's patches (JPP) (at least 3 patches from each of the proximal, medium and distal zones), the caudal mesenteric lymph node (MLN), one jejunal lymph node (JLN) and ileocecal lymph nodes (ICLN) were taken for histopathological examination. All the tissues were fixed in 10% neutral buffered formalin, dehydrated through a graded alcohol series before being embedded in paraffin wax. Sections 4 µm thick were stained with haematoxylin and eosin (HE), Masson's Trichrome to stain connective tissue and by the Ziehl-Neelsen (ZN) technique for acid-fast bacilli (AFB) detection.

Representative granulomatous lesions found in lambs from all the experimental groups were assessed immunohistochemically for the presence of *Map* or its antigens, using an EnVision + HRP visualization kit (Dako North America, Carpinteria, USA). The sections were incubated with a specific rabbit anti-*Map* serum at a dilution of 1/9000, as described elsewhere Delgado *et al.*, 2013). All the lesions consistent with *Map* infection observed in the digestive tract were classified following the guidelines previously proposed (Pérez *et al.*, 1996; Verna *et al.*, 2007) for paratuberculosis lesions in the ovine species, according to the presence and location of granulomas in the different intestinal lymphoid tissue compartments.

After the conventional histopathological examination, the number of granulomas per tissue section was quantified in the following samples: ICV, 3 samples of the IL, JJ and JPP (proximal, middle and distal), MLN, JLN and ICLN. Three tissue sections were randomly selected from each intestinal site and 2 tissue sections from each lymph node, so that a total of 30 intestinal and 6

lymph node tissue sections were analysed from each animal. Sections were assessed blind and the mean number of granulomas per tissue section in each site was recorded by the same observer (MF), distinguishing those granulomas located in the lymphoid tissue from those in the associated lamina propria (LP) or in the mucosa not related to lymphoid tissue.

Nested PCR

The detection of *Map* DNA was assessed using a nested PCR method that was performed from paraffin-embedded tissues. In total, 10 µm of ICV, middle JPP and JLN tissue sections adjacent to those used for the ZN and immunohistochemical studies were cut twice, and DNA was isolated using Speedtools Tissue DNA extraction kit according to the manufacturer's instructions (Biotools® B&M Labs., Madrid, Spain). The nested PCR was carried out as previously described (Delgado *et al.*, 2012) using primers to detect the presence of *Map*-specific IS900 DNA.

Statistical analysis

Data on IFN- γ and Ab production as well as on granuloma count were subjected to analysis of variance using the general linear model procedure (GLM) of the SAS statistical package (version 9.1; SAS Institute, Cary, NC, USA) for the evaluation of treatment, time of killing and lesion location main effects and interactions. The results of the O.D. indexes obtained in the IGRA, Ab ELISA tests and the tissue granuloma count figures were logarithmically transformed to submit them to normal distribution-based tests of significance. Thus, differences among the experimental groups at each time of sampling or killing were evaluated using the Student's t-test for pair-wise comparisons with the Tukey-Kramer correction for multiple comparisons, at the 95% significance level. The results of the IDT among the experimental

groups at 120 and 360 dpi, and the PCR-positive frequencies were compared and tested for significance by chi-squared analysis.

4.1.3. Results

One animal from the K-10 group died at 30 dpi, during the course of the experiment from causes unrelated to Johne's disease (bacterial pneumonia) and was excluded from this study.

Assessment of the colony forming units (CFU)

The number of CFU obtained after the culture of the first and fourth (shown in Figure 1) aliquots of the different inocula gave similar results. As shown in Figure 1, the difference between the expected number of cells/mL as assessed by McFarland readings and CFU/mL counts as assessed by plating serial dilutions of inocula was lower than one logarithm in all cases except for the Ovicap49 strain. In this case the mean value for CFU/mL counts was only 3×10^7 (standard deviation = 1.41×10^7).

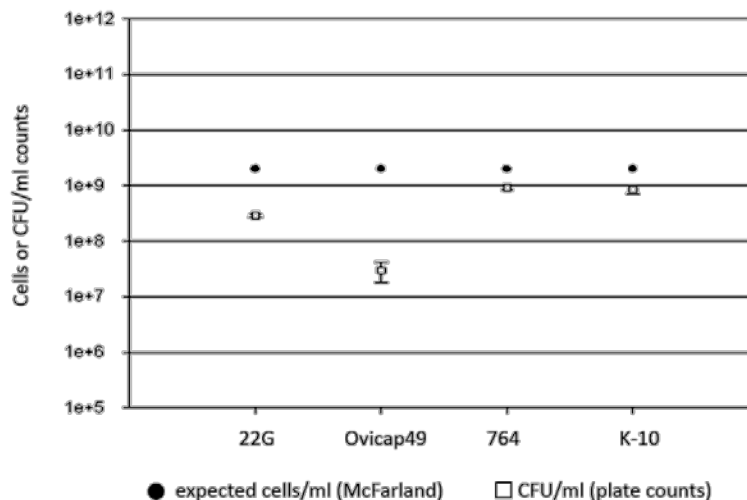


Figure 1. Assessment of the bacterial load of the inocula. Differences between the bacterial load of inocula used for the challenge of animals as assessed by optical density (McFarland) and CFU counts (plate colony counting).

IFN- γ test (IGRA)

Figure 2 shows the IFN- γ production in the different experimental groups. No significant differences were observed between the groups infected with an S-type strain and the control group, although sporadically some of the infected lambs showed an index value considered as positive (> 2). However, in both experimental groups challenged with the C-type strains, the IFN- γ production was significantly higher than in the control or S strains infected groups ($P < 0.05$) between 120 and 330 dpi. The highest values were mainly reached between 240 and 330 dpi, with significant differences ($P < 0.05$) between 764 and K-10 groups. At 120 dpi (Figure 2), both C-type strain-infected groups showed the earliest significant increase that was also higher in the 764 group ($P < 0.05$).

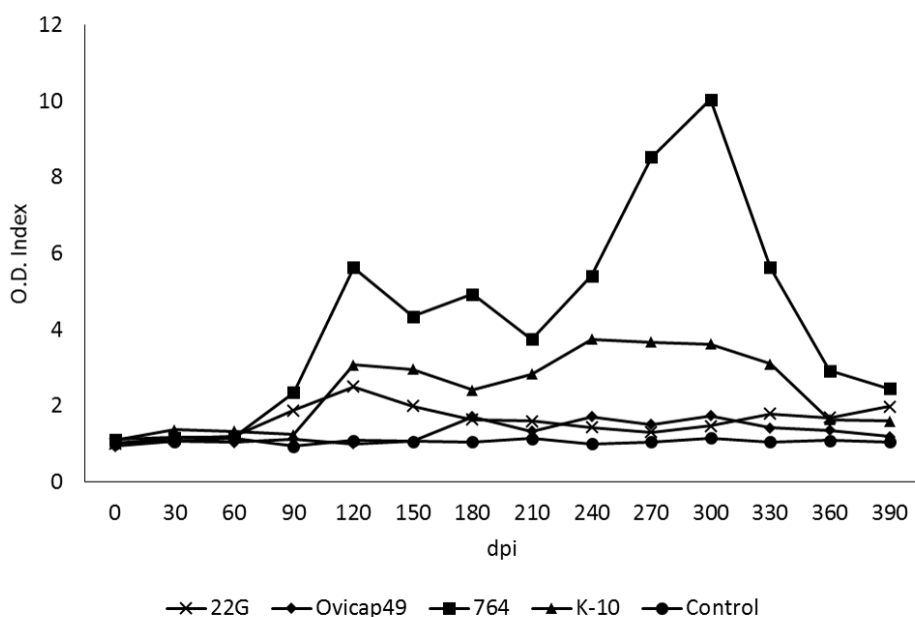


Figure 2. Kinetics of the specific IFN- γ release by whole blood stimulated with avian PPD in the five experimental groups. The results are expressed as an index obtained after dividing the mean O.D. of each sample stimulated with avian PPD by the mean O.D. of the same sample incubated with PBS. From 0 to 150 dpi, each group was formed by 6 lambs, while from 180 to 390 dpi they were composed of 4 animals (except group K-10, formed by 5 and 3 respectively). dpi: days post infection.

Intradermal skin test (IDT)

All the infected groups showed a significant increase in skin thickness ($P < 0.05$) compared to the control group, both at 120 and 360 dpi (Figure 3), except for lambs infected with the 22G strain at 360 dpi. No significant differences in this response were detected among the different groups either at 120 or 350 dpi.

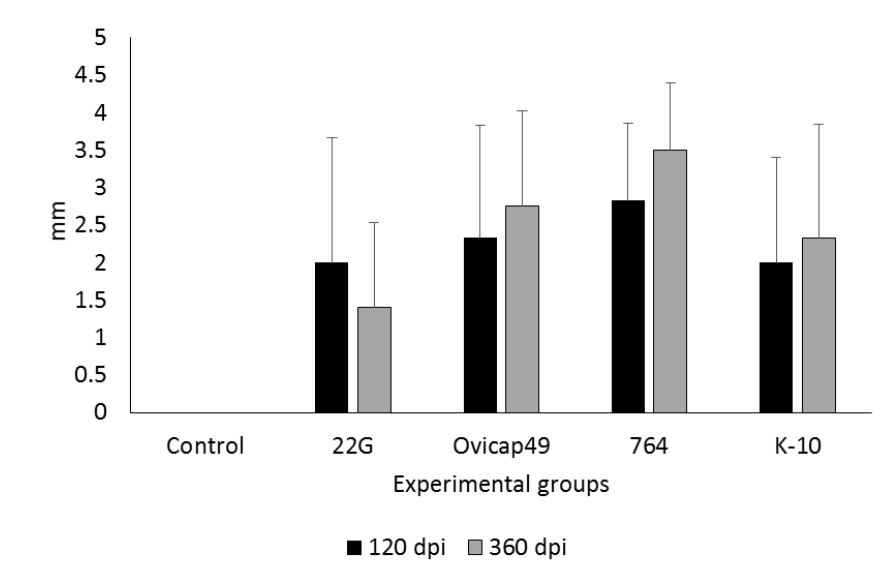


Figure 3. Response to the intradermal skin test (IDT). The results are expressed as the skin-fold thickness increase (in mm) after intradermal injection of avian PPD, at 120 and 360 dpi in the five experimental groups. Error bars: standard deviation.

Indirect ELISA

The Ab production in the different experimental groups throughout the experiment is shown in Figure 4. No significant differences were observed between the groups, except for a significant increase ($P < 0.05$) between 210 and 330 dpi in the Ab levels of the animals from the 764 group.

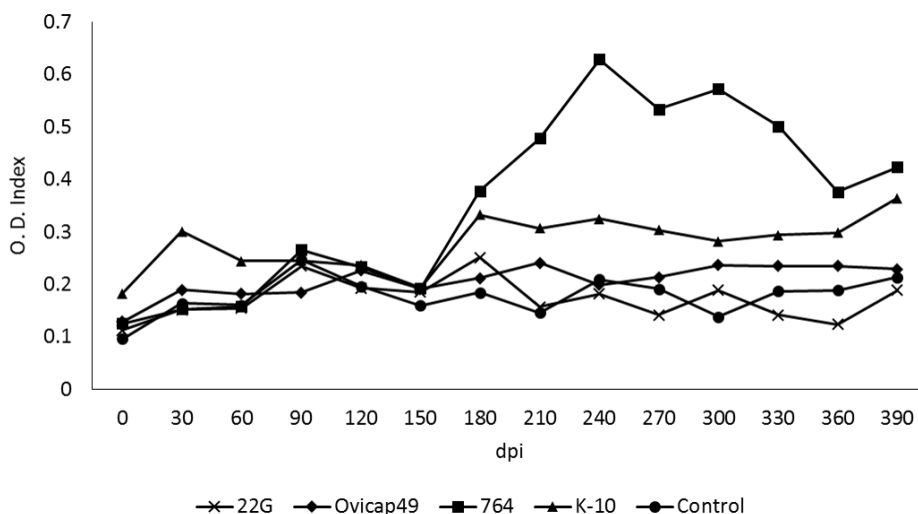


Figure 4. Kinetics of the antibody production of the five experimental groups, assessed by indirect ELISA. The results are expressed as an index obtained after dividing the mean O.D. of each sample by the mean O.D. of the positive control from each plate. From 0 to 150 dpi, each group was formed by 6 lambs, while from 180 to 390 dpi they were composed of 4 animals (except group K-10, formed by 5 and 3 respectively). dpi: days post infection.

Pathological findings

Gross lesions

In the two lambs euthanized at 150 dpi from group 764, one and two areas of thickening of the intestinal mucosa, between 1– 2.5 cm long, were observed respectively in the middle part of the jejunum (Figure 5a). No other gross changes related to paratuberculosis were seen in any of the rest of the lambs regardless of the time of sampling.

Microscopic lesions

Granulomatous lesions consistent with *Map* infection were found in the tissue sections from all infected lambs euthanized at 150 dpi, regardless of the group, and in all but three animals (one from 22G, Ovicap49 and K-10 group each respectively) examined at 390 dpi. However, the type of lesion varied between the S and C-type *Map* strain infected groups. To categorize

each animal, the final classification was always based on its more severe intestinal granulomatous lesion (Table 2).

Lambs from S strain infected groups (both 22G and Ovicap49) showed lesions that were categorized as focal. They were formed by small, well-defined granulomas composed of groups of 20–50 macrophages with a large pale cytoplasm and large nuclei with a few lymphocytes scattered among them (Figure 5b). These granulomas were found exclusively in the interfollicular area of the intestinal lymphoid tissue, either in the ileocecal valve or the jejunal Peyer's patches (Figure 5b). The presence of these granulomas, due to their small size, did not alter the normal structure of the Peyer's patches. These focal lesions appeared in the four lambs euthanized at 150 dpi, and in 6 out of the 8 (75%) lambs analysed at 390 dpi. The remaining two animals (one from each experimental group) did not show lesions related to *Map* infection.

Differences in the lesion type between the groups infected with the S and C strains were observed. At 150 dpi, among lambs from the K-10 group, one animal had lesions categorized as multifocal a, composed of more numerous granulomas than those seen in the focal forms. In addition to the granulomas present in the interfollicular areas of the Peyer's patches, small and well-defined granulomatous lesions were also detected in the lamina propria (LP) related to the intestinal lymphoid tissue. The morphology of the villi was not substantially modified. In the remaining lamb from the K-10 group, the lesion was classified as multifocal b. In that animal, granulomatous changes were more severe in the lymphoid tissue and related LP (Figure 5c), but were also extended to the LP not associated with the lymphoid tissue. At this location, granulomas were seen between the intestinal glands and caused a focal thickening of the LP, without a clear disruption of the normal structure.

In both lambs from group 764 culled at 150 dpi, lesions were classified as diffuse. They were composed of large numbers of granulomas that coalesced and invaded the complete structure of the Peyer's patches, causing a clear modification of their normal architecture. Poorly demarcated granulomatous lesions were also found in the LP related and non-related to the lymphoid tissue (Figure 5d). In areas of the jejunum, the intestinal mucosa was markedly thickened due to the presence of granulomas surrounded by a large number of lymphocytes (Figure 5d). The presence of this infiltrate caused the enlargement and fusion of the intestinal villi and the separation of the intestinal glands. Occasionally cell debris was observed in the lumen of the glands (Figure 5c, d).

A constant feature in both groups of lambs infected with the C-type strains, in contrast to those infected with the S strains, regardless of the lesion type, was the occasional finding of multinucleated Langhans giant cells among the cells forming the granulomas, and the sporadic presence of central areas of caseous necrosis exclusively in some of the granulomas located in the lymphoid tissue, especially in the largest ones.

Among the three lambs from the K-10 group euthanized at 390 dpi, one of them had focal lesions, another had a multifocal a type lesion and there were no lesions in the last. In lambs from group 764, no diffuse lesions were observed at 390 dpi, in contrast to the pathological findings at 150 dpi. One animal had a multifocal b lesion, two had multifocal a lesions (Figure 5e), and a focal form was detected in the remaining lamb. The morphological features of the granulomatous lesions found at 390 dpi among the animals infected with the C-type strains, regardless of the group, differed from those observed at 150 dpi. In the former, all the granulomas, both those located in the lymphoid tissue area and in the LP (related or unrelated to the lymphoid tissue) were significantly smaller, round and very well-demarcated from the

adjacent tissue by a fibrous tissue capsule than those found at 150 dpi (Figure 5e). When the sections stained with Masson's trichrome were examined, a marked amount of collagen fibres was seen among the macrophages, lymphocytes and Langhans giant cells that formed the granulomas, regardless of their location in the intestine (Figure 5f). Very occasionally, granulomas found in the lymphoid tissue in the lamb from group 764 with a multifocal b lesion, showed a necrotic centre with dystrophic mineralization.

Besides the intestine, granulomatous lesions were also found in the lymph nodes, mainly in the MLN and JLN. In lambs from K-10 and 764 groups showing the more severe intestinal lesions (multifocal b and diffuse), a diffuse granulomatous lymphadenitis was observed. It was composed of a granulomatous infiltrate, similar to that seen in the intestine, formed by macrophages and some Langhans giant cells, that was spread throughout the interfollicular and paracortical areas, with a multifocal distribution. In a number of occasions, always corresponding to the animals with diffuse lesions, these granulomas coalesced and invaded the adjacent lymphoid follicles, causing a marked distortion in the morphology and enlargement on the lymph node. A necrotic centre, occasionally with mineralization, was also seen in some granulomas. On the contrary, the lambs with focal or multifocal a lesions in the intestine from any of the four experimental groups, showed a focal granulomatous lymphadenitis characterized by one or two small granulomas composed of less than 10 macrophages (rarely small multinucleated cells were detected in lambs from groups K-10 and 764), located in the interfollicular part of the cortical area of the ICLN, MLN or JLN.

No AFB or *Map* antigens were detected in any of the control lambs or in all the lesions classified as focal or multifocal a, regardless of the experimental group. Only in animals with multifocal b or diffuse lesions were solitary or few AFB detected both by ZN and immunohistochemistry, only in

the granulomas located in the LP. In the lymph nodes, occasional AFB were observed in samples of lambs with intestinal diffuse lesions.

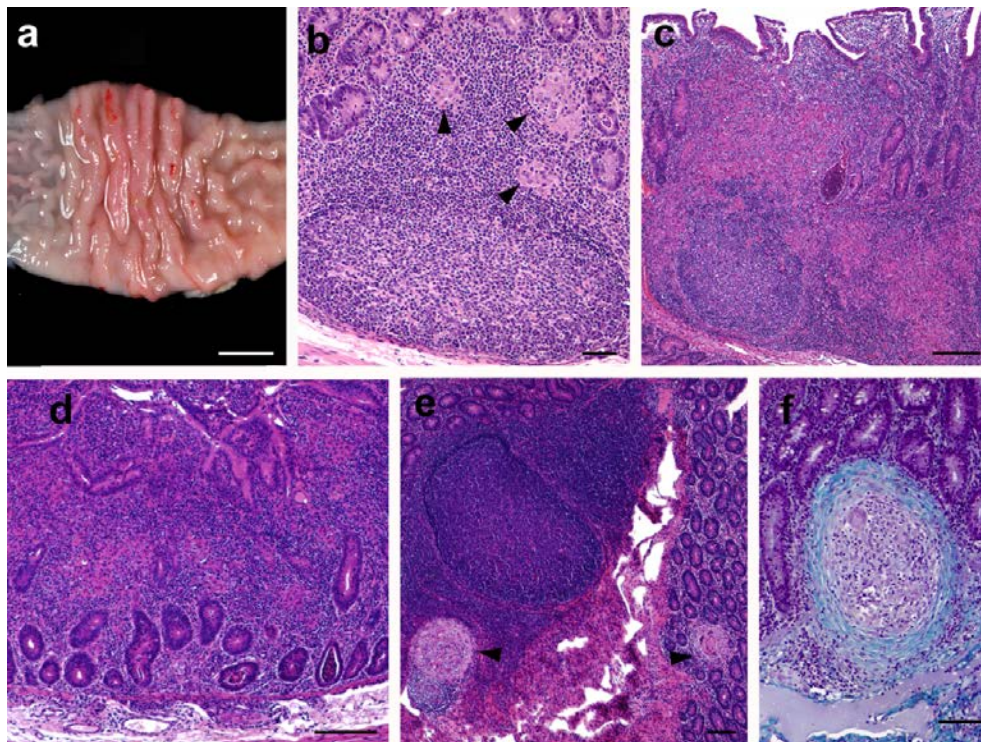


Figure 5. Pathological findings in the experimentally infected lambs. (a) Focal thickening of the jejunal mucosa in a lamb from the 764 group euthanized at 150 dpi. Bar = 1 cm. (b) *Focal* lesion composed of a group of macrophages (arrowheads) seen in the interfollicular area of the JPP, observed in a lamb from group Ovicap49 culled at 390 dpi. HE. Bar = 50 μ m. (c) Severe granulomatous infiltrate invading and modifying the lymphoid tissue architecture, that is also present in the related LP. JPP. Lamb from K-10 group with a *multifocal b* lesion, culled at 150 dpi. HE. Bar = 500 μ m. (d) *Diffuse* lesion characterized by the thickening of the jejunal lamina propria with enlargement of the intestinal villi due to the presence of an infiltrate formed by several poorly-defined granulomas surrounded by numerous lymphocytes. Jejunum. Lamb from 764 group euthanized at 150 dpi. HE. Bar = 350 μ m. (e) Two small and very well- demarcated granulomas (arrowheads) present in the lymphoid tissue and adjacent lamina propria (*multifocal a* lesion) that do not significantly alter intestinal morphology. JPP. Animal from 764 group culled at 390 dpi. HE. Bar = 200 μ m. (f) Detail of a “regressive” type granuloma, with a thick fibrous capsule surrounding the macrophages and giant cells, seen in the jejunal lamina propria in a lamb from 764 group culled at 390 dpi. Masson’s Trichrome. Bar = 70 μ m.

Granuloma count

Table 3 shows the mean of the total granuloma counts per animal, corresponding to the different experimental groups and the time of euthanasia. Differences in the lesion severity, with variations among individuals of the same group, were observed. Significant reduction in the number of granulomas ($P < 0.001$) was noticed between animals euthanized at 150 and 390 dpi in both groups infected with C-type strains whereas no differences were found in animals infected with the S-type strains either between 22G and Ovicap49 groups or the time of sampling. Moreover, animals from the 764 group had a higher amount of granulomatous lesions, both at 150 and 390 dpi ($P < 0.001$) than lambs from the K-10 group.

Figure 6 shows the mean granuloma counts corresponding to the different intestinal compartments examined in lambs from K-10 and 764 groups at 150 and 390 dpi. A reduction in the number of granulomas present in the lymphoid tissue and related LP between 150 and 390 dpi ($P < 0.05$) was observed in both groups. It is worth highlighting the marked decrease in the number of granulomas located in the LP not associated with the lymphoid tissue in the 764 group ($P < 0.001$), in agreement with the previously described types of lesion. In the groups infected with the S-type strains, all the granulomas appeared exclusively in the intestinal lymphoid tissue, with no differences between groups or time of sampling (Table 3).

The distribution of the lesions in each intestinal location examined in the different experimental groups is shown in Figure 7. In the groups infected with S-type strains (Figure 7a), lesions were found exclusively in the ICV and the different JPP. It is noteworthy that IL samples were always negative, even though lymphoid tissue was present in all the sections examined. Although granulomas appear to be slightly more numerous in the JPP samples than in the ICV in both groups (Figure 7), differences were not statistically significant.

In contrast, in the groups infected with C-type strains (Figure 7b) granulomas were appreciated in all the samples with lymphoid tissue (ICV, IL and JPP). Although the number of granulomas seemed to be higher in the JPP than in the other regions, differences were only statistically significant ($P < 0.05$) in animals from group K-10. When comparing both groups, granuloma counts were higher in all the locations in the 764 than in the K-10 group, remarkably in the ICV, IL and JJ samples ($P < 0.001$).

In addition to the intestine, granulomas were also noted in the associated lymph nodes. They were always more numerous in animals infected with the C- rather than the S-type strains ($P < 0.05$). When considering the different groups, no differences were found between the S strain challenged groups, but granulomas were more numerous in the 764 than in the K-10 group ($P < 0.05$).

In accordance with the results of the intestine, a significant decrease was also appreciated in the granuloma counts between 150 and 390 dpi ($P < 0.05$) in animals from both groups infected with the C-type strains. Granulomas were counted more frequently in the JLN than in the other lymph nodes in all the groups.

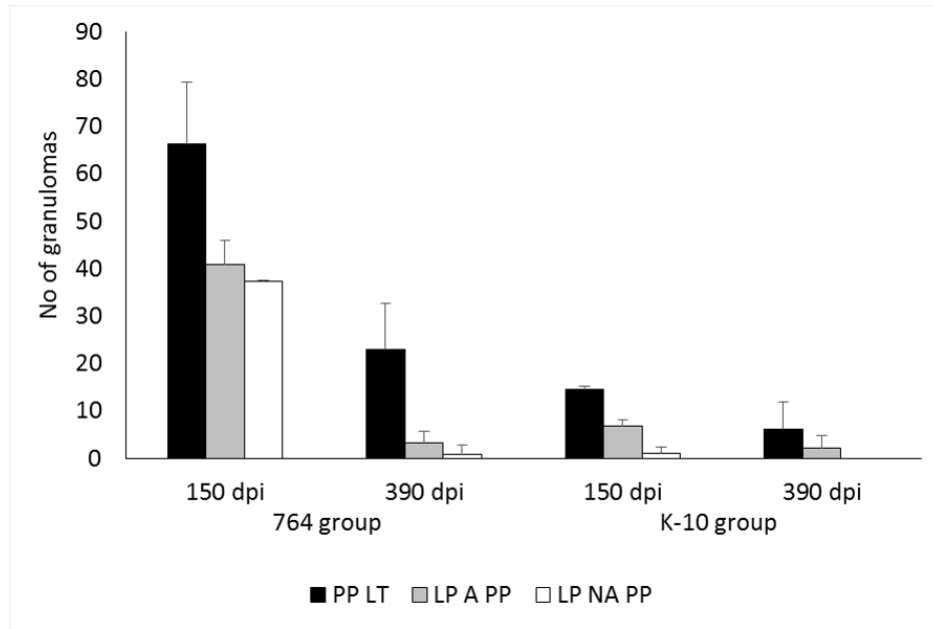
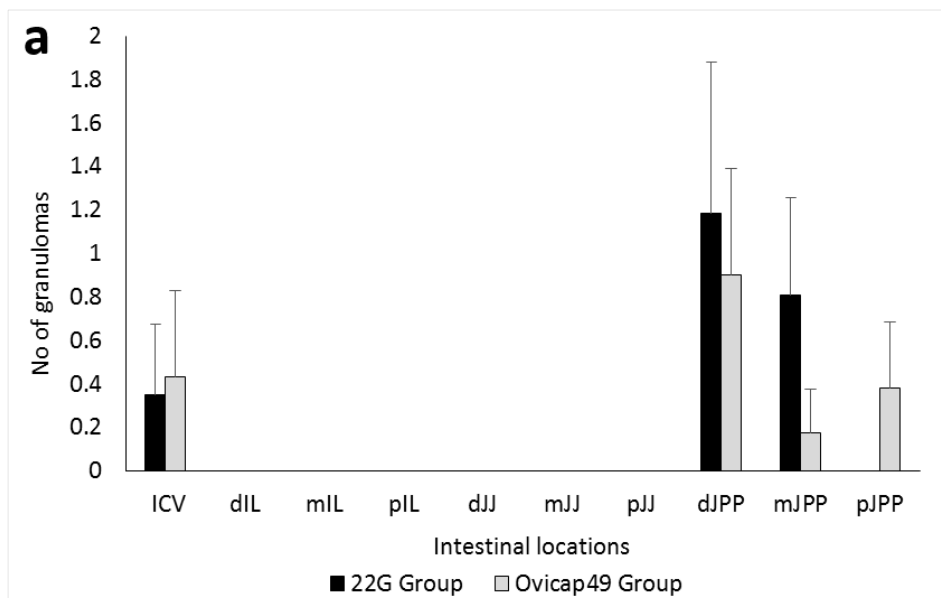


Figure 6. Granuloma counts from the C-type strains infected lambs in the different intestinal compartments. Count of granulomas from the tissues of the C-type strains infected groups (764 and K-10) culled at 150 and 390 dpi. Mean number of the granulomas per animal, corresponding to their location in the different intestinal compartments. dpi: days post infection. Error bars: standard deviation. PP LT: Peyer’s patches lymphoid tissue. LP A PP: lamina propria associated with Peyer’s patches. LP NA PP: lamina propria not associated with Peyer’s patches.



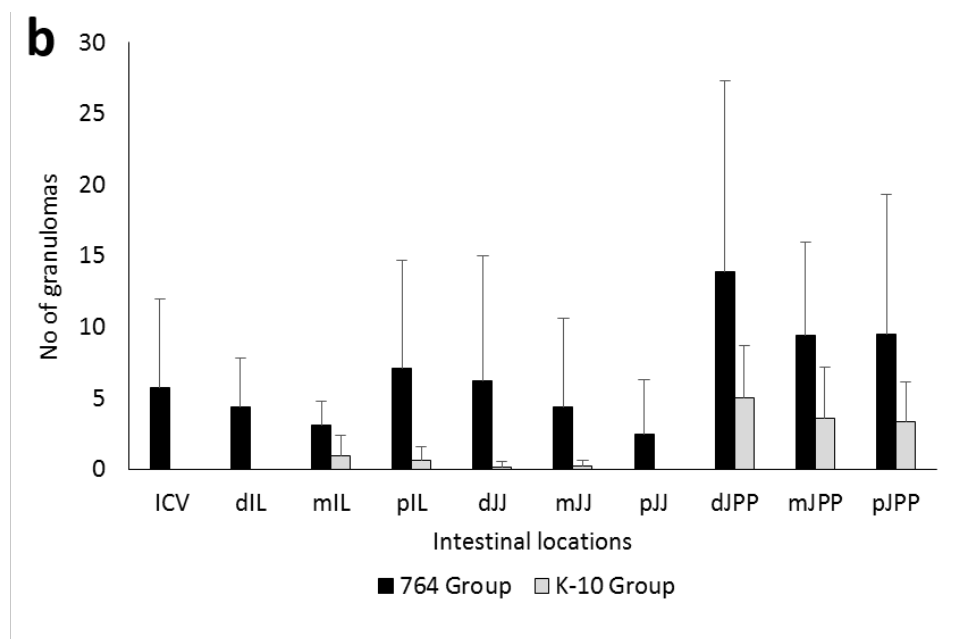


Figure 7. Granuloma counts according to their intestinal location. Total granuloma count from the tissues of the S (a) and C (b) strains infected groups, regardless of the time of sampling. Mean of the total number of granulomas per tissue section and animal, according to their intestinal location. ICV, ileocecal valve; IL, ileum; JJ, jejunum; JPP, jejunal Peyer's patches. d, distal; m, medium; p, proximal. Error bars: standard deviation.

Nested PCR

IS900 *Map*-specific sequence was demonstrated by nested PCR in all 12 lambs infected with the S-type strains including animals with no lesions, from at least 1 of the 3 analysed tissue sections (Table 2). No significant differences in the positivity detected among the examined locations were observed. One lamb euthanized at 390 dpi from the K-10 group, which was categorized as having no lesions, was negative to the presence of *Map* DNA (Table 2). The other animals infected with C-type strains were positive from at least 1 tissue section examined. As in the rest of the groups, no statistical differences were seen in the positivity rates among the locations analysed. All tissue sections from the uninfected control lambs were negative using PCR.

Table 2. Distribution of experimental animals in the infected groups according to their lesion type and the results of the nested-PCR

Group	Sampling	Animal ID	Lesion	Nested PCR results		
				ICV	mJJP	JLN
S-type strains						
22-G	150 dpi	1	Focal	+	+	+
		2	Focal	+	+	+
	390 dpi	3	Focal	+	+	+
		4	Focal	+	+	-
		5	Focal	+	+	+
		6	No lesion	-	+	-
Ovicap 49	150 dpi	7	Focal	+	+	+
		8	Focal	+	+	-
	390 dpi	9	Focal	+	+	+
		10	No lesion	+	-	-
		11	Focal	-	+	-
		12	Focal	+	-	-
C-type strains						
764	150 dpi	13	Diffuse	+	+	+
		14	Diffuse	+	+	+
	390 dpi	15	Multifocal a	+	+	+
		16	Multifocal a	+	+	+
		17	Focal	-	+	-
		18	Multifocal b	+	+	+
K-10	150 dpi	19	Multifocal b	+	+	+
		20	Multifocal a	+	+	+
	390 dpi	21	No lesion	-	-	-
		22	Multifocal a	+	+	+
		23	Focal	-	+	+

Table 3. Total granuloma counts per animal. Granuloma counts from the tissues of lambs infected with the S and C strains and euthanised at 150 and 390 dpi. Mean number of granulomas per animal \pm standard deviation.

	150 dpi	390 dpi
S-type		
22G	2.705 \pm 0.86	2.16 \pm 1.57
Ovicap49	2.42 \pm 1.04	1.63 \pm 1.75
C-type		
764	144.355 \pm 38.4	27.122 \pm
K-10	22.305 \pm 2.18	8.21 \pm 12.4

4.1.4. Discussion

The results of this study show that sheep can become experimentally infected with either C or S-type strains of *Map*, as previously documented (Stewart *et al.*, 2004; Verna *et al.*, 2007), but clear differences in the immune response and especially in the lesion development occur in relation with the type of strain.

Variations in the morphology of the granulomatous lesions due to different *Map* isolates were previously reported (Verna *et al.*, 2007), where infection with C-type strains caused the appearance of a larger number of giant cells and central caseous necrosis in lambs examined at 150 dpi, which was demonstrated in the current study. These findings are closer to the lesions described in natural bovine paratuberculosis (González *et al.*, 2005) than those seen more frequently in sheep, where giant cells are not a very characteristic hallmark (Pérez *et al.*, 1996; Clarke, 1997). Considering that our study and that of Verna *et al.* (2007) used different C-type strains, with similar pathological findings, it seems feasible to conclude that C strains rather than host species are the cause of some of the pathological characteristics of *Map* infection.

Some of the lambs infected with C-type strains, at 150 dpi showed diffuse lesions affecting wide areas of intestinal mucosa not associated with the lymphoid tissue, which has been regarded as related to more advanced stages of *Map* infection (Nisbet *et al.*, 1962; Pérez *et al.*, 1996; González *et al.*, 2005; Verna *et al.*, 2007; Delgado *et al.*, 2012; Delgado *et al.*, 2013). According to the pathological findings at 390 dpi, lesions induced by C strains in sheep showed an evolution towards resolution, with a marked decrease in their severity, characterized by lower numbers of smaller, well-encapsulated and fibrotic granulomas. Although Verna *et al.* (2007) noted some degree of fibrosis in some lesions induced by C-type strains, their study ended at 150

dpi and moreover, lesion severity was not assessed. Granulomas showing fibrosis could be considered as “regressive” type lesions, as similar histological features have been described in lambs vaccinated and experimentally infected with *Map* (Nisbet *et al.*, 1962; Juste *et al.*, 1994; Gwozdz *et al.*, 2000), where they have been associated with a regression of the infection in immunized animals, or in minipigs infected with *Mycobacterium tuberculosis* in the lung (Gil *et al.*, 2010), related to a contention of the infection. This finding would suggest that in lambs infected with C-type strains, if the experimental infection had been prolonged for a longer period, infection could have been contained or even regress, with resolution of lesions and recovery of tissue morphology. The fact that one lamb from the K-10 group that showed a specific cellular immune response did not show any lesion and was negative for *Map* DNA identification in the tissues sampled at 390 dpi, further supports this hypothesis.

In paratuberculosis vaccinated animals, the efficacy of the vaccine in controlling the progression of the infection has been associated with the induction of a protective and vigorous cellular immune response (Gwozdz *et al.*, 2000; Begg and Griffin, 2005). In this study, the intense IFN- γ production seen in C-type strains infected lambs could be related to the regression of the lesions. In a previous experiment, S-type *Map* isolates also proved to be less pathogenic and induced a weaker cell-mediated immune response compared with a C strain, when infecting sheep (Stewart *et al.*, 2004), but a pathological evaluation of the lesions was not assessed. Thus, from our results, it can be hypothesized that infection induced by C-type strains could have reached its highest development around 150 dpi, but infected lambs were able to mount a more efficient and specialized immunologic response that would have caused a regression of the lesions. A similar mechanism has been proposed to occur in adult ewes or cows infected with *Map* showing a higher resistance to infection (Payne and Rankin, 1961; Delgado *et al.*, 2012; Delgado *et al.*, 2013).

It might have been interesting to have followed these animals over a more uniform and longer timescale such as culling every two months after infection for a longer period.

On the contrary, lambs infected with S-type strains only showed focal granulomatous lesions, restricted to the lymphoid tissue, and not associated with a detectable peripheral immune response. This type of lesion has been described in experimental paratuberculosis in sheep (Nisbet *et al.*, 1962; Juste *et al.*, 1994; Begg *et al.*, 2010; Delgado *et al.*, 2013) and also in adult animals in natural cases, raising the hypothesis that they could be considered as latent lesions present in adult animals infected earlier in life or as initial lesions of recently infected adult individuals (Pérez *et al.*, 1996). Our results, showing the presence of similar focal granulomatous lesions at 150 dpi and 390 dpi in the infected animals that did not appear in the control lambs, would further support the hypothesis of the latent character of the focal lesions.

In natural or experimental cases, the majority of sheep with focal lesions show a marked peripheral cellular immune response (Pérez *et al.*, 1999; Delgado *et al.*, 2012). However, in our study, only some lambs were sporadically positive to IGRA, with no statistical differences when compared with the control animals when taking the overall results, even though a specific but weak cellular immune response was detected by IDT. This finding would indicate that IDT may be more sensitive than IGRA, as has been previously reported (Pérez *et al.*, 1999; Dunn *et al.*, 2005). However, this is not in agreement with the results obtained in the groups infected with C-type strains, where the IDT response was similar to the S groups but accompanied by a higher IFN- γ response. From these results, it can be hypothesized that there are differences in the immune response induced by both types of

strains, as has been demonstrated in several in vitro studies (Juste *et al.*, 1991; Abendaño *et al.*, 2013).

Moreover, the hypothesis that IDT and IGRA would measure different factors operating in the specific cell mediated immune response against *Map* should be considered and further investigated. The possibility that these animals with focal forms have not mounted a persistent and measurable peripheral specific production of IFN- γ should also be considered, in the light of the work of Vazquez *et al.* (2013), where they found a large proportion of cattle with focal lesions negative to IGRA. In the present study, lambs infected with S-type strains would fit the recently proposed pathogenesis model of *Map* infection (Vázquez *et al.*, 2013) that considers focal lesions as a condition of certain natural resistance or premonition sustained by the presence of a continuous confined inflammatory focus. Furthermore, our results from the peripheral immune responses in the whole experiment, did not support the standard model of immunity to paratuberculosis in which in the early stages of the disease peripheral IFN- γ release is the main response, while it decreases in the more advanced forms where humoral responses predominate (Stabel, 2000; Whittington *et al.*, 2012). Our results in the lambs infected with C-type strains show a mixed cellular and humoral response from 120 to 330 dpi, probably in coincidence with the highest severity of the inflammatory response, while in the lambs challenged with S-type strains, there were minimal inflammatory lesions, and no IFN- γ production was observed. This finding would coincide with recent studies (Stewart *et al.*, 2004; Begg *et al.*, 2010; Vázquez *et al.*, 2013) that question the Th1 dominance in the early stages of *Map* infection.

Recent work carried out after the in vitro infection of bovine macrophages with different *Map* strains have shown different patterns of cytokine expression: while C-type strains have a high rate of survival inside

the cells related to an anti-inflammatory response characterized by an up-regulation of IL-10, S-type strains showed a lower persistence with a significantly up-regulated proinflammatory response (Janagama *et al.*, 2006; Abendaño *et al.*, 2013). These findings indicate that the survival of the *Map* strains within bovine macrophages is strongly associated with the specific host from which the isolates were initially isolated (Abendaño *et al.*, 2013). A similar mechanism could operate at the level of the intestinal macrophages after *Map* infection, suggesting that the local immune responses occurring at the intestinal lymphoid tissue level should play an important role in *Map* pathogenesis. This deserves to be further investigated in the lambs from this study. In this sense, previous studies (Begara-McGorum *et al.*, 1998; Gillan *et al.*, 2010) have shown the importance of the immune response mounted in the Peyer's patches in the early stages of paratuberculosis and its lack of correspondence with the peripheral immune response.

In contrast to other experimental infections carried out by our group in lambs using S-type strains (Verna *et al.*, 2007; Delgado *et al.*, 2013), none of the lambs of this study showed widespread lesions, that in previous studies were seen as soon as 120–150 dpi. It could be postulated that the use of low passage, pure culture of *Map* inocula in this experiment instead of an intestinal mucosal homogenate from a naturally affected sheep, as in the other studies, could explain this. *Map* infections are more easily and rapidly established when the challenge inoculum was prepared from gut mucosal tissue than from cultured bacteria (Stewart *et al.*, 2004; Begg and Whittington, 2008). Our results possibly mimic what occurs in natural conditions, where a great majority of infected animals show focal and latent lesions (Pérez *et al.*, 1996; Vázquez *et al.*, 2013) similar to those found in our study. Further supporting this finding, in the experiment carried out by Begg *et al.* (2010) infecting larger groups of lambs with a cultured S strain, animals with widespread lesions only appeared in some lambs examined 10–19

months after the infection. Thus, it seems feasible that, should the length of the experimental infection had been prolonged, lesions could have progressed towards more severe forms in some of the lambs infected with the *S Map* strains. On the contrary, the possibility that the S-type strains used had a lower pathogenicity than those used in previous studies cannot be discounted. The existence of variations in pathogenicity among the different strains of *Map* has already been reported (Taylor, 1951; Verna *et al.*, 2007; Begg and Whittington, 2008) and has been confirmed among the C strains in this study, where the 764 isolate induced more intense immune and pathological responses than the K-10 strain. The fact that the latter is a *Map* reference strain with a high number of culture passages could have contributed to its lower pathogenicity (Begg and Whittington, 2008). However, no differences were observed between the two S strains employed; both were low passage cultures, isolated from clinical cases of ovine paratuberculosis. Although traditionally ovine pigmented strains have been considered as having a higher pathogenicity (Taylor, 1951; Stamp and Watt, 1954), this fact is not supported by our results.

Differences in the pathogenicity have also been associated with the dose administered to the experimental animals (Nisbet *et al.*, 1962; Delgado *et al.*, 2013). In our study, the dose employed is comparable to those used in other studies (Stewart *et al.*, 2004; Verna *et al.*, 2007; Begg *et al.*, 2010; Delgado *et al.*, 2013) and has been shown to cause the infection. A good correlation was observed between the expected number of bacteria assessed by the McFarland method and the CFU counts evaluated by plating serial dilutions, as previously stated (Hughes *et al.*, 2001), except for the pigmented strain Ovicap49. Such an unexpected difference between optical density and viable cell count could be explained by the enormous difficulty in culturing this concrete ovine pigmented strain, especially on the surface of solid media, rather than by an actual reduction in the number of viable units.

This study has also shown the importance of the intestinal lymphoid tissue in the establishment of paratuberculosis infection, regardless of the strain used, since most of the granulomatous lesions appeared in this tissue, as was previously observed (Nisbet *et al.*, 1962; Juste *et al.*, 1994; Pérez *et al.*, 1996; Verna *et al.*, 2007; Delgado *et al.*, 2013), further confirming the role of the Peyer's patches both as a primary portal of entry of *Map* in the organism and in the persistence for longer periods of time of focal granulomatous lesions representing forms of latency or resistance.

Regarding the distribution of the lesions along the different intestinal sites and their intensity, the granuloma count showed a marked variation between the individuals and the different sections of the intestine, as has previously been reported as a typical feature of natural and experimental paratuberculosis (Payne and Rankin, 1961; Nisbet *et al.*, 1962; Begg and Whittington, 2008; Delgado *et al.*, 2013). In all the experimental groups, JPP has been the region harbouring the highest amount of lesions followed by the ICV, whereas lesions in the ileal Peyer's patches (IPP) appeared in low numbers and only in lambs infected with the C-type strains. This finding has been reported previously (Valheim *et al.*, 2002; Delgado *et al.*, 2013) and could indicate a different functional pattern between IPP and JPP related to the morphological and lymphocyte distribution differences observed (Corpa *et al.*, 2001; Valheim *et al.*, 2002). Lesions only appeared in the lymph nodes when they were already present in the intestine in a remarkably lower number. This finding, supported by other studies (Pérez *et al.*, 1996; Delgado *et al.*, 2013), would confirm the critical role of the intestinal lymphoid tissue in the start of *Map* infection, which would be detected in the lymph nodes only when lesions are well established in the gut.

The recognized difficulty in culturing *Map* from ovine tissues (Juste *et al.*, 1994; Whittington *et al.*, 2011) in terms of slowness and low performance

of bacterial isolation, was the reason for using a nested PCR method for confirming *Map* infection in the tissues of the challenged animals, in addition to the presence of the specific granulomatous lesions or AFB. This method has successfully been used and shown to have a higher sensitivity than *Map* culture or other PCR methods (Bull *et al.*, 2003; Delgado *et al.*, 2013). However, it has to be taken into account that the PCR method identifies DNA in the tissues that could have originated from non-viable and/or degraded bacilli. In our study, the presence of *Map* DNA was demonstrated in all infected animals, except one from the K-10 group culled at 390 dpi in which no lesion was detected, with no other differences with the time of sampling, in contrast to the lower number of granulomas detected at 390 dpi. It can be hypothesised that if bacterial culture had been performed, a lower number of colonies would have been isolated at 390 dpi in C strain infected lambs. Furthermore, similar to previous studies (Delgado *et al.*, 2013), two lambs infected with S-type strains, in which no lesions were observed, were also positive for PCR. In contrast to the higher prevalence of lesions in the JPP, no differences in the percentages of positivity by PCR were detected among the three regions of gut analysed, suggesting that the DNA from *Map* is spread along the intestinal tissues even without being related to evident lesions.

The low rate of identification of AFB in the tissues either by ZN or immunohistochemical methods was not surprising. Previous studies have shown that the focal and multifocal lesions contain no or very few AFB (Pérez *et al.*, 1996; González *et al.*, 2005; Verna *et al.*, 2007; Delgado *et al.*, 2013). The morphology of the diffuse lesions found in the 764 group was consistent with the so-called “lymphocytic” diffuse forms of paratuberculosis (Clarke *et al.*, 1996; González *et al.*, 2005), characterised by the presence of very low numbers of bacteria.

This study has shown clear differences in the pathogenesis of *Map* infection related to the type of strain used in an experimental infection of lambs. Infection caused by C-type strains was more rapidly and easily established, showing the most severe lesions and a stronger immune response. However, as the infection progresses, a marked reduction in the amount and severity of the lesions, consistent with a regressive character, was observed in association with a high peripheral cellular response suggesting that, with time, infection could have disappeared in these animals. In contrast, lambs infected with S-type strains developed focal granulomas located in the intestinal lymphoid tissue that persisted throughout the experiment. Although, in field cases, cross infection between S and C strains has been reported (Moloney and Whittington, 2008; Whittington *et al.*, 2011; Dimarelli-Mali *et al.*, 2013), its occurrence has been considered as infrequent (Collins *et al.*, 1990; Marsh *et al.*, 1999; Whittington *et al.*, 2000). Considering our results, it seems feasible that in areas where cattle and sheep graze together and cross infection could occur naturally (Muskens *et al.*, 2001; Moloney and Whittington, 2008), most of the sheep infected with C-type-strains could recover from the infection.

Competing interests

The authors declare that they have no competing interests.

Authors' contributions

MF performed the experiment, participated in all the immune response and pathological studies and collaborated in the analysis of the data and writing of the paper. JB contributed to the sample collection, pathological studies, interpretation of the results and helped to draft the manuscript. IAS prepared the administered inocula and collaborated in writing the paper. MF participated in the sample collection, pathological studies and carried out the immunohistochemical analysis. PC performed the immune response analysis and helped in the sample collection. LD

contributed to sample collection and to the pathological studies. JFGM collaborated in the pathological studies. JMG participated in the design of the experiment and inocula preparation. MCF collaborated in the sample collection, analysis of the data and helped write the manuscript. VP conceived and designed the experiment, analysed the data and wrote the paper. All the authors read and approved the final manuscript.

Acknowledgements

This work was supported by grant AGL2008-05820-C02 of the Spanish Ministry of Science and Innovation. The authors wish to thank all the staff of the IGM (CSIC-ULE) responsible for handling the experimental animals. The technical help of S. Morales, G. Belver and J. Reyero, and the proof-reading of the manuscript by Dr Stephen Maley, of the Moredun Research Institute, is also acknowledged. M. Fernández is founded by a predoctoral contract from the “Junta de Castilla y León”. J. Benavides is supported by CSIC through the JAE-Doc program, financed in part by European Social Fund (ESF). We acknowledge support of the publication fee by the CSIC Open Access Publication Support Initiative through its Unit of Information Resources for Research (URICI).

References

- Abendaño N, Sevilla IA, Prieto JM, Garrido JM, Juste RA, Alonso-Hearn M (2013). *Mycobacterium avium* subspecies *paratuberculosis* isolates from sheep and goats show reduced persistence in bovine macrophages than cattle, bison, deer and wild boar strains regardless of genotype. *Vet Microbiol.* 163:325–334.
- Begara-McGorum I, Wildblood LA, Clarke CJ, Connor KM, Stevenson K, McInnes CJ, Sharp JM, Jones DG (1998). Early immunopathological events in experimental ovine paratuberculosis. *Vet Immunol Immunopathol.* 63:265–287.
- Begg DJ, de Silva K, Carter N, Plain KM, Purdie A, Whittington RJ (2010). Does a Th1 over Th2 dominance really exist in the early stages of *Mycobacterium avium* subspecies *paratuberculosis* infections? *Immunobiology.* 216:840–846.
- Begg DJ, de Silva K, Di Fiore L, Taylor DL, Bower K, Zhong L, Kawaji S, Emery D, Whittington RJ (2010). Experimental infection model for Johne’s disease using a lyophilised pure culture, seedstock of *Mycobacterium avium* subspecies *paratuberculosis*. *Vet Microbiol.* 141:301–311.
- Begg DJ, Griffin JF (2005). Vaccination of sheep against *M. paratuberculosis*: immune parameters and protective efficacy. *Vaccine.* 23:4999–5008.


- Begg DJ, Whittington RJ (2008). Experimental animal infection models for Johne's disease, an infectious enteropathy caused by *Mycobacterium avium* subsp. *paratuberculosis*. *Vet J.* 176:129–145.
- Borrmann E, Möbius P, Diller R, Köhler H (2011). Divergent cytokine responses of macrophages to *Mycobacterium avium* subsp. *paratuberculosis* strains of Types II and III in a standardized in vitro model. *Vet Microbiol.* 152:101–111.
- Bull TJ, McMinn EJ, Sidi-Boumediene K, Skull A, Durkin D, Neild P, Rhodes G, Pickup R, Hermon-Taylor J (2003). Detection and verification of *Mycobacterium avium* subsp. *paratuberculosis* in fresh ileocolonic mucosal biopsy specimens from individual with and without Crohn's disease. *J Clin Microbiol.* 41:2915–2923.
- Clarke CJ, Patterson IAP, Armstrong KE, Low JC (1996). Comparison of the absorbed ELISA and agar gel immunodiffusion test with clinicopathological findings in ovine clinical paratuberculosis. *Vet Rec.* 139:618–621.
- Clarke CJ (1997). The pathology and pathogenesis of paratuberculosis in ruminants and other species. *J Comp Pathol.* 116:217–261.
- Collins DM, Gabric DM, de Lisle GW (1990). Identification of two groups of *Mycobacterium paratuberculosis* strains by restriction analysis and DNA hybridization. *J Clin Microbiol.* 28:1591–1596.
- Corpa JM, Juste RA, García-Marín JF, Reyes L, González J, Pérez V (2001). Distribution of lymphocyte subsets in the small intestine lymphoid tissue of 1-month-old lambs. *Anat Histol Embryol.* 30:121–127.
- Delgado L, García-Marín JF, Muñoz M, Benavides J, Juste RA, García-Pariente C, Fuertes M, González J, Ferreras MC, Pérez V (2013). Pathological findings in young and adult sheep following experimental infection with 2 different doses of *Mycobacterium avium* subsp. *paratuberculosis*. *Vet Pathol.* 50:857–866.
- Delgado L, Juste RA, Muñoz M, Morales S, Benavides J, Ferreras MC, García-Marín JF, Pérez V (2012). Differences in the peripheral immune response between lambs and adult ewes experimentally infected with *Mycobacterium avium* subspecies *paratuberculosis*. *Vet Immunol Immunopathol.* 145:23–31.
- Dimareli-Malli Z, Mazaraki K, Stevenson K, Tsakos P, Zdragas A, Giantzi V, Petridou E, Heron I, Vafeas G (2013). Culture phenotypes and molecular characterization of *Mycobacterium avium* subsp. *paratuberculosis* isolates from small ruminants. *Res Vet Sci.* 95:49–53.
- Dunn JR, Kaneene JB, Grooms DL, Bolin SR, Bolin CA, Bruning-Fann CS (2005). Effects of positive results for *Mycobacterium avium* subsp. *paratuberculosis* as determined by microbial culture of feces or antibody ELISA on results of caudal fold tuberculin test and interferon-gamma assay for tuberculosis in cattle. *J Am Vet Med Assoc.* 226:429–435.
- Elguezábal N, Bastida F, Sevilla IA, González N, Molina E, Garrido JM, Juste RA (2011). Estimation of *Mycobacterium avium* subsp. *paratuberculosis* growth parameters: strain characterization and comparison of methods. *Appl Environ Microbiol.* 77:8615–8624.
- Gil O, Díaz I, Vilaplana C, Tapia G, Díaz J, Fort M, Cáceres N, Pinto S, Caylà J, Corner L, Domingo M, Cardona PJ (2010). Granuloma encapsulation is a key factor for containing tuberculosis infection in minipigs. *PLoS One.* 5:e10030.
- Gillan S, O'Brien R, Hughes AD, Griffin JFT (2010). Identification of immune parameters to differentiate disease states among sheep infected with *Mycobacterium avium* subsp. *paratuberculosis*. *Clin Vaccine Immunol.* 17:108–117.

- González J, Geijo MV, García-Pariente C, Verna A, Corpa JM, Reyes LE, Ferreras MC, Juste RA, García Marín JF, Pérez V (2005). Histopathological classification of lesions associated with natural paratuberculosis infection in cattle. *J Comp Pathol.* 133:184–196.
- Gwozdz JM, Thompson KG, Manktelow BW, Murray A, West DM (2000). Vaccination against paratuberculosis of lambs already infected experimentally with *Mycobacterium avium* subspecies paratuberculosis. *Aust Vet J.* 78:560–566.
- Hughes JB, Hellmann JJ, Ricketts TH, Bohannon BJ (2001). Counting the uncountable: statistical approaches to estimating microbial diversity. *Appl Environ Microbiol.*; 67:4399–4406.
- Janagama HK, Il Jeong K, Kapur V, Coussens P, Srrevelsan S (2006). Cytokine responses of bovine macrophages to diverse clinical *Mycobacterium avium* subspecies paratuberculosis strains. *BMC Microbiol.* 6:10.
- Juste RA, García-Marín JF, Peris B, Sáez de Ocariz CS, Badiola JJ (1994). Experimental infection of vaccinated and non-vaccinated lambs with *Mycobacterium paratuberculosis*. *J Comp Pathol.* 110:185–194.
- Juste RA, Marco JC, Sáez de Ocariz C, Adúriz JJ (1991). Comparison of different media for the isolation of small ruminant strains of *Mycobacterium paratuberculosis*. *Vet Microbiol.* 28:385–390.
- Marsh I, Whittington R, Cousins D (1999). PCR-restriction endonuclease analysis for identification and strain typing of *Mycobacterium avium* subsp. paratuberculosis and *Mycobacterium avium* subsp. avium based on polymorphisms in IS1311. *Mol Cell Probes.* 13:115–126.
- Moloney BJ, Whittington RJ (2008). Cross species transmission of ovine Johne's disease from sheep to cattle: an estimate of prevalence in exposed susceptible cattle. *Aust Vet J.* 86:117–123.
- Muskens J, Bakker D, de Boer J, van Keulen L (2001). Paratuberculosis in sheep: its possible role in the epidemiology of paratuberculosis in cattle. *Vet Microbiol.* 78:101–109.
- Nisbet DI, Gilmour NJL, Brotherston JG (1962). Quantitative studies of *Mycobacterium johnei* in tissues of sheep: III: Intestinal histopathology. *J Comp Pathol.* 72:80–91.
- O'Brien R, Mackintosh CG, Bakker D, Kopečna M, Pavlik I, Griffin JF (2006). Immunological and molecular characterization of susceptibility in relationship to bacterial strain differences in *Mycobacterium avium* subsp. paratuberculosis infection in red deer (*Cervus elaphus*). *Infect Immun.* 74:3350–3357.
- Payne JM, Rankin JD (1961). A comparison of the pathogenesis of experimental Johne's disease in calves and cows. *Res Vet Sci.* 2:175–179.
- Pérez V, García-Marín JF, Badiola JJ (1996). Description and classification of different types of lesion associated with natural paratuberculosis infection in sheep. *J Comp Pathol.* 114:107–122.
- Pérez V, Tellechea J, Badiola JJ, Gutiérrez M, García Marín JF (1997). Relation between serologic response and pathologic findings in sheep with naturally acquired paratuberculosis. *Am J Vet Res.* 58:799–803.
- Pérez V, Tellechea J, Corpa JM, Gutiérrez M, García Marín JF (1999). Relation between pathologic findings and cellular immune responses in sheep with naturally acquired paratuberculosis. *Am J Vet Res.* 60:123–127.
- Sevilla I, Garrido JM, Geijo M, Juste RA (2007). Pulsed-field gel electrophoresis profile homogeneity of *Mycobacterium avium* subsp. paratuberculosis isolates from cattle and heterogeneity of those from sheep and goats. *BMC Microbiol.* 7:18.

- Stabel JR. Transitions in immune responses to *Mycobacterium avium paratuberculosis* (2000). *Vet Microbiol.* 77:465–473.
- Stamp JT, Watt JA (1954). Johne's disease in sheep. *J Comp Pathol.* 64:26–39.
- Stevenson K, Hughes VM, de Juan L, Inglis NF, Wright F, Sharp JM (2002). Molecular characterization of pigmented and non pigmented isolates of *Mycobacterium avium* subsp. *paratuberculosis*. *J Clin Microbiol.*; 40:1798–1804.
- Stewart DJ, Vaughan JA, Stiles PL, Noske PJ, Tizard ML, Prowse SJ, Michalski WP, Butler KL, Jones SL (2004). A long-term study in Merino sheep experimentally infected with *Mycobacterium avium* subsp. *paratuberculosis*: clinical disease, faecal culture and immunological studies. *Vet Microbiol.* 104:165–178.
- Taylor AW (1951). The varieties of *Mycobacterium johnei* isolated from sheep. *J Pathol Bacteriol.* 63:333–336.
- Valheim M, Storset AK, Aleksandersen M, Brun-Hansen H; Press MCL (2002). Lesions in subclinical paratuberculosis of goats are associated with persistent gut-associated lymphoid tissue. *J Comp Pathol.* 127:194–202.
- Vázquez P, Garrido JM, Juste RA (2013). Specific antibody and interferon-gamma responses associated with immunopathological forms of bovine paratuberculosis in slaughtered Friesian cattle. *PLoS One.* 8:e64568.
- Verna AE, García-Pariente C, Muñoz M, Moreno O, García-Marin JF, Romano MI, Paolicchi F, Pérez V (2007). Variation in the immuno-pathological responses of lambs after experimental infection with different strains of *Mycobacterium avium* subsp. *paratuberculosis*. *Zoonoses Public Health.* 54:243–252.
- Whittington RJ, Begg DJ, de Silva K, Plain KM, Purdie AC (2012). Comparative immunological and microbiological aspects of paratuberculosis as a model mycobacterial infection. *Vet Immunol Immunopathol.* 148:29–47.
- Whittington RJ, Hope AF, Marshall DJ, Taragel CA, Marsh I (2000). Molecular epidemiology of *Mycobacterium avium* subsp. *paratuberculosis*: IS900 restriction fragment length polymorphism and IS1311 polymorphism analyses of isolates from animals and a human strain in Australia. *J Clin Microbiol.* 38:3240–3248.
- Whittington RJ, Marsh IB, Saunders V, Grant IR, Juste R, Sevilla IA, Manning EJ, Whitlock RH (2011). Culture phenotypes of genomically and geographically diverse *Mycobacterium avium* subsp. *paratuberculosis* isolates from different hosts. *J Clin Microbiol.* 49:1822–1830.

4.2. SEGUNDO ESTUDIO

SECOND STUDY

	<p>Fernández M, Delgado L, Sevilla IA, Fuertes M, Castaño P, Royo M, Ferreras MC, Benavides J, Pérez V. Virulence attenuation of a <i>Mycobacterium avium</i> subspecies. <i>paratuberculosis</i> S-type strain prepared from intestinal mucosa after bacterial culture. Evaluation in an experimental ovine model. <i>Res Vet Sci.</i> 2015; 99:180-7.</p>
--	--

Factor de impacto 1,504

Veterinary Sciences 31/133

4.2. Virulence attenuation of a *Mycobacterium avium* subspecies *paratuberculosis* S-type strain prepared from intestinal mucosa after bacterial culture. Evaluation in an experimental ovine model.

Miguel Fernández¹, Laetitia Delgado¹, Iker A. Sevilla², Miguel Fuertes¹, Pablo Castaño¹, Marcos Royo¹, M. Carmen Ferreras¹, Julio Benavides¹, Valentín Pérez^{1*}

¹Departamento de Sanidad Animal, Instituto de Ganadería de Montana (CSIC-ULE), Facultad de Veterinaria, Universidad de León, Campus de Vegazana s/n, 24071 León, Spain.

²Departamento de Sanidad Animal, NEIKER-Tecnalia, Berreaga 1, 48160 Derio, Bizkaia, Spain.

*Corresponding author: Valentín Pérez (vperp@unileon.es)

Received: 8 October 2014

Accepted: 6 February 2015

Abstract

The differences in pathogenicity between an inoculum derived directly from an intestinal tissue homogenate from a paratuberculosis affected sheep and the S-type *Mycobacterium avium* subsp. *partuberculosis* (*Map*) strain isolated in laboratory media from the mentioned homogenate were assessed in two experiments in lambs. Specific peripheral immune responses were significantly lower in animals inoculated with the cultured organisms that showed only granulomatous lesions in the intestinal lymphoid tissue. However, in the homogenate group, more abundant granulomata also occurred in the lamina propria. *Map* was isolated only in lambs infected with

the culture strain. *Map* DNA was demonstrated by nested- PCR in all the lambs but in a lower proportion (57.1% vs 100%) in those from the culture group. Under these particular experimental conditions, the results suggest that an attenuation of *Map* virulence has occurred in the cultured strain compared to the initial tissue homogenate, even after a low number of passages.

4.2.1. Introduction

Paratuberculosis or Johne's disease is a chronic bacterial infection of wild and domestic ruminants caused by *Mycobacterium avium* subsp. *paratuberculosis* (*Map*). Infected animals develop granulomatous enteritis associated with a progressive loss of weight, diarrhea and eventually death. The infection by *Map* is widespread, causes important economic losses to livestock and it has been associated with Crohn's disease in humans (Bull *et al.*, 2003; Juste, 2012).

Experimental infection is considered an essential tool to investigate different aspects of paratuberculosis as it allows control of different variables that operate in the interaction between *Map* and the host. Due to the variety of challenge models employed, standard guidelines have been proposed with the objective of being accepted worldwide (Hines II *et al.*, 2007).

Sheep have been used as an experimental model of paratuberculosis as the results can be easily extrapolated to other ruminant species but the main difficulty encountered has been the type of infectious inoculum employed (Hines II *et al.*, 2007; Begg and Whittington, 2008; Begg *et al.*, 2010). *Map* strains are classified by the use of IS900 restriction fragment length polymorphism (RFLP) and IS1311 PCR-restriction enzyme analysis (PCR-REA), into two main genotypes (Collins *et al.*, 1990; Stevenson *et al.*, 2002; Sevilla *et al.*, 2005): sheep or ovine isolates (also called "S type" or

“type-I and III”), associated with natural ovine paratuberculosis, and cattle or bovine isolates (also called “C type” or “type II”). When C-type strains have been used to challenge sheep, the outcome of the infection has shown marked differences with that seen in natural conditions (Stewart *et al.*, 2004; Verna *et al.*, 2007; Fernández *et al.*, 2014). Therefore, it has been recommended to use S-type strains to more closely reproduce natural ovine infections (Hines II *et al.*, 2007). However, the difficulty in culturing S-type strains (Whittington *et al.*, 2011) is probably the main reason why tissue homogenates obtained from intestinal mucosal scrapings from clinically diseased animals have been the preferred inocula (Kurade *et al.*, 2004; Stewart *et al.*, 2004; Verna *et al.*, 2007; Begg and Whittington, 2008; Delgado *et al.*, 2013). Conversely, it has been advised not to use direct tissue homogenate as inocula for experimental challenge studies in sheep due to the low repeatability as a consequence of the limited amount of material available from any given animal. Additionally, the inability to control all the components present in the inoculums is why the use of virulent, low passage S-type strain cultivated *in vitro* has been recommended for inocula (Hines II *et al.*, 2007).

Experimental infections in sheep using ovine cultured bacteria have shown discordant results with infectious rates ranging from very low levels to 100% (Thorel *et al.*, 1992; Reddacliff and Whittington, 2003; Begg *et al.*, 2005; Fernandez *et al.*, 2014). Previous studies (Stewart *et al.*, 2004; Begg *et al.*, 2005, 2010) have shown that infection was more clearly established when the challenge inoculums was prepared from intestinal tissue compared to cultured strains. It should be noted that in those studies the cultured strain used in the inoculum was isolated from a different sheep to that used in the preparation of the intestinal homogenate. Variations in pathogenicity among the different strains of *Map* have been already reported (Verna *et al.*, 2007; Begg and Whittington, 2008; Fernández *et al.*, 2014) and could explain the

success differences on infected animals observed among the different inocula.

Recently, a model to evaluate the outcome of *Map* infection based on the assessment of histological changes together with the peripheral immune response, and *Map* detection in tissues, has been successfully employed in experimentally infected lambs (Delgado *et al.*, 2013; Fernandez *et al.*, 2014). Pathological changes are evaluated by counting granulomata in the intestine and lymph nodes. In addition, the distribution of lesions in the same samples is analyzed in order to estimate the stage of the disease. According to the suggested pathogenesis of paratuberculosis, initial or latent lesions are restricted to the lymphoid tissue and when the infection progresses, granulomatous lesions extend to the intestinal lamina propria (Nisbet *et al.*, 1962; Juste *et al.*, 1994; Delgado *et al.*, 2013; Pérez *et al.*, 1996; Kurade *et al.*, 2004).

The aim of this study was to investigate, in a lamb experimental model, the existence of differences in the virulence of an inoculum composed of either (1) homogenate of gut mucosal tissue from a diseased sheep or (2) the bacteria isolated from that homogenate obtained after laboratory culture, by assessing the peripheral humoral and cellular immune responses, the degree of bacterial colonization of the tissues and the pathological changes.

4.2.2. Material and methods

Challenge inocula

a) Intestinal mucosa derived homogenate inoculum

This inoculum was prepared from several ileal and jejunal pieces of tissue obtained from one sheep with clear clinical signs of paratuberculosis.

Before extracting the mycobacteria, shedding of abundant acid fast bacilli (AFB) was confirmed by microscopical examination of fecal samples and histological sections of gut tissue. Mycobacteria were extracted following the method of Ratnamohan and Spencer (1986). The inoculum obtained was IS900 positive by polymerase chain reaction (PCR) and typed as an “ovine” strain by IS1311 PCR-restriction enzyme analysis (Garrido *et al.*, 2000; Sevilla *et al.*, 2005). Furthermore, the strain was typed using a *SnaBI-SpeI* pulse-field electrophoresis method (Sevilla *et al.*, 2007) and only one profile was obtained, being characterized as a 69-50 type III strain.

For determining the concentration of organisms present in the inoculum, ten-fold dilutions were prepared and plated onto Middlebrook 7H11 medium, as described previously (Aduriz *et al.*, 1995), to assess the number of colony forming units (CFU) per milliliter in the inoculum. The final concentration resulted in 4×10^6 CFU of *Map*/ml.

b) Pure culture inoculum

A positive *Map* isolation was obtained after plating the tissue homogenate inoculum both in Lowenstein-Jensen and Middlebrook 7H11 media. According to the procedures described (Garrido *et al.*, 2000; Sevilla *et al.*, 2005), both isolates were IS900 positive and classified an “ovine” strain by IS1311 PCR-REA. When typed by *SnaBISpeI* pulse-field electrophoresis method (Sevilla *et al.*, 2007), both isolates showed the same profile (69-50 type III strain) than the tissue homogenate inoculum. Thus, after the first isolation of the *Map* strain in 7H11 medium from the intestinal mucosa homogenate, one passage was made in Middlebrook 7H9 broth supplemented with OADC (oleic acid, albumin, dextrose, catalase) enrichment (Becton Dickinson and Co., MD), Tween 80 (Panreac Quimica SA, Barcelona, Spain), glycerol and mycobactin J (Allied Monitor Inc, Fayette, MO) and subsequently the strain was maintained at -80 °C as a glycerol stock. Finally,

the strain was propagated in 7H9 broth prepared as mentioned earlier. After 5 weeks at 37 °C, cultures were harvested by centrifugation at 2800 x g for 15 min. Bacterial pellets were washed twice in phosphate buffered saline (PBS), resuspended in PBS and the presence of clumps minimized by making the liquid flow up and down through a fine needle (26G3/8) several times. The turbidity (McFarland units) of the resultant suspension was measured using a Densimat (bioMerieux, Marcy l' Etoile, France). Expected cell concentration was estimated assuming one McFarland unit represented 1×10^8 cells/ ml (Hughes *et al.*, 2001).

Concentration of the suspension resulted in 1×10^8 cells/ ml. As for the tissue homogenate inoculum, the number of CFU was assessed by plating ten-fold dilutions of the suspension onto agar solidified Middlebrook 7H11 medium (Aduriz *et al.*, 1995). The final concentration resulted in 5×10^7 CFU/ml.

For both inocula and in order to assess the potential reduction of viability during the administration period, the plating procedure was repeated on the last challenge day using a separate aliquot prepared and kept under the same conditions as those of the administered inocula. After 15 days at 4 °C, a reduction of less than one logarithm was detected in CFU counts of both inocula. In order to assess variations in the strain during the storage of the inocula, the isolate given to the lambs in the last challenge was typed by *SnaBI-SpeI* pulse-field electrophoresis method (Sevilla *et al.*, 2007) and the same profile (69-50 type III strain) showed by the initial challenge dose isolate and the tissue homogenate inoculum.

Animals and experimental design

All protocols involving animals were approved by the Animal Welfare Committee of the "Instituto de Ganaderia de Montana CSIC-ULE", following

procedures described in Spanish and EU legislation (Law 32/2007, R.D. 1201/2005, and Council Directive 2010/63/EU). All animals used in this study were handled in strict accordance with good clinical practice and all efforts were made to minimize suffering.

A total of 21 1-month old lambs of the Churra breed were used in the study. They were randomly selected from a single flock in which no clinical cases of paratuberculosis had been reported in the past 5 years. All the dams were negative for antibody detection to *Map* and peripheral blood mononuclear cells interferon- γ release test.

In the first experiment, 14 randomly selected lambs were used. They were divided into 2 groups, each composed of 7 lambs: one was infected with the tissue homogenate inoculum (homogenate group) and the remaining were kept as uninfected negative controls.

As S-type strains of *Map* had a slow growth in culture, needing long periods of time to reach the amount required for infecting lambs, and in order to avoid freezing the tissue homogenate inoculums for a long period of time, the infection of lambs with cultured bacteria took place approximately 1 year after the beginning of the first study. In this experiment, a new group of 7 Churra lambs coming from the same flock and born to the same ewes employed in the previous study was infected with the pure culture inoculums (culture group). All the experimental procedures were carried out in the same season of the year and in the same experimental facilities where the lambs, after a period of adaptation, were allocated to separate pens. The animals were fed grass hay *ad libitum* and a conventional compound feed appropriate for each age.

Each experimentally infected lamb was orally challenged using an automatic syringe, with a total dose of 40 ml of the respective inoculum,

administered in 4 doses of 10 ml given at 3-day intervals. Lambs from the control group were challenged with saline solution.

Blood samples were collected from the jugular vein into 10 ml evacuated tubes (Vacutainer®, Becton Dickinson, Plymouth, UK) containing lithium heparin or without anticoagulant for IFN- γ and antibody (Ab) determination studies respectively. Blood samples were taken at monthly intervals from day 0 up to 240 dpi. On day 120 after infection, three lambs from each group were humanely culled, after sedation with xylazine (Rompun®, Bayer Animal Health, Mannheim, Germany), by an intravenous overdose of embutramide and mebezonium iodide (T61®, Intervet, Salamanca, Spain), followed by immediate exsanguination. The remaining animals were killed at 240 days post-infection (dpi).

Cell mediated immune response determination

Single intradermal skin test (IDT)

One month before euthanasia (90 and 210 dpi), 0.1ml of an avian protein derivative (PPD) antigen (CZ Veterinaria, Porrino, Spain), at a concentration of 0.5 mg/ml, was injected intradermally in the skin fold of the tail. Skin-fold thickness was measured at the injection site with callipers before injection and 72 h later. Results were expressed as the increase in mm of skin thickness. For diagnostic purposes, an animal was considered positive when the increase was ≥ 2 mm (Perez *et al.*, 1999).

Interferon- γ (IFN- γ) release assay (IGRA)

Two separate aliquots of 1.5 ml from the whole blood sample taken into heparinized tubes were mixed in a laminar flood hood with either 100 μ l of sterile PBS (negative control) or avian PPD (CZ Veterinaria, Porriño, Spain) at a final concentration of 30 μ l/ ml within 3 h from the time of collection.

Blood cultures were incubated for 20 h at 37 °C in a humidified chamber and, after centrifugation, the plasma supernatant was removed and kept at –20 °C until required. Plasma samples were assayed in duplicate for IFN- γ determination using a commercial immunoassay kit (BOVIGAM[®], Prionics AG, Switzerland). In order to avoid inter-plate variations, all the optical density (O.D.) values were adjusted by dividing the sample O.D. minus the negative control O.D., by the positive control O.D. minus the negative control O.D., from each plate. Once the raw values were standardized, results were expressed as a quotient between the mean O.D. of the avian PPD-stimulated plasma and the O.D. of the same plasma incubated with PBS.

Humoral immune response determination by indirect ELISA (Ab ELISA)

Blood samples without anticoagulant were allowed to clot and the serum was removed and frozen at –20 °C until required. The production of Ab against *Map* was assessed by an in-house indirect ELISA (Fernández *et al.*, 2014) using the PPA-3 protoplasmic antigen of *Map* (Allied Monitor Inc, Fayette, MO, USA) and a horseradish peroxidase conjugated to protein G (BioRad, Hercules, USA). The results were expressed as a quotient between the mean O.D. of each sample sera and the mean O.D. of the positive control serum in each plate.

Pathological studies and granuloma count

Complete necropsies were performed on all the experimental animals. Samples for histological examination were taken from the ileocecal valve (ICV), ileum (IL) (three 5-cm samples, taken 20, 40 and 60 cm from the ICV), jejunum (JJ) and jejunal Peyer's patches (JPP) (at least 3 patches from each of the proximal, mid and distal zones), the caudal mesenteric lymph node (MLN), one jejunal lymph node (JLN), and ileocecal lymph nodes (ILN). All tissues were fixed in 10% neutral buffered formalin, dehydrated through a

graded alcohol series before being embedded in paraffin wax. Sections, 4 μm thick, were stained with hematoxylin and eosin (HE) and by the Ziehl-Neelsen (ZN) technique for AFB and examined by light microscopy for histological changes.

The presence of *Map* antigens in the tissue sections showing histological lesions was assessed immunohistochemically using a specific rabbit anti-*Map* serum, as described elsewhere (Delgado *et al.*, 2013). The amount of AFB and *Map* antigens in the lesions was subjectively scored into 5 categories: 0 (no AFB or *Map* antigens), +/- (doubtful presence of bacteria), + (solitary or very few bacteria), ++ (moderate amount of AFB or antigens), +++ (large amount of AFB or *Map* antigens in the cytoplasm of macrophages).

All the lesions consistent with paratuberculosis infection observed in the examined samples were classified following the guidelines previously proposed (Pérez *et al.*, 1996; Delgado *et al.*, 2013) for ovine species, according to the distribution and location of the granulomata in the different intestinal compartments.

After histopathological examination, the number of granulomata per tissue was quantified, as previously reported (Delgado *et al.*, 2013; Fernández *et al.*, 2014). Briefly, three tissue sections from each different intestinal sites and 2 sections from each lymph node, with approximately the same area, were assessed blindly and the mean number of granulomata per tissue section in each site was recorded by the same observer (MF), distinguishing those granulomata located in the lymphoid tissue (LT) from those in the associated lamina propria (LP) or in the mucosa unrelated to LT.

Tissue culture

Bacterial isolation was performed on tissue samples from the ICV, a 5-cm sample of the distal ileum (dIL), mid jejunum Peyer's patch (mJPP) and

caudal MLN. Two grams of tissues was processed for culture onto two tubes containing Middlebrook 7H11 solid medium (Difco, MD, USA) supplemented with OADC (BD, MD, USA) and also two Lowenstein-Jensen tubes (Difco, MD, USA). Both media were supplemented with mycobactin J (Allied Monitor Inc, Fayette, MO) and with penicillin, chloramphenicol, and amphotericin B (Sigma- Aldrich, Madrid, Spain). The tubes were incubated at 37 °C and growth was monitored under stereoscopic light microscopy every 2 months until 10 months post-inoculation. When a colony was detected, a smear was made and stained by the ZN method for AFB and confirmed by PCR to be IS900 positive (Garrido *et al.*, 2000).

Nested-PCR

A nested PCR for the detection of *Map* DNA was performed on tissue samples adjacent to those taken from bacteriological culture from the ICV, dIL, mJPP and MLN. DNA was isolated from 0.5 g of each tissue sample, using Speedtools Tissue DNA extraction kit following the manufacturer instructions (Biotools® B&M Labs SA, Madrid, Spain), and the resultant DNA samples frozen at -20 °C until analysis was performed. The nested PCR was carried out as described previously (Delgado *et al.*, 2013), using primers to detect the presence of *Map*-specific IS900 DNA.

Statistical analysis

Data from IFN- γ , Ab production and granuloma count were subjected to analysis of variance using the general lineal model procedure (GLM) of the SAS statistical package (version 9.1; SAS Institute, Cary, NC, USA). The results were logarithmically transformed to enable them to be submitted to normal distribution-based tests of significance. Differences among experimental groups at each time of sampling were evaluated using Student's *t*-test for pair-wise comparisons with the Tukey-Kramer method correction, at the 95%

significance level. The results of the IDT and the culture and PCR positive frequencies were compared and tested for significance by chi-squared analysis.

4.2.3. Results

No clinical signs related to *Map* infection were detected in any of the challenged lambs.

Peripheral immune response

Figure 1 shows the results of the IDT test. An increase in skin thickness was seen in both infected groups, but the response was higher in lambs from the homogenate group ($p < 0.05$) at both tests. While there was no significant difference in the response between lambs from the homogenate group tested at 90 and 210 dpi, there was a significant decrease ($p < 0.05$) in the skin thickness of lambs from culture group between 90 and 210 dpi. The mean of increase in the skin thickness in this latter group did not reach the value considered as positive (2 mm).

The kinetics of IFN- γ production by blood cells in the different groups is represented in Fig. 2. A significant increase ($p < 0.05$) with respect to the other two groups was observed in lambs from the homogenate group from 90 dpi until the end of the experiment. However, no differences were seen between culture and control groups except for lambs tested at 90 dpi ($p < 0.05$). The serology is shown in Fig. 3. Significant differences were seen only between the homogenate and the rest of the groups from 120 dpi until the end of the experiment ($p < 0.05$).

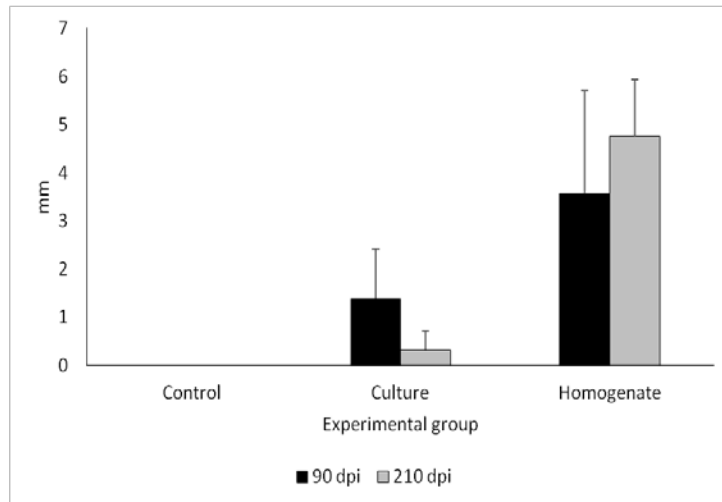


Figure 1. Response to intradermal skin test (IDT). The results are expressed as the skinfold thickness increase (in mm) after intradermal injection of avian PPD at 90 and 210 dpi in the three experimental groups. Error bars: standard deviation.

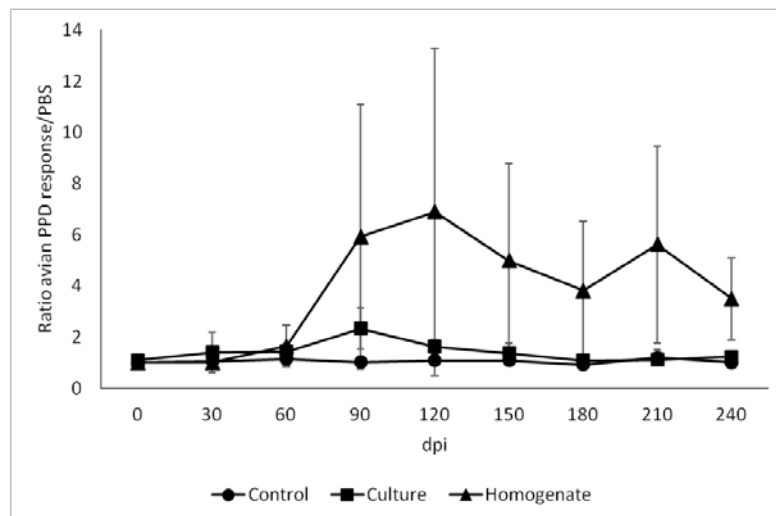


Figure 2. Kinetics of the specific IFN- γ production by peripheral blood cells stimulated with avian PPD in the three experimental groups throughout the experiment. Error bars: standard deviation.

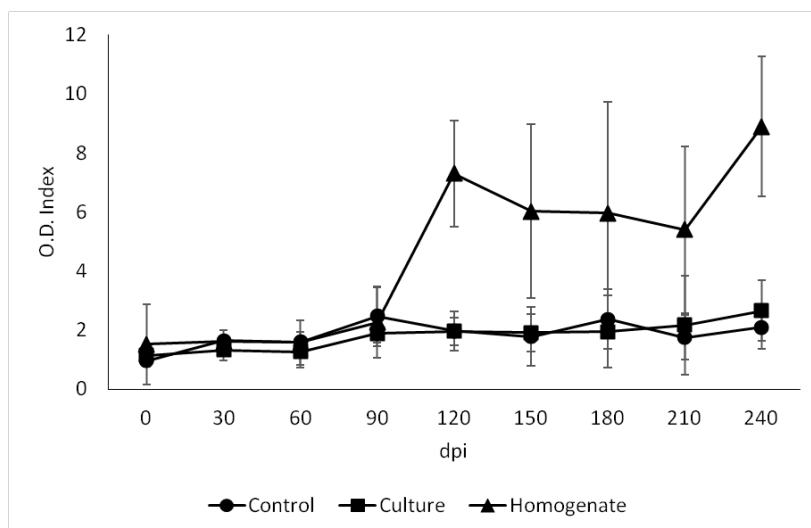


Figure 3. Kinetics of antibody production of the three experimental groups throughout the experiment. Error bars: standard deviation.

Pathological findings

No clinical sign or gross lesions related to paratuberculosis were seen in any lamb during the experiment. When examined microscopically, granulomatous lesions consistent with *Map* infection were found in the seven lambs from homogenate group but only in four animals from the culture group. Moreover, differences were observed in the extension and type of lesion between both groups and time of culling.

No microscopic lesions were detected in the control group. Lesions in lambs from the culture group (Table 1) were categorized as *focal*. They were composed of small, well-defined granulomata formed by groups of 10-40 macrophages that appeared exclusively in the interfollicular area of the intestinal LT or lymph nodes, without disturbing the normal architecture of the organ. These lesions appeared in two out of three lambs (66.6%) culled at 120 dpi and in two of the four animals (50%) examined at 240 dpi.

Table 1. Distribution of lambs from the culture group according to lesion type, number of granulomata, presence of acid-fast bacilli in the tissues and result of microbiological culture and nested-PCR

Time of culling	Lamb ID	Type of lesion ^a	Total No of granulomata	ZN ^b	IHC ^b	Culture ^c	Nested PCR ^c
120 dpi	23	F	11	0	0	Neg	JPP, LN
120 dpi	24	Neg	0	0	0	Neg	Neg
120 dpi	21	F	10	+/-	+	Neg	ICV, JPP
240 dpi	22	Neg	0	0	0	Neg	Neg
240 dpi	25	F	3	0	0	Neg	Neg
240 dpi	26	Neg	0	0	0	Neg	LN
240 dpi	27	F	6	0	+/-	Neg	JPP

^a F, focal; Neg, no lesion. ^b Intensity of staining, from 0 (no staining) to +++ (high amount of acid-fast bacilli or *Map* antigens in the cytoplasm of the macrophages). ^c Neg: negative. Tissue sample with positive result: ICV, ileocecal valve; JPP, jejunal Peyer's patch; LN, mesenteric lymph node. ID: identification. dpi: days post-infection. ZN: Ziehl-Neelsen technique. IHC: Immunohistochemistry for *Map* antigens detection.

In contrast, lesions in lambs from the homogenate group (Table 2) were more severe. In two lambs (culled at 120 and 240 dpi) lesions were classified as *multifocal a*. They were formed by granulomata located in the LT, similar to those seen in the culture group but more abundant and, in addition to that, small granulomata were also present in the LP of the mucosa associated with the LT. Four lambs (two of each examined at both times of culling) showed lesions categorized as *multifocal b*. In these animals, granulomatous lesions were similar to those already described in the LT and related LP but also extended to areas of the intestinal LP not associated with LT, where they caused separation of the intestinal glands and enlargement of the villi.

Granulomata were also present in the lymph nodes in higher numbers than in the previous types of lesion. The remaining lamb (culled at 240 dpi)

showed a focal form. The number of AFB detected by ZN varied from hardly any in *focal* lesions to abundant in some granulomata located in the LP in lambs with *multifocal b* lesions (Tables 1 and 2). No AFB or lesions consistent with Map infection were seen in the negative control lambs.

Table 2. Distribution of lambs from the homogenate group according to their type of lesion, number of granulomata, presence of acid-fast bacilli in the tissues and results of microbiological culture and nested- PCR.

Time of culling	Lamb ID	Type of lesion ^a	Total No of granulomata	ZN ^b	IHC ^b	Culture ^c	Nested PCR ^c
120 dpi	47	Mfa	30	+	+	Neg	ICV
120 dpi	51	Mfb	1325	++	++	ICV	ICV, JPP
120 dpi	54	Mfb	165	++	+++	Neg	ICV, JPP, MLN
240 dpi	48	Mfb	484	+++	+++	ICV	ICV, JPP, MLN
240 dpi	49	Mfb	745	+	+	Neg	ICV, JPP, MLN
240 dpi	50	Mfa	49	+	+	ICV	ICV, JPP, MLN
240 dpi	52	F	36	0	+	Neg	ICV, MLN

^a F: focal; Mfa: multifocal a; Mfb: multifocal b.

^b Intensity of staining, from 0 (no staining) to +++ (high amount of acid-fast bacilli or *Map* antigens in the cytoplasm of the macrophages).

^c Neg: negative. Tissue sample with positive result: ICV, ileocecal valve; JPP, jejunal Peyer's patch; LN, mesenteric lymph node. ID: identification. dpi: days post-infection. ZN: Ziehl-Neelsen technique. IHC: Immunohistochemistry for *Map* antigens detection.

The mean number of granulomata per lamb is shown in Table 3. The number of granulomata was significantly higher ($p < 0.001$) in lambs from homogenate than culture group at both sampling time points. A significant decrease ($p < 0.05$) could also be observed in both groups between lambs culled at 120 and 240 dpi. The distribution of the lesions in each location examined in both challenged experimental groups is shown in Fig. 4. In lambs from the culture group (Fig. 4a), lesions were found exclusively in the ICV, the different JPP and LN, with no statistically significant differences between the

locations. In spite of the presence of LT in all the samples examined from the ileum, no lesions were seen in this location. In all the sites, except for the mJPP and ICLN, a significant reduction in the number of granulomata ($p < 0.05$) was detected between lambs culled at 120 compared to 240 dpi. In lambs from the homogenate group (Fig. 4b) granulomatous lesions were seen in all the samples examined, including the ileum and areas of the jejunum without LT. Except for the pJPP and ICLN sites, no statistically significant differences were seen in the number of granulomata according to their location between lambs culled at 120 and 240 dpi.

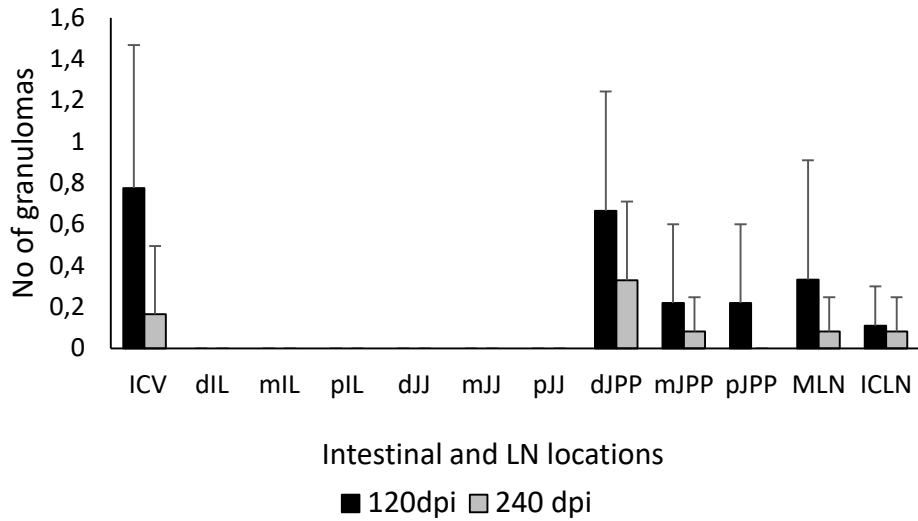
However, when considering the distribution of the lesions in the different intestinal compartments, regardless of the location (Fig. 5), a significant decrease ($p < 0.05$) was seen in the number of granulomata located in the LT and an increase in those seen in areas of LP not associated with LT ($p < 0.05$) between lambs culled at 120 and 240 dpi from the homogenate group.

Table 3. Mean number of granulomata per animal \pm standard deviation, in lambs from the culture and homogenate groups culled at 120 and 240 dpi.

	Culture	Homogenate
120 dpi	6.98 (\pm 6.06)	506.59 (\pm 711.90)
240 dpi	2.22 (\pm 2.84)	328.41 (\pm 488.31)

dpi: days post-infection.

A



B

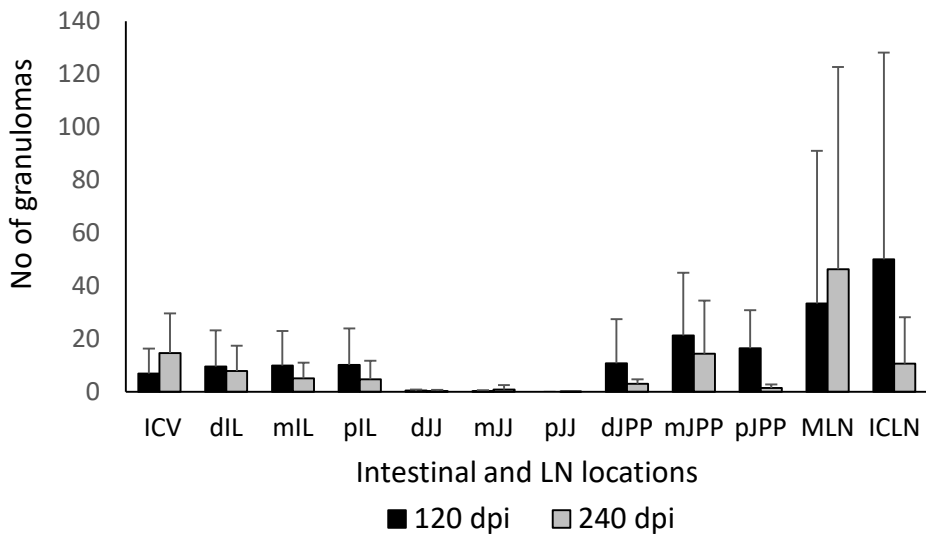


Figure 4. Mean of the total number of granulomata per tissue section and animal according to their intestinal location in lambs from culture (a) and homogenate (b) groups, regardless of the time of sampling. ICV, ileocecal valve; IL, ileum, JJ, jejunum; JPP, jejunal Peyer’s patches; MLN, mesenteric lymph node; ICLN, ileocecal lymph node. d, Distal; m, mid; p, proximal. Error bars: standard deviation.

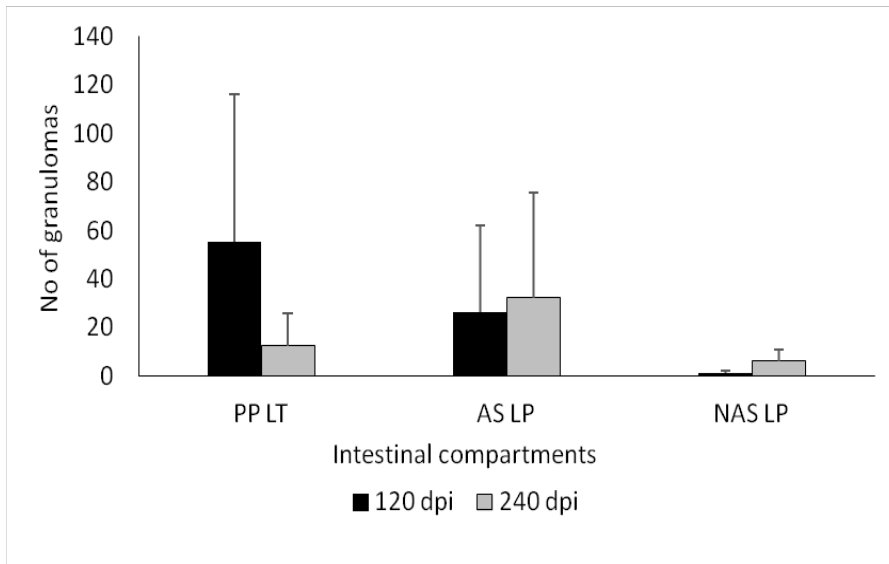


Figure 5. Mean number of the granulomata per animal, in lambs from homogenate group, according to their location in the different intestinal compartments. PP LT, Peyer's patches lymphoid tissue; AS LP, lamina propria associated with Peyer's patches; NAS LP, lamina propria not associated with Peyer's patches. Error bars: standard deviation.

Map detection in tissues by culture and nested PCR

The number and samples where *Map* could be isolated by culture or *Map* DNA could be demonstrated by nested PCR in the experimental animals is shown in Tables 1 and 2. In lambs from the culture group, no isolation was successful by culture while *Map* DNA was demonstrated in four out of the eight (50%) examined lambs.

In three lambs from the homogenate group *Map* could be cultured, always in samples from the ICV (in two cases in the Lowenstein-Jensen and Middlebrook 7H11 tube respectively, and in the two media in the remaining animal). By nested PCR, *Map* DNA was detected in all the lambs of this group. No *Map* isolation or DNA detection was observed in lambs from the control group.

4.2.4. Discussion

Under the experimental conditions used in this study, a marked attenuation of the virulence of a low-passage cultured *Map* strain has been observed, when compared with the tissue homogenate from which it was isolated. Previous reports have shown that experimental infection with an inoculum obtained directly from the intestinal mucosa of diseased animals results in more rapid and severe forms of disease compared to inoculation of cultured bacteria (Stewart *et al.*, 2004; Begg *et al.*, 2005). These differences have not been so clearly seen in other studies (Begg *et al.*, 2010). In all experiments mentioned earlier, the gut tissue homogenate and cultured bacteria used for challenge originated from different flocks, so it is possible that different strains of *Map* were used (Stewart *et al.*, 2004).

In this sense, the existence of differences in virulence between *Map* strains has been widely documented (Verna *et al.*, 2007; Begg and Whittington, 2008; Fernández *et al.*, 2014). However, this possibility is highly unlikely in this study as the same strain of *Map* was employed, as seen by the molecular typing techniques employed, either as a direct isolate from the tissue or after its passage by culture media. Although the complete absence of other *Map* strains in the tissue homogenate cannot be completely guaranteed, the bacteriological procedures employed were those recommended for the isolation of ovine *Map* strains (Adúriz *et al.*, 1995; Hines II *et al.*, 2007; Whittington *et al.*, 2011).

Besides the individual strain virulence, other factors can also influence the outcome of experimental *Map* infection (Hines II *et al.*, 2007; Begg and Whittington, 2008; Juste, 2012) such as the dose administered and the age or the genetic resistance of the experimental animals. It has been shown previously that there is a direct relationship between the dose administered and the outcome of the infection (Reddacliff and Whittington, 2003;

McGregor *et al.*, 2012; Delgado *et al.*, 2013). In this study we have chosen an infectious dose that has been shown to be effective in previous studies (Begg and Whittington, 2008). Furthermore, despite the fact that the number of CFUs used to infect the culture group was slightly higher, the symptoms of infection were milder. Regarding the age, 1-month old lambs were used in both groups, when susceptibility to infection is high (Begg and Whittington, 2008; McGregor *et al.*, 2012; Delgado *et al.*, 2013).

Some of the conditions in which this study was performed should be taken into account when interpreting the results. The slow multiplication rate of S-type *Map* in strains in laboratory culture and the need to use fresh original tissue homogenate to avoid loss of bacterial viability after freezing forced to divide this experiment in two separate infections 1 year apart. Moreover, only a control group was employed in the first experiment, in order to minimize the number of experimental animals used. Although both experiments were performed in the same facilities, at the same season of the year and were carried out under the same management conditions, it cannot be completely discarded the influence of some other factors over the outcome of the infection, especially in the second experiment. On the other hand, the offspring from the same ewes and from the same flock was used in the two infections. Even though no detailed genetic analysis in relation to paratuberculosis resistance has been carried out in the lambs used in the experiment, it can be assumed that not substantial differences in the genetic background would be present among the experimental lambs.

Although bearing in mind all the considerations mentioned earlier, the most feasible hypothesis explaining the differences found in this study between the two experimental groups would be that culture in laboratory media resulted in changes in the *Map* isolate as used in the inoculum. Another possibility is that, in spite of the intense antibiotic and enzymatic

treatments to which the tissue samples were exposed during the preparation of the homogenate inoculum, the potential presence of other microbial species, which theoretically might have interacted with *Map*, could have influenced the progression of the disease (Wu *et al.*, 2007; Begg *et al.*, 2010). In this sense, it has been proposed that impaired intestinal microbial homeostasis leads to an alteration of the permeability of tissue and the activation of specific intestine immunocompetent cells, leading to micro-environmental changes that provide the substrate for outbreaks of intestinal infections (Tomasello *et al.*, 2011).

There are previous reports of different mycobacterial strains that show a loss of virulence after frequent *in vitro* passages (Rosseels and Huygen, 2008), associated with changes in the *Map* strain genotype (Bull *et al.*, 2013; Kasnitz *et al.*, 2013). Although in our study we used a low-passage inoculum, minimizing this possibility, it has been observed that the virulent factor *kdpC* gene of *Map* appears activated only in the samples directly obtained from an infected cow and not in cultured isolates (Wu *et al.*, 2007). In this sense, it is not uncommon that bacteria, in particular slow growing organisms, switch off the expression of pathogenicity genes or discard large pathogenicity plasmids, not needed for survival under *in vitro* conditions (DiRita *et al.*, 2000; Zheng *et al.*, 2008). A similar feature could have occurred in this experiment and further genetic analysis of the strains employed would be of interest. However, and not supporting this hypothesis, there is a wide range of experimental studies where a variety of cultured strains have been able to successfully reproduce the infection (Begg and Whittington, 2008; Hines II *et al.*, 2007).

It is remarkably difficult to culture S-type strains in laboratory media (Adúriz *et al.*, 1995; Whittington *et al.*, 2011) and experimental infections employing these strains have shown a variety of results, from clinically

evident (Stewart *et al.*, 2004; Begg *et al.*, 2005, 2010) or very mild (Begg *et al.*, 2005; Fernández *et al.*, 2014) infections to cases where no clear sign of infection was detected (Thorel *et al.*, 1992). It is tempting to speculate that this difficulty in isolating S-type strains in laboratory media might contribute to selection of *Map* clones better adapted to growth *in vitro* rather than maintenance of *in vivo* virulence. This particularity of S-type strains could also explain why experimental infections with other types of *Map* strains have been more successful (Juste *et al.*, 1994; Stewart *et al.*, 2004; Hines II *et al.*, 2007; Verna *et al.*, 2007; Stabel and Robbe-Austerman, 2011, Fernández *et al.*, 2014).

The presence of *Map* related lesions is considered as a good indicator of infection, since they reflect the host response to the infectious agent. The model employed in this study has already been validated for the evaluation of strain pathogenicity (Fernández *et al.*, 2014). In our study, lambs from the homogenate group showed more severe lesions, both in number of granulomata and their distribution within several areas of the LP, thus following the progression model already described for the pathogenesis of paratuberculosis (Nisbet *et al.*, 1962; Juste *et al.*, 1994; Pérez *et al.*, 1996 Kurade *et al.*, 2004; Delgado *et al.*, 2013).

Conversely, only focal and scarce lesions were observed in the culture group. The lack of clinical signs in any of the infected lambs was consistent with the lesions found, not severe enough for developing evident clinical evidence or permanent bacterial shedding (Pérez *et al.*, 1996). Focal lesions are considered as initial or latent lesions (Pérez *et al.*, 1996; Delgado *et al.*, 2013; Fernández *et al.*, 2014) and would indicate that lambs from the culture group were able to control the infection better than those from the homogenate group. It has been stated that animals infected with *Map* mount a protective cell-mediate immune response early in the infection (Stabel,

2000). In our study, however, lambs from culture group with focal lesions showed a weak and inconstant peripheral cell-mediated immune response, as seen by IDT and IGRA results. This, although likely related to the challenge, cannot be discarded to be due to environmental factors. The absence of an evident cell-mediated immune response does not exclude the possibility of lambs having controlled the infection since in the work of Vazquez *et al.* (2013), a large number of cattle with focal lesions were negative to IGRA and, what is more, local immune responses mounted against *Map* infection in the intestine, crucial in the first contact with the bacteria, do not necessarily correspond to the peripheral immune responses (Charavaryamath *et al.*, 2013). On the other hand, the marked cellular and humoral peripheral immune responses seen in lambs from the homogenate group support the hypothesis that peripheral responses are related to the extension of the lesions (Vázquez *et al.*, 2013).

The pathology results of this study emphasize the role of intestinal LT in establishment of the initial lesions associated with *Map* infection (Nisbet *et al.*, 1962; Juste *et al.*, 1994; Kurade *et al.*, 2004; Delgado *et al.*, 2013; Fernández *et al.*, 2014) and that significant differences between ileal and ileocecal/jejunal Peyer's patches occur as lesions appear in the former only when lesions are widespread. This finding could be a reflection of the functional differences described between both lymphoid tissue sites (Mutwiri *et al.*, 1999).

In spite of the extension of the lesions and the identification of AFB in the tissue sections, *Map* isolation was achieved only in 3 out of 8 lambs from the homogenate group, and always in the ICV sample. According to this result, the absence of positive cultures in tissues from the culture group was not a surprise. These findings agree with the already mentioned difficulty of culturing S-type strains (Whittington *et al.*, 2011). In contrast, infection was

confirmed by nested PCR in all the lambs from homogenate group and in three from the culture group. These results support the higher sensitivity reported for nested PCR in comparison with culture (Bull *et al.*, 2003; Delgado *et al.*, 2013) and confirm the existence of tissue infection in both groups. However, it has to be taken into account that the PCR method identifies DNA that could have originated from non-viable and/or degraded bacilli originally present in the inocula. Except for one lamb from the culture group that gave a positive PCR result, the rest of the animals also showed histological lesions, supporting the hypothesis that an infection was established but lambs were able to control *Map* infection at least during the time of the experiment.

In conclusion, this study has shown the occurrence of differences in the severity of *Map* infection, as determined by pathological, microbiological and immunological parameters, after experimental oral challenge of lambs with an inoculum derived from a tissue homogenate prepared from an ovine clinical case and the isolated *Map* strain obtained after the culture of the aforementioned inoculums in laboratory media. According to these results, marked attenuation of the virulence can occur after *in vitro* culture of the *Map* strain present in the homogenate. Thus, when experimental reproduction of ovine *Map* infection is necessary for pathogenesis, vaccine, treatment efficacy or other studies, the use of intestinal tissue homogenates as inoculum is more efficient despite the disadvantages inherent to this procedure. If these disadvantages are to be overcome, the isolation of new low-passage S-type *Map* strains with the appropriate degree of pathogenicity, although probably still lower than the tissues from which they were isolated, and capable of reproducing the disease in experimentally challenged lambs, should be recommended.

Acknowledgements

This work was supported by grants AGL2009-05820-C02 and AGL2012-39818-C02-01 from the Spanish Ministry of Economy and Competitiveness. The authors wish to thank all the staff of the IGM (CSIC-ULE) responsible for handling the experimental animals. The technical support of S. Morales is acknowledged. M. Fernandez and M. Royo are funded by a predoctoral contract from the “Junta de Castilla y León” and Spanish Ministry of Economy and Competitiveness, respectively. J. Benavides was supported by CSIC through the JAE-Doc program, financed in part by European Social Fund (ESF). The authors are in deep gratitude to Dr. M. Dagleish (Moredun Research Institute, Scotland, UK) for proof reading and constructive criticism of this work.

References

- Adúriz JJ, Juste RA, Cortabarria N (1995). Lack of mycobactin dependence of mycobacteria isolated on Midebrook 7H11 from clinical cases of ovine paratuberculosis. *Vet Microbiol.* 45:211-217.
- Begg DJ, Whittington RJ (2008). Experimental animal infection models for Johne’s disease, an infectious enteropathy caused by *Mycobacterium avium* subsp. *paratuberculosis*. *Vet Microbiol.* 176:129-145.
- Begg DJ, O’Brien R, Mackintosh CG, Griffin FT (2005). Experimental infection model for Johne’s disease in sheep. *Infect Immun.* 73:5603-5611.
- Begg DJ, de Silva K, Di Fiore L, Bower K, Zhong L, Kawaji S, Emery D, Whittington RJ (2010). Experimental infection model for Johne’s disease using a lyophilised, pure culture, seedstock of *Mycobacterium avium* subspecies *paratuberculosis*. *Vet Microbiol.* 141:301-311.
- Bull TJ, McMinn EJ, Sidi-Boumedine K, Skull A, Durkin D, Neild P, Rhodes G, Pickup R, Hermon-Taylor J (2003). Detection and verification of *Mycobacterium avium* subsp. *paratuberculosis* in fresh ileocolonic mucosal biopsy specimens from individual with and without Crohn’s disease. *J Clin Microbiol.* 41:2915-2923.
- Bull TJ, Schock A, Sharp JM, Greene M, McKendrick IJ, Sales J, Linedale R, Stevenson K (2013). Genomic variations associated with attenuation in *Mycobacterium avium* subsp. *paratuberculosis* vaccine strains. *BMC Microbiol.* 13:11.
- Charavaryamath C, Gonzalez-Cano P, Fries P, Gomis S, Doig K, Scruten E, Potter A, Napper S, Griebel PJ (2013). Host responses to persistent *Mycobacterium avium* subspecies *paratuberculosis* infection in surgically isolated bovine ileal segments. *Clin Vaccine Immunol.* 20:156-165.
- Collins DM, Gabric DM, de Lisle GW (1990). Identification of two groups of *Mycobacterium paratuberculosis* strains by restriction analysis and DNA hybridization. *J Clin Microbiol.* 28:1591-1596.
- Delgado L, García-Marín JF, Muñoz M, Benavides J, Juste RA, García-Pariente C, Fuertes M, González J, Ferreras MC, Pérez V (2013). Pathological findings in young and adult sheep following

- experimental infection with 2 different doses of *Mycobacterium avium* subspecies *paratuberculosis*. *Vet Pathol.* 50: 857-866.
- DiRita VJ, Engleberg NC, Heath A, Miller A, Crawford JA, Yu R (2000). Virulence gene regulation inside and outside. *Philos Trans R Soc Lond B Biol Sci.* 355:657-665.
- Fernández M, Benavides J, Sevilla IA, Fuertes M, Castaño P, Delgado L, García- Marín JF, Garrido JM, Ferreras MC, Pérez V (2014). Experimental infection of lambs with C and S-type strains of *Mycobacterium avium* subspecies *paratuberculosis*: immunological and pathological findings. *Vet Res.* 45:5.
- Garrido JM, Cortabarría N, Oguiza JA, Adúriz G, Juste RA (2000). Use of a PCR method on fecal samples for diagnosis of sheep paratuberculosis. *Vet Microbiol.* 77:379-386.
- Hines II ME, Stabel JR, Sweeney RW, Griffin F, Talaat AM, Bakker D, Benedictus G, Davis WC, de Lisle GW, Gardner IA, Juste RA, Kapur V, Koets A, McNair J, Pruitt G, Whitlock RH (2007). Experimental challenge models for Johne's disease: a review and proposed international guidelines. *Vet Microbiol.* 122:197-222.
- Hughes JB, Hellmann JJ, Ricketts TH, Bohannon BJ (2001). Counting the uncountable: statistical approaches to estimating microbial diversity. *Appl Environ Microbiol.* 67:4399-4406.
- Juste RA (2012). Slow infection control by vaccination: paratuberculosis. *Vet Immunol Immunopathol.* 148:190-196.
- Juste RA, Garcia-Marín JF, Peris B, Sáez de Ocáriz CS, Badiola JJ (1994). Experimental infection of vaccinated and non-vaccinated lambs with *Mycobacterium paratuberculosis*. *J Comp Pathol.* 110:185-194.
- Kasnitz N, Köhler H, Weigoldt M, Gerlach GF, Möbius P (2013). Stability of genotyping target sequences of *Mycobacterium avium* subsp. *paratuberculosis* upon cultivation on different media, *in vitro*- and *in vivo* passage, and natural infection. *Vet Microbiol.* 167:573-583.
- Kurade NP, Tripathi BN, Rajukumar K, Parihar NS (2004). Sequential development of histologic lesions and their relationship with bacterial isolation, fecal shedding and immune responses during progressive stages of experimental infection of lambs with *Mycobacterium avium* subsp. *paratuberculosis*. *Vet Pathol.* 41:378-387.
- McGregor H, Dhand NK, Dhungyel OP, Whittington RJ (2012). Transmission of *Mycobacterium avium* subsp. *paratuberculosis*: dose-response and age-based susceptibility in a sheep model. *Prev Vet Med.* 107:76-84.
- Mutwiri G, Watts T, Lew L, Beskorwayne T, Papp Z, Baca-Estrada ME, Griebel P (1999). Ileal and jejunal Peyer's patches play distinct roles in mucosal immunity of sheep. *Immunology.* 97:455-461.
- Nisbet DI, Gilmour NJL, Brotherston JG (1962). Quantitative studies of *Mycobacterium johnei* in tissues of sheep: III. Intestinal histopathology. *J Comp Pathol.* 72:80-91.
- Pérez V, García-Marín JF, Badiola JJ (1996). Description and classification of different types of lesion associated with natural paratuberculosis infection in sheep. *J Comp Pathol.* 114:107-122.
- Pérez V, Tellechea J, Corpa JM, Gutiérrez M, García Marín JF (1999). Relation between pathologic findings and cellular immune responses in sheep with naturally acquired paratuberculosis. *Am J Vet Res.* 60:123-127.
- Ratnamohan TN, Spencer TL (1986). A technique for the purification of *Mycobacterium paratuberculosis* from the ileal mucosa of infected cattle. *Aust Vet J.* 63:185-187.

- Reddacliff LA, Whittington RJ (2003). Experimental infection of weaner sheep with S strain *Mycobacterium avium* subsp. *paratuberculosis*. *Vet Microbiol.* 96:247-258.
- Rosseels V, Huygen K (2008). Vaccination against paratuberculosis. *Expert Rev Vaccines.* 7:817-832.
- Sevilla IA, Singh SV, Garrido JM, Adúriz G, Rodríguez S, Geijo MV, Whittington RJ, Saunders V, Whitlock RH, Juste RA (2005). Molecular typing of *Mycobacterium avium* subspecies *paratuberculosis* strains from different hosts and regions. *Rev Sci Tech.* 24:1061-1066.
- Sevilla IA, Garrido JM, Geijo MV, Juste RA (2007). Pulse-field gel electrophoresis profile homogeneity of *Mycobacterium avium* subsp. *paratuberculosis* isolates from cattle and heterogeneity of those from sheep and goats. *BMC Microbiol.* 7:18.
- Stabel JR (2000). Transitions in immune responses to *Mycobacterium avium paratuberculosis*. *Vet Microbiol.* 77:465-473.
- Stabel JR, Robbe-Austerman S (2011). Early immune markers associated with *Mycobacterium avium* subsp. *paratuberculosis* infection in a neonatal calf model. *Clin Vaccine Immunol.* 18:393-405.
- Stevenson K, Hughes VM, de Juan L, Inglis NF, Wright F, Sharp JM (2002). Molecular characterization of pigmented and non pigmented isolates of *Mycobacterium avium* subsp. *paratuberculosis*. *J Clin Microbiol.* 40:1798-1804.
- Stewart DJ, Vaughan JA, Stiles PL, Noske PJ, Tizard ML, Prowse SJ, Michalski WP, Butler KL, Jones SL (2004). A long-term study in Merino sheep experimentally infected with *Mycobacterium avium* subsp. *paratuberculosis*. Clinical disease, faecal culture and immunological studies. *Vet Microbiol.* 104:165-178.
- Thorel MF, Vialard J, Manfroni F, Bernardot J, Ostyn A, Vancevelde J (1992). Paratuberculose experimentale chez le mouton apres inoculation par voie veineuse ou par voie orale: pouvoir pathogene et diagnostic biologique. *Ann Rech Vet.* 23:105-115.
- Tomasello G, Bellavia M, Palumbo VD, Gioviale MC, Damiani P, Lo Monte AI (2011). From gut microflora imbalance to mycobacteria infection: is there a relationship with chronic intestinal inflammatory diseases? *Ann Ital Chir.* 82:361-368.
- Vázquez P, Garrido JM, Juste RA (2013). Specific antibody and interferon-gamma responses associated with immunopathological forms of bovine paratuberculosis in slaughtered Friesian cattle. *PLoS One.* 8:e64568.
- Verna AE, García-Pariente C, Muñoz M, Moreno O, García-Marin JF, Romano MI, Paolicchi F, Pérez V (2007). Variations in the immunopathological responses of lambs after experimental infection with different strains of *Mycobacterium avium* subsp. *paratuberculosis*. *Zoonoses Public Health.* 54: 243-252.
- Whittington RJ, Marsh IB, Saunders V, Grant IR, Juste R, Sevilla IA, Manning EJ, Whitlock RH (2011). Culture phenotypes of genomically and geographically diverse *Mycobacterium avium* subsp. *paratuberculosis* isolates from different hosts. *J Clin Microbiol.* 49:1822-1830.
- Wu C, Schmoller SK, Shin SJ, Talaat AM (2007). Defining the stressome of *Mycobacterium avium* subsp. *paratuberculosis* in vitro and in naturally infected cows. *J Bacteriol.* 189:7877-7886.
- Zheng H, Lu L, Wang B, Pu S, Zhang X, Zhu G, Shi W, Zhang L, Wang H, Wang S, Zhao G, Zhang Y (2008). Genetic basis of virulence attenuation revealed by comparative genomic analysis of *Mycobacterium tuberculosis* strain H37Ra versus H37Rv. *PLoS One.* 3:e2375.

4.3. TERCER ESTUDIO

THIRD STUDY



Factor de impacto 2,120

Veterinary Sciences 13/133

4.3. Macrophage subsets within granulomatous intestinal lesions in bovine paratuberculosis

Miguel Fernández¹, Julio Benavides¹, Pablo Castaño¹, Natalia Elguezabal², Miguel Fuertes¹, María Muñoz¹, M. Royo¹, M. Carmen Ferreras¹, and Valentín Pérez^{1*}

¹Departamento de Sanidad Animal, Instituto de Ganadería de Montaña (CSIC-ULE), Facultad de Veterinaria, Universidad de León, Campus de Vegazana s/n, León 24071, Spain.

²Departamento de Sanidad Animal, NEIKER-Tecnalia, Berreaga 1, Derio, Bizkaia 48160, Spain.

* Corresponding author: Valentín Pérez (vperp@unileon.es)

Received: 21 December 2015

Published: 17 June 2016

Abstract

Animals infected with *Mycobacterium avium* subspecies *paratuberculosis* show a variety of granulomatous lesions that range from focal forms, seen in the subclinical stages, to diffuse lesions associated with clinical signs. The aim of this study was to phenotypically characterize the macrophages present in the different lesion types using immunohistochemical methods. Lesions from a total of 23 animals with bovine paratuberculosis, natural and experimental, were examined by immunohistochemistry. Antibodies against inducible nitric oxide synthase (iNOS), tumor necrosis factor α (TNF- α), CD163, interleukin 10 (IL-10), transforming growth factor β (TGF- β), major histocompatibility complex (MHC) class II, natural resistance associated macrophage protein 1 (Nramp-1),

calprotectin, Ki-67, CD68, lysozyme, and ionized calcium-binding adaptor molecule 1 (Iba-1) molecules were employed. Samples were scored semiquantitatively using a complete histological score (H-score), reflecting the staining intensity and the percentage of immunolabeled macrophages. Differences in the H-score were seen depending on the lesion type. In focal lesions, with none or few acid-fast bacilli (AFB), macrophages were polarized toward M1 phenotype, with high H-scores for iNOS and TNF- α . Diffuse multibacillary lesions showed M2 differentiation, with high expression of CD163, IL-10, and TGF- β as well as Nramp-1 and MHC class II antigens. Macrophages in diffuse paucibacillary forms showed high H-scores for iNOS but low ones for TNF- α . Diffuse lesions, either multibacillary or paucibacillary, showed high calprotectin and low Ki-67 expression, suggesting a progressive character, while focal forms, with low H-scores for these antigens, would be consistent with latency. Lysozyme and CD68 expression were related to the amount of AFB. H-score for Iba-1 antibody was similar among all types. The findings of this study provide insights into the polarization status of macrophages and lesion development in bovine paratuberculosis.

4.3.1. Introduction

Paratuberculosis or Johne's disease is a chronic infection of domestic and wild ruminants caused by *Mycobacterium avium* subspecies *paratuberculosis* (*Map*). It is distributed worldwide and causes important economic losses to domestic livestock associated with chronic diarrhea and progressive loss of body condition (Harris and Barletta, 2001). Despite its relevance, the pathogenesis of paratuberculosis is still poorly understood. Although transplacental infection or excretion of *Map* in the milk or colostrum has been demonstrated, the ingestion of *Map* containing feces by young animals is the most important transmission route (Harris and Barletta, 2001). As a consequence, infected animals can show different outcomes such

as resistance to infection, development of latent infections that can last for an entire lifetime, or clinical disease that will appear only in the adulthood (Harris and Barletta, 2001; Whittington *et al.*, 2012).

In *Map*-infected animals, a variety of granulomatous lesions can be detected, which have been classified according to the intensity, location, cellular types, and number of acid-fast bacilli (AFB) (Buergelt *et al.*, 1978; Pérez *et al.*, 1996; González *et al.*, 2005). Although slight differences are observed between species, 4 main types of lesions have been recognized, which are associated with different stages of the disease: focal forms, composed of small, well-demarcated granulomas located exclusively in the intestinal lymphoid tissue or lymph nodes, have been related to the initial phases of infection or to latent stages in adult animals (González *et al.*, 2005; Delgado *et al.*, 2013). Multifocal forms, seen in subclinically infected animals, are characterized by the presence of small granulomas in the lymphoid tissue and also in the lamina propria either related to or not related to the Peyer's patches; the normal histological architecture of the intestine is not substantially modified (González *et al.*, 2005; Delgado *et al.*, 2013).

Animals with clinical signs usually show diffuse lesions, characterized by a widespread granulomatous enteritis, affecting both the lymphoid tissue and lamina propria causing the thickening of the intestinal wall (Buergelt *et al.*, 1978; Pérez *et al.*, 1996; González *et al.*, 2005). According to the cell types and amount of AFB, they have been classified as multibacillary/histiocytic forms, where epithelioid cells harboring large amounts of AFB are the main component, and as paucibacillary/lymphocytic lesions that are characterized by a diffuse infiltrate of lymphocytes in the lamina propria, with scattered granulomas formed by macrophages and giant cells containing none or low numbers of AFB (Pérez *et al.*, 1996; González *et al.*, 2005).

The factors responsible for the development of the different pathological responses remain unclear. A relation between the immune response developed by the host and the type of lesion has been reported (Pérez *et al.*, 1997; Vázquez *et al.*, 2013). Focal, multifocal, or diffuse paucibacillary lesions have been associated with high peripheral cellular immune responses, while in those animals with multibacillary lesions, a humoral response is predominant. However, in some cases, this polarization of forms is not so clearly defined (Whittington *et al.*, 2012; Vázquez *et al.*, 2013; Fernández *et al.*, 2014).

Map infection occurs mainly through M cells of the Peyer's patches and, to a lesser extent, through differentiated epithelial cells (Sigurdardóttir *et al.*, 2004). After penetrating the intestinal epithelial barrier, *Map* invades the subepithelial macrophages that play a crucial role in the host–pathogen interaction (Sigurdardóttir *et al.*, 2004). Granulomatous lesions, composed mainly of macrophages, are the hallmark of paratuberculosis, constituting a complex environment where mycobacteria can inhibit the maturation and acidification of phagosomes and transform the potentially hostile macrophages into protected havens assuring their replication (Sigurdardóttir *et al.*, 2004; Valheim *et al.*, 2004). There is still a lack of information regarding macrophage function or diversity within the granuloma in paratuberculosis. In addition, why some granulomas control bacterial growth while others permit it remains unknown. As a reflection of the complexity of these interactions, the existence of different myeloid cell populations that can interact with antigens and participate in the local immune response has been described in the intestine of cattle, with differences related to age or intestinal location (Fries *et al.*, 2011).

A common feature across different species is that macrophages are characterized by a remarkable diversity and plasticity and can acquire distinct

functional phenotypes depending on polarization status (Mills *et al.*, 2000; Sica and Mantovani, 2012; Davies, 2013; Martínez and Gordon, 2014). Traditionally, it has been considered that, in response to different signals, macrophages can be differentiated into 2 main types (Sica and Mantovani, 2012; Martínez and Gordon, 2014): M1 or classically activated which are characterized by a proinflammatory response and promotion of Th1 responses, and M2 or alternatively activated which are considered to have immunoregulatory functions involved in parasite containment and promotion of tissue remodeling. M1 macrophages are mainly activated by interferon gamma (IFN- γ), whereas M2 cells are activated by interleukin (IL) 4 or IL-10. They can be distinguished by the differential expression of diverse markers, such as inducible nitric oxide synthase (iNOS) or tumor necrosis factor α (TNF- α) for M1 macrophages or CD163, IL-10, or transforming growth factor β (TGF- β) for M2 macrophages (Mantovani *et al.*, 2004; Barros *et al.*, 2013; Martínez and Gordon, 2014). Pathology of different diseases has been associated with dynamic changes in macrophage activation (Benoit *et al.*, 2008; Lugo-Villarino *et al.*, 2011; Sica and Mantovani, 2012; Ka *et al.*, 2014; Huang *et al.*, 2015; Marino *et al.*, 2015).

Most of the information regarding M1 and M2 polarization have been obtained from in vitro studies involving cultured macrophages (Mills *et al.*, 2000; Ka *et al.*, 2014; Huang *et al.*, 2015) that probably do not correlate with the complexity of the immune responses and the environment that take place in the in vivo developed granulomas (Valheim *et al.*, 2004; Davies, 2013). The study of macrophage polarization associated with lesion types has been assessed through the immunohistochemical labeling of different markers associated with M1 and M2 polarization in different diseases (Barros *et al.*, 2013; Ka *et al.*, 2014; Huang *et al.*, 2015; Marino *et al.*, 2015).

Concerning mycobacterial infections in human tuberculosis, it has been shown that M1 macrophages are associated with early stages of infection where they promote the formation of tuberculous granulomas and a protective response, while M2 macrophages are more typically associated with an advanced stage of the disease where host responses are less effective in controlling infection (Huang *et al.*, 2015; Marino *et al.*, 2015). In paratuberculosis, a recent study on blood monocytes from subclinically infected cattle has detected a heterogeneous macrophage activation pattern characterized by both classical and alternative phenotypes (Thirunavukkarasu *et al.*, 2015).

The main objective of this study was to carry out the phenotypical characterization of the macrophages present within the different granulomatous lesions associated with Map infection through immunohistochemical labeling of different markers related to macrophage biology. Particularly, the existence of different polarization status among the macrophages in the lesions was also evaluated.

4.3.2. Materials and Methods

Animals

A total of 23 female cattle were used in the study. Eight of them were calves experimentally infected with Map for other purposes (Muñoz *et al.*, 2006). Briefly, 4-month-old calves were orally challenged with a total dose of 6×10^{10} bacilli obtained directly from the intestinal mucosa of a clinically affected cow, which were purified and administered in 6 different doses given every 2 days. Two calves were culled at 120 days postinfection (dpi), and the remaining 6 animals at 270 dpi. Two additional uninfected, control cattle culled at 270 dpi were also examined as negative controls. All the animals were sedated with xylazine (Rompun®; Bayer, Mannheim, Germany) and

immediately euthanized by an intravenous overdose of embutramide and mebezonium iodide (T61®; Intervet, Salamanca, Spain). The remaining 15 animals were naturally *Map*-infected cows that had been killed in a slaughterhouse by standard authorized methods. They were unvaccinated Holstein cows coming from 2 different herds in whom a follow-up study on losses due to paratuberculosis was ongoing. Infection was confirmed by bacteriological culture of frozen tissues (González *et al.*, 2005), serum indirect enzyme-linked immunosorbent assay (Muñoz *et al.*, 2009; Fernández *et al.*, 2014) and IFN- γ release test (Muñoz *et al.*, 2009; Fernández *et al.*, 2014), following the methodology detailed in the referred articles. Complete information on the animals and the results of the different tests are provided in Supplemental Table 1. The experimental procedures carried out in this study were performed in accordance with Spanish Royal Decree 1201/2005 for the protection of animals used for experimental and other scientific purposes and were approved by the “Instituto de Ganadería de Montaña CSIC-ULE” Animal Ethics Committee (Ref LE-B-12).

Tissue Samples

After necropsy or at the slaughterhouse, at least one sample from different areas of the intestine (ileocecal valve; distal, middle, or proximal ileum; and jejunum [with and without Peyer’s patches]; duodenum; and large intestine—including cecum, colon, and rectum) and ileocecal, ileal, and jejunal mesenteric lymph nodes was taken from each animal for histopathological examination. All samples were fixed in 10% buffered formalin for less than 48 hours and subsequently dehydrated through a graded alcohol series before being embedded in paraffin wax. Sections, 3.5 μm thick, were stained with hematoxylin and eosin and Ziehl-Neelsen method for AFB identification. A subjective classification of the sections was made according to the amount of AFB present, from 0 (no detectable bacilli), 1

(scant AFB in the cytoplasm of macrophages), 2 (moderate, easily detectable bacilli), to 3 (high load of AFB). Detailed information on the lesion type and AFB category present in each examined sample are provided in Supplemental Table 1. Granulomatous lesions were detected in different small intestine and lymph node samples. Only in 1 case, granulomas were seen in the cecum (Supplemental Table 1). Control cattle did not show any lesion consistent with Map infection.

Classification of Lesions

Lesions associated with Map infection were classified into 4 categories, according to the guidelines provided by González *et al.* (2005) focal, multifocal, diffuse multibacillary, and diffuse paucibacillary. Each animal was classified based on the most severe lesion found in the examined samples, bearing in mind that the type of lesion could vary among the tissue samples obtained from the same individual (Supplemental Table 1).

Focal lesions were characterized by small, well-demarcated granulomas composed of 5–50 macrophages located exclusively in the interfollicular areas of the intestinal lymphoid tissue of the ileocecal valve or the isolated jejuna Peyer's patches. They were also detected in the paracortical area of the lymph nodes. Acid-fast bacilli were absent or detected in very low amounts in the cytoplasm of the macrophages (category 0 or 1).

Three experimentally infected calves and 2 naturally infected cows were classified as having focal lesions. In these animals, intestinal sections from 2 locations (ileocecal valve and jejunal Peyer's patches) presented this type of lesion (Supplemental Table 1).

Sections containing multifocal lesions presented focal granulomas in the lymphoid tissue, as well as small and well-demarcated granulomas,

formed by 5–25 macrophages and giant cells in the intestinal lamina propria related to the Peyer's patches or in the lamina propria of villi not related to the lymphoid tissue. Granulomas were scanty and did not substantially modify the normal intestinal mucosa architecture. As in focal lesions, AFB were not detected or present in very low amounts (score 0-1).

A total of 6 animals (3 experimentally challenged calves and 3 adult cows) were classified under this category. In this group, this lesion was detected in 24 tissue sections of the intestine (Supplemental Table 1).

Diffuse lesions were characterized by the presence of a widespread granulomatous lymphadenitis and enteritis that altered significantly the normal intestinal architecture. The lesion was present in areas of the intestine both with and without lymphoid tissue. Large numbers of macrophages and occasional giant cells appeared in the interfollicular areas, infiltrating the lymphoid follicles. The lamina propria was markedly thickened and distended due to the presence of inflammatory cells. According to the cellular types and number of AFB, 2 types of diffuse forms were considered: diffuse multibacillary lesions, characterized by the predominance of macrophages morphologically consistent with epithelioid cells harboring large numbers of AFB (category 2 or more frequently 3) and diffuse paucibacillary lesions, wherein the infiltrate was composed mainly of lymphocytes, with some macrophages and giant cells, with occasional AFB (score 1) located among them.

Diffuse multibacillary lesions were identified in six animals (1 experimentally infected and 5 naturally infected) and diffuse paucibacillary forms in another six (5 naturally and 1 experimentally infected cattle). Concerning tissue samples, diffuse multibacillary forms were identified in 30 intestine sections and diffuse paucibacillary forms in 29 samples (Supplemental Table 1). In all 12 cattle with diffuse lesions, grossly visible

thickening of the intestinal wall of the ileum and jejunum and enlargement of the regional lymph nodes were seen in different degrees.

Immunohistochemistry

Immunohistochemical studies were performed in a total of 23 intestinal sections from different animals (Supplemental Table 1), showing the 4 main types of lesions considered (6 different samples from each lesion, except for the focal lesions where 5 samples were examined). Focal lesions were evaluated in sections obtained from the jejunal Peyer's patches, whereas multifocal, diffuse multibacillary, and diffuse paucibacillary lesions were evaluated in tissue sections obtained from the middle ileum.

Different primary antibodies raised against antigens expressed by macrophages, including M1 and M2 subpopulations, and proliferation markers were used (Supplemental Table 2). Immunohistochemistry was performed using the Envision+ System (Dako, Agilent Technologies, Glostrup, Denmark) in 3.5- μ m-thick tissue sections that were placed onto poly-L-lysine-coated slides. After deparaffinization and hydration, endogenous peroxidase was blocked by immersion of the sections into a 3 % H₂O₂ in methanol solution for 30 minutes in dark at room temperature. Rehydrated slides were rinsed twice in phosphate-buffered saline (PBS) of pH 7.4, and antigen retrieval methods using enzymatic or heat-based protocols, depending on the primary antibody, were used to optimize the immunoreaction as specified in Supplemental Table 2. Sections were incubated with the primary antibodies diluted in PBS (Supplemental Table 2) overnight at 4 °C in a humidified chamber. After washing in PBS, sections were incubated for 40 minutes at room temperature with EnVision+ horseradish peroxidase (HRP) solution (Dako, Agilent technologies) for the appropriate monoclonal or polyclonal antibodies. After washing in PBS, antibody localization was determined using 3,3-diaminobenzidine (Sigma-Aldrich Corp., Madrid, Spain) as chromogenic

substrate for peroxidase. Sections were counterstained with Mayer's hematoxylin for 10 seconds. Appropriate species- and isotype-matched immunoglobulins were used as negative controls. As positive controls, the same examined sections were used.

All the antibodies were tested in the 23 selected intestinal sections. A single antigen was examined per section. From each intestinal sample, serial sections were used for the sequential immunostaining of the antigens.

Statistical Analysis

Immunohistochemical data (H-score) were analyzed for normality of distribution using Shapiro-Wilk and Kolmogorov-Smirnov tests. As data were not normally distributed and logarithmic transformation failed to correct skewness, they were analyzed with nonparametric methods of statistical analysis. The Kruskal-Wallis test was used to compare groups of lesions (focal, multifocal, diffuse multibacillary, and diffuse paucibacillary) for each antibody. The Mann-Whitney test was applied for post hoc comparison when significant differences were observed. A $P < 0.05$ was considered to indicate statistical significance. Correlation between AFB category and H-scores for the different antibodies was evaluated using Spearman test. All statistical analyses were performed with the use of statistical software SPSS version 21.0 (IBM Corp., Armonk, New York).

Supplemental table 1: Details on the Origin, Age, Lesion Category and Distribution in the Different Tissue Samples, PCR, Culture and Immunological Test Results of the Animals Included in the Study.

ID	Age	Lesion type	ICV		dIL		mIL		pIL		JPP		dJ		mJ		pJ		ILn		JLn		LI		Tissue culture			ELISA	Ifn				
			L	A	L	A	L	A	L	A	L	A	L	A	L	A	L	A	L	A	L	A	L	A	IL	J	Ln						
1E	0.75	F	F	0	0	0	0	0	0	0	0	F*	1	0	0	0	0	0	0	+	0	+	0	0	0	0	-	+	+	-	+		
2E	0.75	F	F	1	0	0	0	0	0	0	0	F*	0	0	0	0	0	0	0	+	0	0	0	0	0	0	-	-	+	-	+		
3E	0.75	F	0	0	0	0	0	0	0	0	0	F*	1	0	0	0	0	0	0	0	0	+	0	0	0	-	+	-	-	-	+		
4N	2	F	F	1	0	0	0	0	0	0	0	F*	0	0	0	0	0	0	0	0	0	+	0	0	0	+	-	-	-	-	+		
5N	2.5	F	0	0	0	0	0	0	0	0	0	F*	0	0	0	0	0	0	0	+	0	0	0	0	0	-	+	-	-	-	+		
6E	1.2	MF	F	0	0	1	MF*	1	MF	0	MF	1	0	0	0	0	0	0	+	1	+	0	0	0	0	+	-	-	-	-	+		
7E	1.2	MF	0	0	MF	0	MF*	0	MF	0	F	0	MF	1	MF	0	0	0	+	0	0	0	0	0	0	-	+	-	-	-	+		
8E	1.2	MF	MF	1	0	0	MF*	1	0	0	MF	1	0	0	MF	0	0	0	+	1	+	0	0	0	0	+	+	+	-	-	+		
9N	4	MF	F	0	MF	0	MF*	1	MF	0	MF	1	MF	0	MF	1	0	0	0	0	0	+	0	0	0	-	+	+	-	+	+		
10N	2.75	MF	F	1	0	0	MF*	1	MF	0	0	1	F	0	0	0	0	0	+	0	0	0	0	0	0	+	-	-	-	-	+		
11N	3.5	MF	0	0	MF	0	MF*	0	0	0	MF	0	0	0	MF	0	0	0	0	0	0	0	0	0	0	-	+	-	-	+	+		
12E	1.2	MB	MB	0	MF	2	MB*	3	MF	2	MB	3	MB	3	MB	2	MF	2	+	2	+	2	0	0	0	+	+	+	+	+	-	+	
13N	2.75	MB	MF	2	MF	3	MB*	3	MB	3	MB	2	MB	3	MB	2	MF	2	+	1	+	2	0	0	0	+	+	+	+	+	+	+	
14N	2.5	MB	F	2	MB	3	MB*	3	MF	2	MB	3	MF	2	MB	3	MB	2	+	2	+	1	0	0	0	+	+	+	+	+	+	+	
15N	3.5	MB	MB	2	MF	2	MB*	2	MF	2	MB	3	MB	3	MB	3	MB	2	+	1	+	1	+	0	0	+	+	+	+	+	+	-	+
16N	5	MB	MF	2	MB	3	MB*	3	MB	3	MF	2	MB	3	MF	2	MF	2	+	1	+	1	0	0	0	+	+	+	+	+	+	+	+
17N	3.7	MB	MF	2	MB	3	MB*	3	MF	3	MB	3	MF	3	MB	3	MB	3	+	2	+	2	0	0	0	+	+	+	+	+	+	+	+
18E	1.2	PB	MF	1	MF	0	PB*	1	PB	1	PB	1	MF	1	0	0	0	0	+	1	-	1	0	0	0	+	+	+	+	-	-	+	+
19N	3.2	PB	F	0	PB	1	PB*	1	MF	1	PB	0	PB	1	PB	0	MF	0	+	1	+	0	0	0	0	+	+	+	+	+	+	+	+
20N	2.5	PB	F	1	PB	1	PB*	1	PB	1	PB	0	PB	1	PB	1	MF	1	0	0	+	1	0	0	0	+	+	+	-	-	-	+	+
21N	3.5	PB	MF	0	PB	1	PB*	1	PB	1	PB	1	PB	0	PB	1	PB	1	+	1	+	1	0	0	0	+	+	+	-	-	-	+	+
22N	4	PB	F	1	MF	1	PB*	1	PB	1	PB	1	PB	1	PB	1	0	0	+	0	+	0	0	0	0	+	+	+	-	-	-	+	+
23N	2.7	PB	MF	1	PB	1	PB*	1	MF	0	PB	1	MF	0	MF	1	0	0	+	1	+	0	0	0	0	+	+	+	+	+	+	+	+

Abbreviations: E, experimental; N, natural; 0, no lesion; F, focal; MF, multifocal; MB, diffuse multibacillary; PB, diffuse paucibacillary; 0, no lesion; ICV, ileocaecal valve; d, distal; m, medium; p, proximal; IL, ileum; JPP, jejunal Peyer’s patches; J, jejunum; ILn, ileocaecal-ileal lymph nodes; JLn, jejunal lymph nodes; LI, large intestine (caecum, colon, rectum); Ln, ileal, jejunal lymph nodes; L, lesion type; A, acid-fast bacilli category (0 to 3) assessed by Ziehl-Neelsen; +, positive; -, negative. Ifn: interferon-γ release assay. *Samples chosen for the immunohistochemical characterization of macrophages in this study.

Supplemental Table 2. Details of the primary antibodies and procedures used for the immunohistochemical examination of macrophages.

Target	Specificity (clone)	Source	Epitope demasking	Dilution
Murine iNOS	Inducible nitric oxide synthase (Rabbit polyclonal). M1 marker.	Millipore	Heat mediated Antigen Retrieval (AR) EDTA buffer, pH 9.0, 20 min	1:1000
Bovine TNF- α	Tumor necrosis factor- α (Clone CC327). M1 marker	Serotec	Heat mediated AR Citrate buffer, pH 6.0, 20 min	1:200
Human CD163	Tissue macrophages (Clone EDHu-1). M2 marker	Serotec	Heat mediated AR Citrate buffer, pH 6.0, 20 min	1:200
Human IL-10	Interleukin-10 (Rabbit polyclonal). M2 marker	Biorbyt	Heat mediated AR Citrate buffer, pH 6.0, 20 min	1:300
Human TGF- β	Transforming growth factor- β (Rabbit polyclonal). M2 marker	Santa Cruz	Microwave-mediated AR Citrate buffer, pH 6.0, 20 min	1:1000
Ovine MHC class II	Antigen-presenting cells (Clone VPM36)	Serotec	None	1:100
Human Nramp-1	Natural resistance associated macrophage protein 1 (Rabbit polyclonal)	Santa Cruz	Trypsin 0.1%, 15 min	1:50
Human myeloid/histiocyte antigen	Calprotectin (Clone MAC 387)	Dako	Protease 0.1%, 20 min	1:100
Human Ki-67 antigen	Proliferating cells (Clone MIB-1)	Dako	Heat mediated AR Citrate buffer, pH 6.0, 20 min	1:75
Human CD68	Monocytes and macrophages (Clone KP-1)	Dako	Trypsin 0.1%, 40 min	1:100
Human lysozyme	Lysozyme (Rabbit polyclonal)	Dako	Proteinase K 0.2%, 20 min	1:200
Iba-1	Macrophages (Rabbit polyclonal)	Wako	Heat mediated AR Citrate buffer, pH 6.0	1:2000

4.3.3. Results

Macrophages present in the 4 types of lesions considered were immunolabeled with the 12 tested antibodies showing differences in the intensity of the signal and the number of immunolabeled cells. Figure 1 shows the mean of the H-score obtained for each antibody according to the lesion category. Images corresponding to the patterns of immunostaining for the different antibodies and the main types of lesion are shown in Figs. 2-14 (focal), Figs. 15-27 (diffuse multibacillary), and Supplemental Figs. 1-13 (diffuse paucibacillary). Histological score values for iNOS were significantly higher in focal lesions than in diffuse multibacillary ($P < 0.001$) or multifocal and diffuse paucibacillary forms ($P < 0.05$). No differences were observed between the last 2, both of them showing higher values than diffuse multibacillary forms. The lowest H-score values for this marker were found in diffuse multibacillary lesions. Expression of TNF- α was higher in focal and multifocal forms ($P < 0.05$) than in diffuse multibacillary or paucibacillary lesions, showing no differences between them.

The highest H-score values for CD163 and IL-10 antibodies were obtained in diffuse multibacillary lesions, with significant differences compared to the rest of the lesion types ($P < 0.001$). High H-scores were also obtained for TGF- β immunolabeling, although in this case differences were also observed between focal and multifocal and diffuse paucibacillary type lesions ($P < 0.05$).

Immunohistochemical expression of MHC class II antigen, associated with antigen-presenting cells, was significantly higher in diffuse multibacillary lesions than in the rest of the forms ($P < 0.001$), where significant differences were not observed. Expression of natural resistance-associated macrophage protein 1 (Nramp-1) was higher in diffuse multibacillary lesions than in the rest of forms ($P < 0.001$) exhibiting similar H-score values.

The intensity of immunostaining for calprotectin antibody was significantly lower in focal and multifocal forms than in diffuse lesions ($P < 0.001$), with no differences between both diffuse types. Histological scores for immunodetection of Ki-67 antigen, which marks nuclear proteins expressed in cells that are proliferating, were significantly lower in both types of diffuse lesions, that is, focal and multifocal forms ($P < 0.001$) that rendered the highest values. CD68 and lysozyme antibody immunolabeling rated the highest H-score values in multifocal and diffuse multibacillary lesions in relation to focal and diffuse paucibacillary forms ($P < 0.05$) that showed similar levels. For ionized calcium binding adaptor molecule 1 (Iba-1) antibody, no significant differences in the H-score values were observed among the different types of lesions.

Antibody immunolabeling according to the type of lesion

Focal lesions showed high H-score values for iNOS, TNF- α , and Ki-67 antibodies, as observed in Figs. 1 and 2. A similar pattern was observed in multifocal lesions except for the immunolabeling of TGF- β , CD68, and lysozyme, which was higher. Diffuse multibacillary lesions showed high H-score values for CD163, IL-10, TGF- β , lysozyme, CD68, calprotectin, Nramp-1, and MHC class II antibodies, whereas iNOS and TNF- α immunolabeling was significantly lower. Diffuse paucibacillary lesion immunolabeling profiles were also similar to those of focal forms, except for the immunolabeling of TNF- α , calprotectin, and Ki-67 antibodies which showed a pattern similar to that presented by the diffuse multibacillary forms. High H-score values were observed for Iba-1 antibody in the 4 types of lesions, with no differences between them.

Correlation between AFB category and H-Scores for the different antibodies

The amount of AFB present in the lesions was directly correlated with the H-score for the different antibodies used, with a variable statistical significance (between $P < 0.05$ and $P < 0.0001$) depending on the marker used (Supplemental Fig. 14). Histological scores for iNOS, TNF- α , and Ki-67 were negatively correlated with the amount of AFB, whereas a positive correlation was confirmed with the H-scores for the rest of the markers.

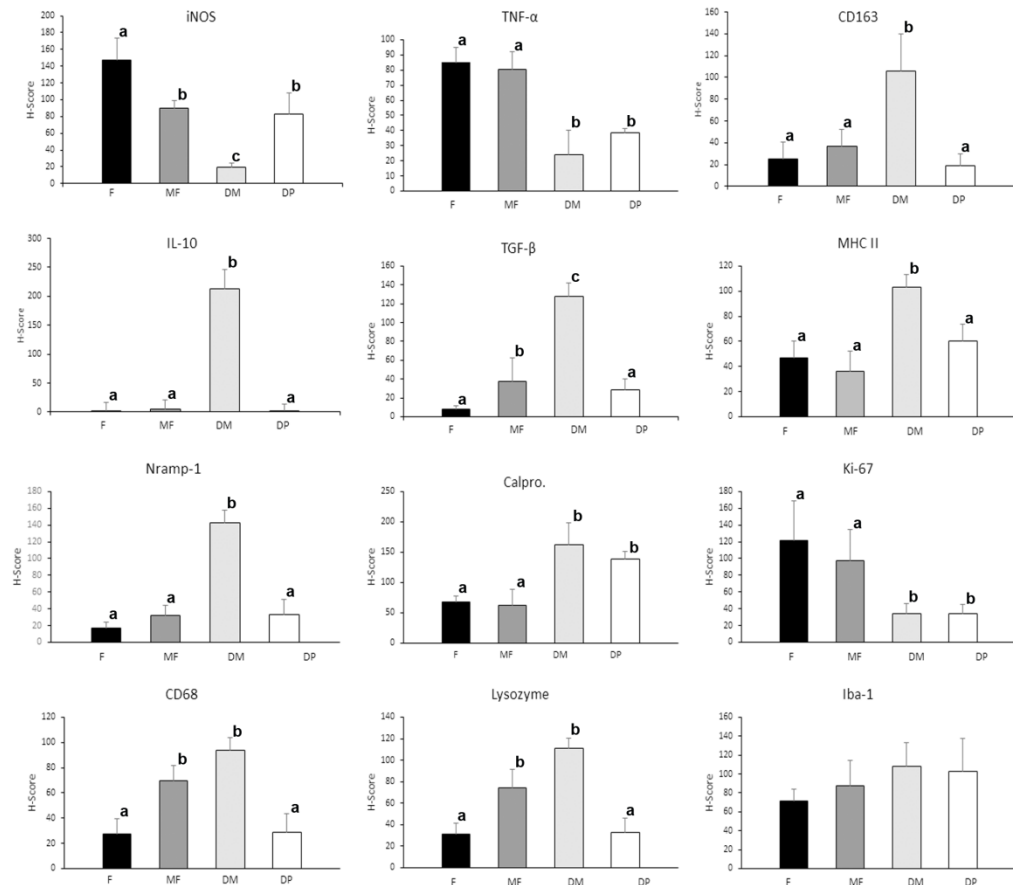


Figure 1. Mean number of the histological score (H-Score) for the immunohistochemical staining according to the different lesion categories for (a) inducible oxide synthase (iNOS), (b) tumor necrosis factor- α (TNF- α), (c) CD163, (d) interleukin-10 (IL-10), (e) transforming growth factor- β (TGF- β), (f) MHC class II, (g) natural resistance macrophage protein-1 (Nramp-1), (h) calprotectin, (i) Ki-67, (j) CD68, (k) lysozyme, and (l) Iba-1 antibodies. F: focal; MF: multifocal; DM: diffuse multibacillary; DP: diffuse paucibacillary. Different letters in superscripts following values indicate statistical significance ($P < 0.05$). Error bars indicate standard error of the mean.

Figure 2- 14

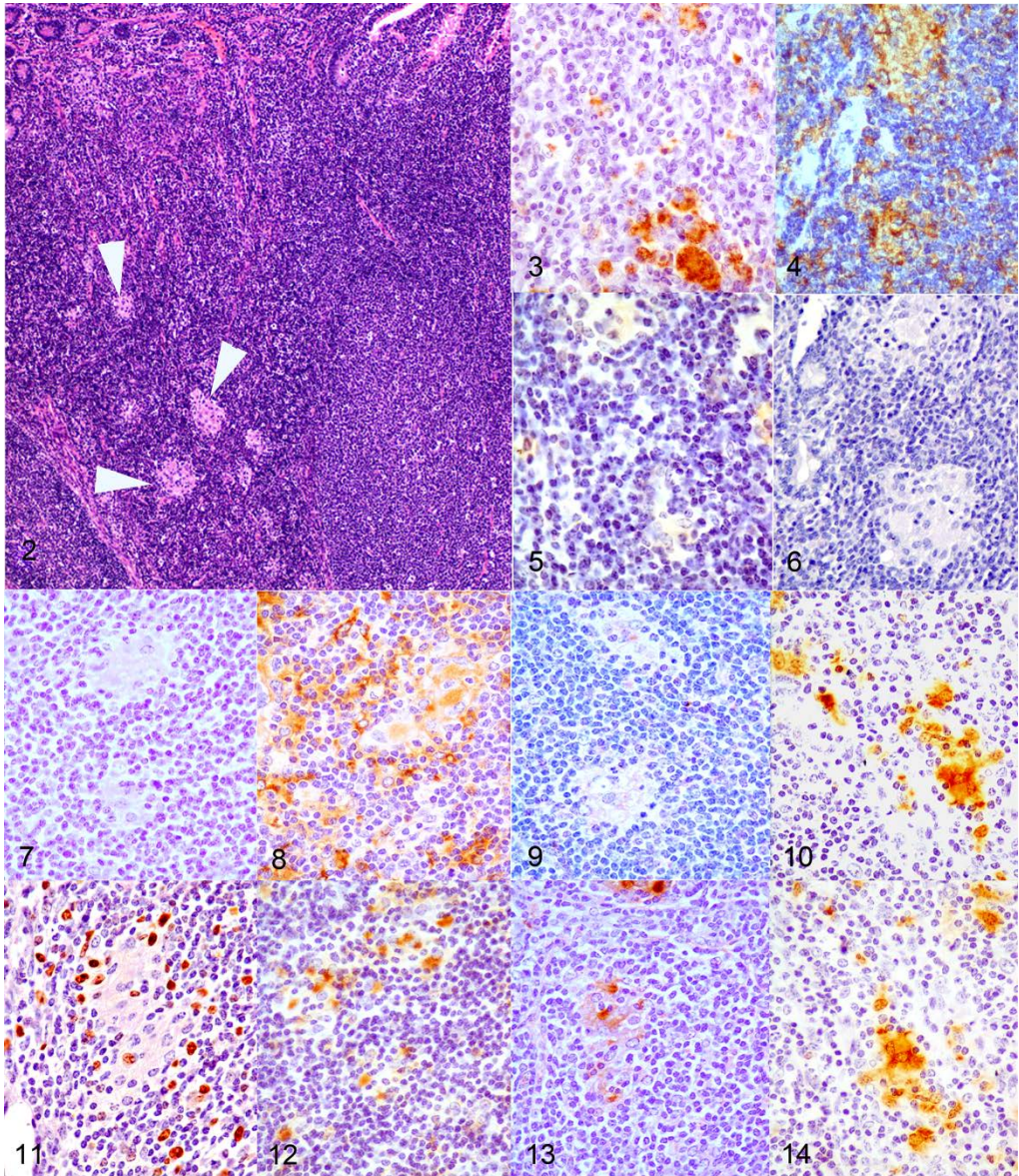


Figure 2-14. *Mycobacterium avium* subsp *paratuberculosis* infection, focal lesion, jejunal Peyer's patches, cattle. **Figure 2.** Small and well demarcated granulomas (arrowheads) in the interfollicular area of the lymphoid tissue. HE. **Figure 3.** Inducible oxide synthase (iNOS) immunoperoxidase stain showing marked immunolabelling in macrophages forming the granulomas. Immunohistochemistry (IHC). **Figure 4.** Intense immunoreactivity for tumor necrosis factor- α (TNF- α) antibody in the granulomas and in lymphocytes from the surrounding lymphoid tissue. IHC. **Figure 5.** Weak immunoperoxidase stain for CD163 in macrophages of the granulomas. (IHC). **Figure 6.** Lack of interleukin-10 (IL-10)+ macrophages. IHC. **Figure 7.** Absence of transforming growth factor- β (TGF- β) expression. IHC. **Figure 8.**

Positive immunolabelling for MHC class II antibody in macrophages and other lymphoid tissue cells. IHC. **Figure 9.** Weak brownish immunoperoxidase stain for natural resistance macrophage protein-1 (Nramp-1) in macrophages. IHC. **Figure 10.** Calprotectin immunoperoxidase stain showing moderate immunolabelling in granuloma macrophages. IHC. **Figure 11.** Positive nuclear immunoreactivity for Ki-67 antibody in macrophages and lymphocytes. IHC. **Figure 12.** Weak immunoperoxidase stain for CD68+ macrophages. IHC. **Figure 13.** Moderate expression of lysozyme immunoperoxidase stain in macrophages. IHC. **Figure 14.** Positive immunolabelling for Iba-1 antibody in the macrophages. IHC.

Figure 15-27

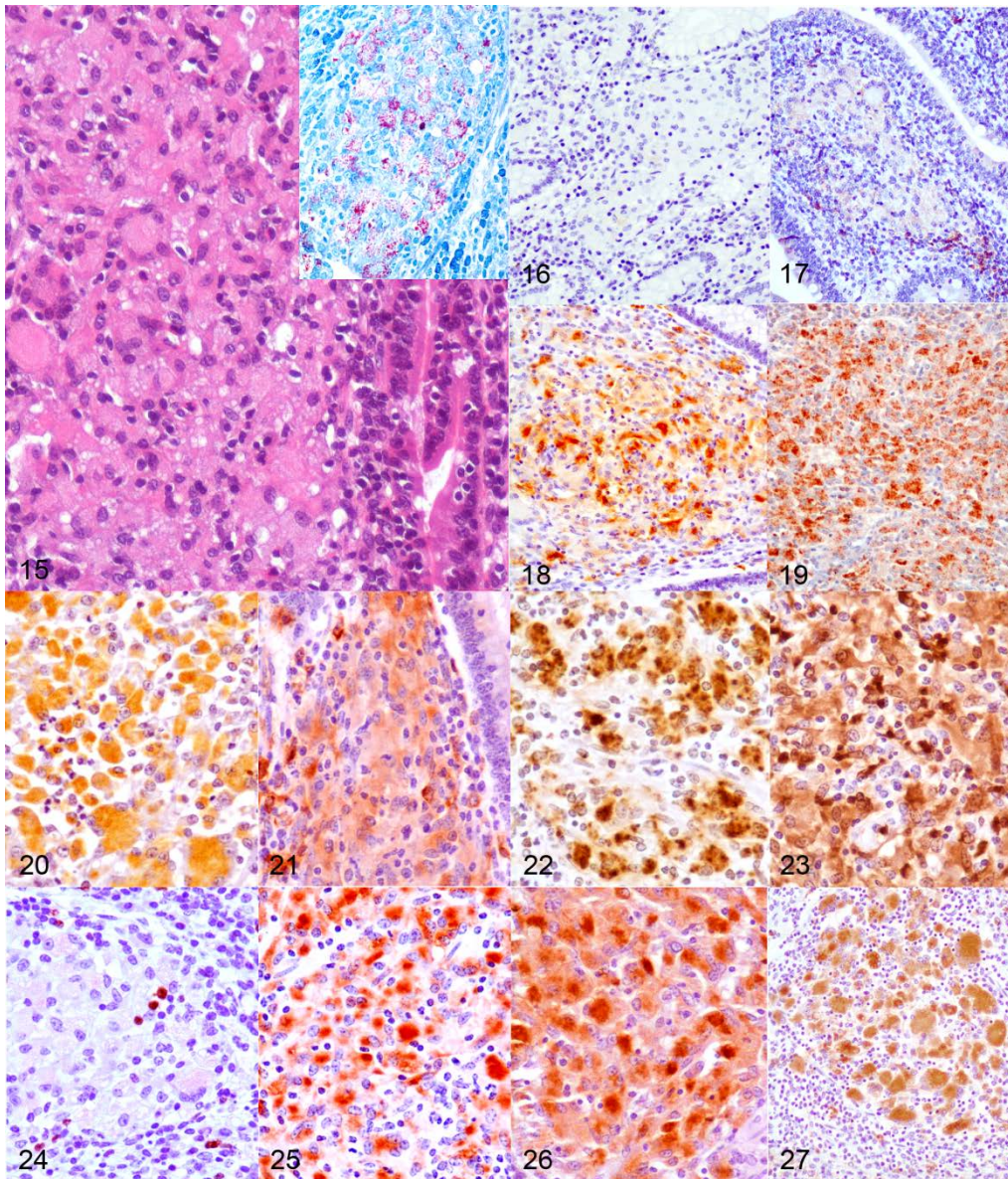
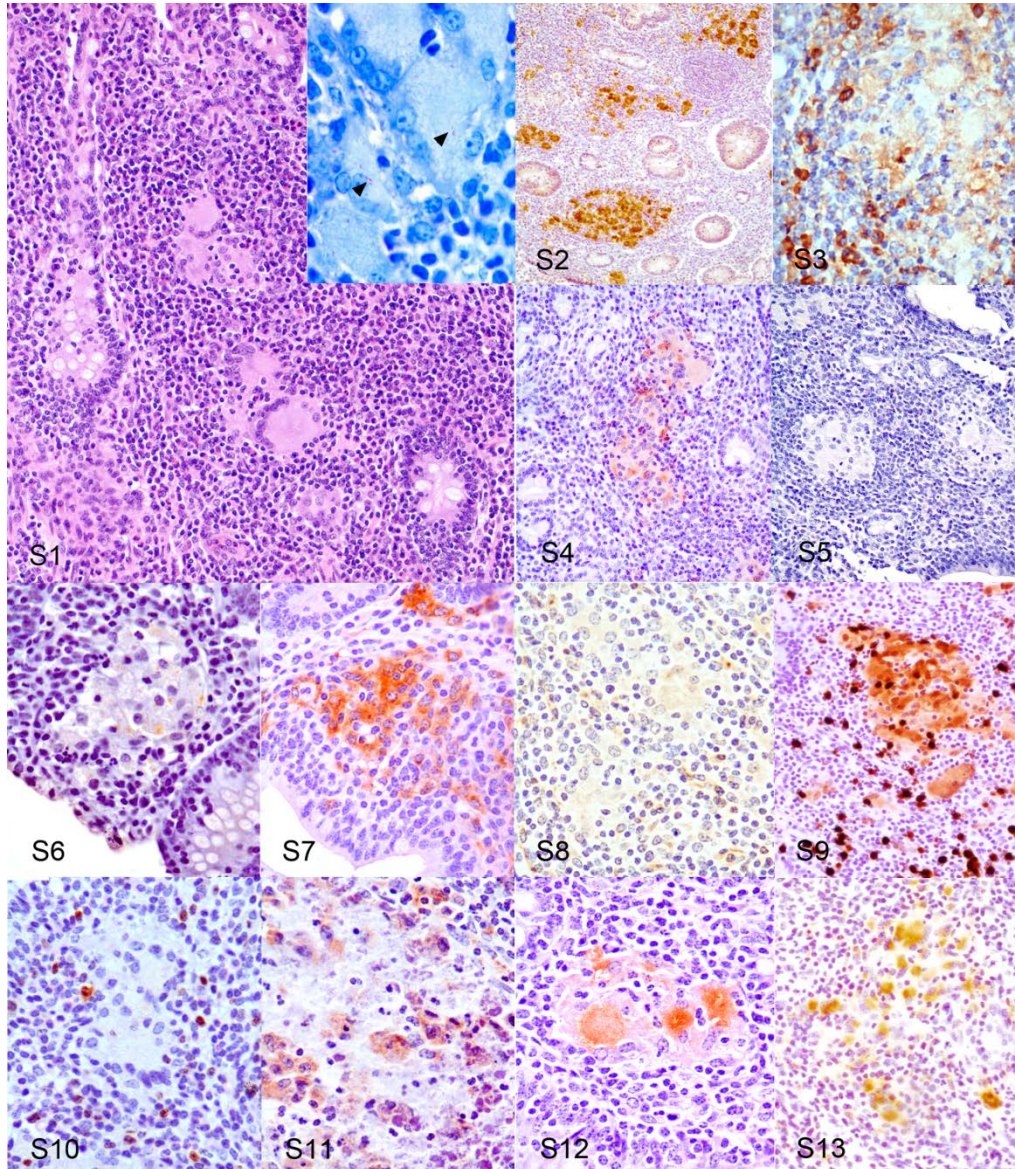


Figure 15-27. *Mycobacterium avium* subsp *paratuberculosis* infection, cattle, ileum, diffuse multibacillary lesion. **Figure 15.** Granulomatous infiltrate in the lamina propria composed mainly of macrophages together with some giant cells and low numbers of lymphocytes. HE. Inset: macrophages contain large numbers of acid fast-bacilli. Ziehl-Neelsen. **Figure 16.** Weak immunoperoxidase staining for inducible oxide synthase (iNOS) in the granulomatous infiltrate. Immunohistochemistry (IHC). **Figure 17.** Tumor necrosis factor- α (TNF- α) immunoperoxidase stain showing weak expression in macrophages. IHC. **Figure 18.** Strong immunoreactivity for CD163 antibody in macrophages. IHC. **Figure 19.** Interleukin-10 (IL-10) immunoperoxidase stain showing intense expression in macrophages. IHC. **Figure 20.** Marked macrophage immunolabelling for transforming growth factor- β (TGF- β) antibody. IHC. **Figure 21.** MHC II immunoperoxidase stain showing intense immunolabelling in the inflammatory infiltrate. IHC. **Figure 22.** Strong immunoreactivity for natural resistance macrophage protein-1 (Nramp-1) antibody. IHC. **Figure 23.** Macrophages in the infiltrate are intensively immunolabelled for calprotectin antibody. IHC. **Figure 24.** Only few macrophages show positive immunolabelling for Ki-67 antibody in their nuclei. IHC. **Figure 25.** Marked immunoperoxidase stain for CD68+ macrophages. IHC. **Figure 26.** Lysozyme immunoperoxidase stain showing intense expression in macrophages. IHC. **Figure 27.** Macrophages in the infiltrate are positively immunolabelled for Iba-1 antibody. IHC.

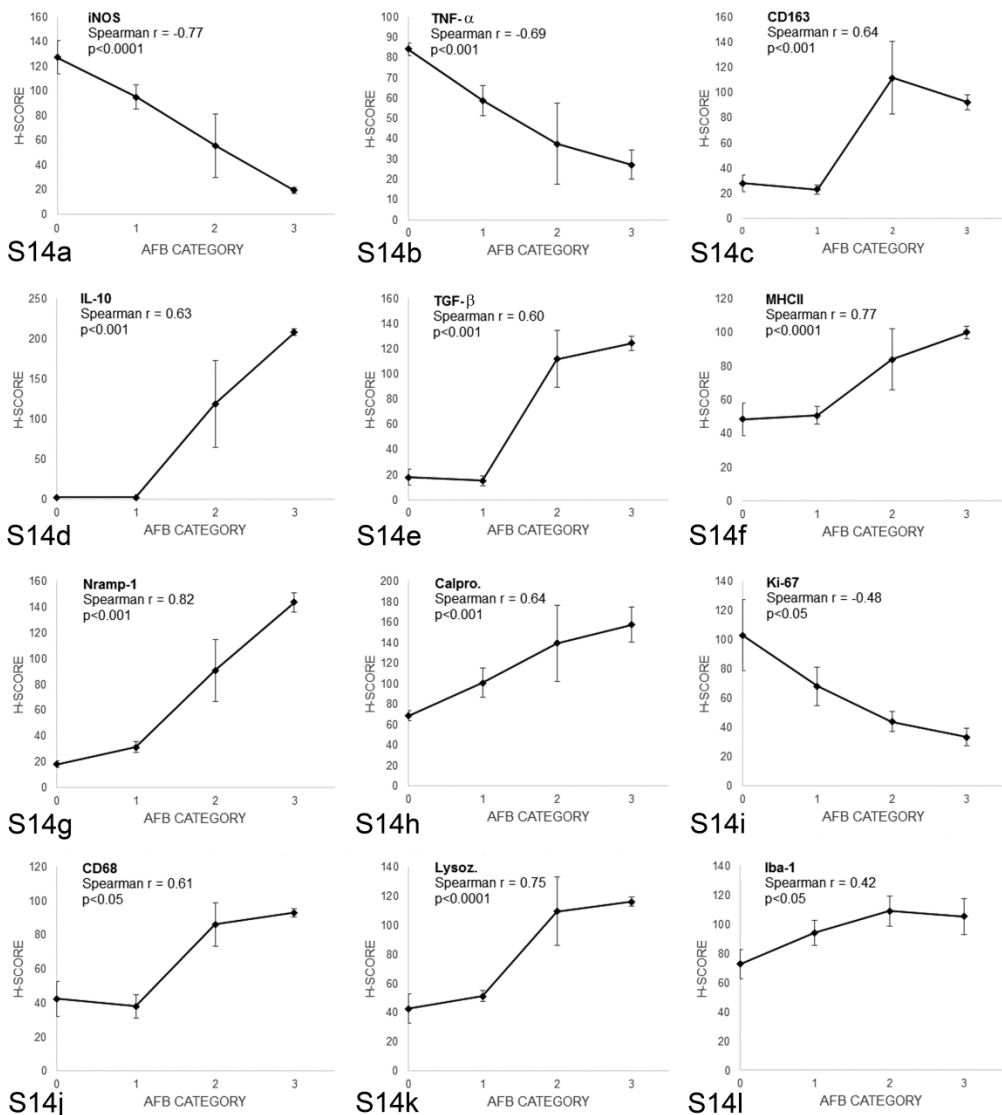
Supplemental Figure S1-S13



Supplemental figures S1-S13. *Mycobacterium avium* subsp *paratuberculosis* infection, cattle, ileum, diffuse paucibacillary lesion. **Figure S1.** Inflammatory infiltrate in the lamina propria is composed mainly of lymphocytes with small groups or macrophages scattered among them. HE. Inset: Macrophages or giant cells contain (arrowheads) few acid-fast bacilli. Ziehl Neelsen. **Figure S2.** iNOS immunoperoxidase stain showing marked immunolabelling in macrophages forming the granulomas. Immunohistochemistry (IHC). **Figure S3.** Weak positive immunoreactivity for TNF- α antibody in the granulomas and more intense in lymphocytes surrounding them. IHC. **Figure S4.** Weak immunoperoxidase stain for CD163 in macrophages of the granulomas. IHC. **Figure S5.** Lack of IL-10+ macrophages. IHC. **Figure S6.** Weak TGF- β expression in the macrophages. IHC. **Figure S7.** Positive immunolabelling for

MHC class II antibody in macrophages and other lymphoid tissue cells. IHC. **Figure S8.** Very weak immunoperoxidase stain for Nramp-1 in macrophages. IHC. **Figure S9.** Calprotectin immunoperoxidase stain showing marked immunolabelling in granuloma macrophages. IHC. **Figure S10.** Absence of nuclear immunoreactivity for Ki-67 antibody in macrophages. IHC. **Figure S11.** Weak immunoperoxidase stain for CD68+ macrophages. IHC. **Figure S12.** Moderate expression of lysozyme immunoperoxidase stain in macrophages. IHC. **Figure S13.** Positive immunolabelling for Iba-1 antibody in the macrophages. IHC.

Supplemental Figure S14



Supplemental figure S14: Relationship between the amount of acid-fast bacilli (AFB) categories in the tissue sections and the histological scores (H-Scores) for (a) inducible oxide synthase (iNOS), (b) tumor necrosis factor- α (TNF- α), (c) CD163, (d) interleukin-10 (IL-10), (e) transforming growth factor- β (TGF- β), (f) MHC class II, (g) natural resistance macrophage protein-1 (Nrp-1), (h) calprotectin, (i) Ki-67, (j) CD68, (k) lysozyme, and (l) Iba-1 antibodies.

4.3.4. Discussion

As a consequence of *Map* infection, animals can develop morphologically distinct granulomatous lesions, from focal forms seen in the subclinical phase of the disease to diffuse lesions usually related to clinical signs (Buergelt *et al.*, 1978; González *et al.*, 2005; Delgado *et al.*, 2013). This study has shown that macrophages present in the granulomatous infiltrates show different immunohistochemical expression of the markers examined, as seen by the differences in the H-scores for several of these markers, depending on the lesion type. These differences can probably play different roles in their development.

Considering this, the semiquantitative method used (H-score) has proven to be a useful tool to evaluate immunostaining, also enabling statistical comparison between these antibodies. Since it was initially proposed for the quantification of hormone receptors in neoplastic cells (Detre *et al.*, 1995), the H-score has been proven to be useful for the immunophenotypic characterization of different cell populations (Charafe-Jauffret *et al.*, 2004). However, this method has evident disadvantages such as only permitting a semiquantitative evaluation of biomarker production that cannot completely correlate with the real expression and the difficulty in assessing the immunostaining when it is not present in a single cell population (Fedchenko y Reifenrath, 2014).

Depending on the polarization status, 2 different phenotypes of macrophages, named M1 and M2, have been recognized. Briefly, M1 or

classically activated macrophages are involved in the response against intracellular pathogens throughout the secretion of proinflammatory cytokines and iNOS, whereas M2 or alternatively activated macrophages have immunoregulatory functions and play a role in tissue remodeling (Mantovani *et al.*, 2004; Sica and Mantovani, 2012; Ka *et al.*, 2014; Martínez and Gordon, 2014). Several of the molecules whose expression has been evaluated in this study are considered to be M1 (iNOS, TNF- α) or M2 (CD163, IL-10, or TGF- β) markers and have shown differential expression.

The results of this study suggest that after *Map* infection, there is a modulation in the macrophage polarization toward proinflammatory and anti-inflammatory forms in the different types of lesions in such a way that in focal lesions, macrophages express markers related to M1 status, whereas in diffuse multibacillary lesions, M2 macrophages would predominate. Similar findings have been reported in *Mycobacterium tuberculosis* infection (Huang *et al.*, 2015; Marino *et al.*, 2015). In a recent study on paratuberculosis, a heterogeneous macrophage activation pattern was observed, characterized by both classical and alternative phenotypes (Thirunavukkarasu *et al.*, 2015); although in the same study, it was found that in animals with low peripheral IFN- γ responses, the proportion of monocytes expressing CD163 (an M2 marker) was higher, while they showed the lowest expression of iNOS (an M1 marker), in accordance with our results. In any case, that study was conducted in blood monocytes from subclinically affected calves, where the lesions were not determined.

Macrophages in focal lesions that have been related to the subclinical stages of paratuberculosis, either to initial phases of *Map* infection or to latent stages (Pérez *et al.*, 1996; González *et al.*, 2005; Delgado *et al.*, 2013), show an M1 phenotype associated with the absence or low numbers of AFB and the production of high levels of iNOS and TNF- α , a proinflammatory

cytokine (Mantovani *et al.*, 2004; Martínez and Gordon, 2014). A similar finding has been observed in the initial granulomas in *M. bovis* infection (Pereira-Suárez *et al.*, 2006; Palmer *et al.*, 2007) also with very low numbers or absence of bacilli and with a similar histological morphology of lesions. Moreover, IFN- γ and TNF- α are the main stimuli that will drive macrophages to an M1 phenotype (Mantovani *et al.*, 2004; Martínez and Gordon, 2014).

In this sense, focal lesions are associated with high levels of plasma IFN- γ production after lymphocyte stimulation (Pérez *et al.*, 1999; Vázquez *et al.*, 2013; Fernández *et al.*, 2014). Tumor necrosis factor α has been shown previously to be produced by macrophages after infection with mycobacteria and it is considered, together with IFN- γ , as an endogenous cofactor in the induction of mycobacterial growth inhibition (Flesch *et al.*, 1994). Inducible nitric oxide synthase induces the production of nitric oxide (NO) that has reported to play a role in mycobacterial infections by supporting killing mechanisms within macrophages (Hostetter *et al.*, 2005; Palmer *et al.*, 2007) and has been related to the subclinical phases of paratuberculosis (Khalifeh *et al.*, 2009). The expression of MHC class II, a molecule that plays a key role in antigen presentation, has also been previously observed in M1-polarized macrophages (Mantovani *et al.*, 2004; Benoit *et al.*, 2008), and in granulomas found in the initial phases of paratuberculosis in goats, with weaker intensity of labeling in those macrophages harboring low amounts of mycobacteria (Valheim *et al.*, 2004; Krüger *et al.*, 2015) as in this study. In this sense, in vitro studies have revealed that, shortly after mycobacterial infection, monocytes downregulate MHC class II expression (Weiss *et al.*, 2001). Natural resistance-associated macrophage protein 1 has been linked to innate resistance to intracellular pathogens (Barton *et al.*, 1999) by reducing the susceptibility to phagosome rupture in macrophages infected with *M. tuberculosis* (Simeone *et al.*, 2015).

Since it is almost undetected in non-activated macrophages (Delgado *et al.*, 2010), its presence in focal lesions could be linked to their ability to control *Map* multiplication, suggesting an activated state of macrophages in these lesions. All these findings suggest that focal lesions could be the reflection of highly protective stages that could last long periods of time (latency), where subclinically infected animals can control the growth of *Map* inside the M1-polarized macrophages, without developing a severe inflammatory response related to clinical signs.

Macrophages in diffuse multibacillary lesions exhibit an M2 profile, as seen by the high expression of CD163, IL-10, and TGF- β markers and the low levels of iNOS and TNF- α . CD163 has been widely considered an M2 marker (Sica and Mantovani, 2012; Barros *et al.*, 2013; Huang *et al.*, 2015), but some studies have reported that it is not totally specific, and macrophage characterization should be done in combination with other markers (Barros *et al.*, 2013; Ka *et al.*, 2014). Following these suggestions, we explored CD163, IL-10, and TGF- β immunostaining, whose high expression has been recognized to be linked to an M2 phenotype (Mantovani *et al.*, 2004; Martínez and Gordon, 2014), more precisely to the M2c category. In contrast to M2a macrophages, associated with allergy and killing and encapsulation of parasites (Mantovani *et al.*, 2004), or M2b macrophages, related to a Th2 activation induced by IL-1,32 M2c macrophages induced by the presence of IL-10 and TGF- β (Mantovani *et al.*, 2004) show a high immunoregulatory and anti-inflammatory activity (Mantovani *et al.*, 2004; Martínez and Gordon, 2014) and predominate in the late stages of tuberculosis infection, posing a risk of exacerbating the disease (Lugo-Villarino *et al.*, 2011).

These mechanisms are probably operating in *Map* infection, since diffuse multibacillary lesions are detected in the late stages of the disease and are characterized by harboring large amounts of AFB, low numbers of

other inflammatory cells rather than macrophages (Buergelt *et al.*, 1978; González *et al.*, 2005), and low expression of iNOS (Hostetter *et al.*, 2005) as in our case. These immunoregulatory actions are related to the production of TGF- β and IL-10 by macrophages that have been demonstrated to play a role in the downregulation of NO production (Mills *et al.*, 200; Khalifeh *et al.*, 2009). This scenario is consistent with the low levels of iNOS and TNF- α (a well-known proinflammatory cytokine) expression found in this type of lesions opposed to those found in focal forms. In paratuberculosis infection, upregulation of TGF- β and IL-10 has been reported in clinical cases during the late stages of the disease (Khalifeh *et al.*, 2009; Abendaño *et al.*, 2013), which are highly expressed in macrophages harboring high numbers of Map (tanaka *et al.*, 2005; Muñoz *et al.*, 2009) in agreement with our results. Expression of MHC class II was significantly higher in diffuse multibacillary lesions compared to the rest of the lesion types.

In contrast to this finding, Navarro *et al.* (1998) did not find immunohistochemical expression of this marker in the cytoplasm of epithelioid cells associated with diffuse lesions and harboring AFB in goats. However, in agreement with the results of this study, Lybeck *et al.* (2013) and Krüger *et al.* (2015) have also reported positive immunolabeling of MHC class II in macrophages from diffuse lesions and showing AFB in their cytoplasm, also in goats and using antibodies different to the one used in this work. A high level of Nramp-1 expression was also observed in these lesions, in the presence of abundant AFB, as it was noted previously by Delgado *et al.* (2010) in paratuberculosis or by Pereira-Suárez *et al.* (2006) for *M. bovis* infection. For these authors, the expression was interpreted as a reflection of mycobacterial infection, since they only examined lesions with remarkable numbers of AFB. In our study, the differential expression of Nramp-1 is also strongly related to the high numbers of AFB as seen in the multibacillary forms. Since this protein is located on the membrane of the macrophage-

containing phagosomes (Frehel *et al.*, 2002), its higher level of expression would be linked to the higher number of these structures present in these cells as a consequence of harboring AFB. Its action in mycobacterial infections would be both to reduce phagosomal rupture (Simeone *et al.*, 2015) and to inhibit the capacity of mycobacteria to arrest phagosome maturation (Frehel *et al.*, 2002), hampering bacterial growth. In diffuse multibacillary lesions, however, these mechanisms would not be efficiently activated, despite high level of Nrap-1 expression, permitting Map intracellular growth and whose nature deserves further investigation.

In comparison with diffuse multibacillary lesions, macrophages in paucibacillary lesions would be mostly polarized toward an M1 type, as shown by high H-scores for iNOS and low scores for CD163, IL-10, and TGF- β (Mantovani *et al.*, 2004; Martínez y Gordon, 2014). However, paucibacillary granulomas showed lower level of TNF- α expression compared to focal lesions. Similar findings have been reported previously (Tanaka *et al.*, 2005; Smeed *et al.*, 2007) and these are probably related to the severe T-lymphocyte infiltration observed in paucibacillary lesions (Navarro *et al.*, 1998; Smeed *et al.*, 2007) which are not reported in focal forms. Supporting this, in human patients with Crohn's disease, a disorder in which Map has been proposed to play an etiological role, and where lesions similar to the diffuse paucibacillary forms reported in this study have been observed (Hermon-Taylor *et al.*, 2000), a downregulation of TNF- α has been found (Campos *et al.*, 2011). It has already been pointed out that severe lesions of paratuberculosis are related to low TNF- α expression regardless of the amount of mycobacteria (Abendaño *et al.*, 2013). Further research is necessary to elucidate the mechanisms underlying these findings.

An interesting finding of this study is the difference between focal and diffuse lesions in the expression levels of calprotectin. Calprotectin is a major

cytosolic protein complex present in monocytes that is expressed in tissue macrophages recently recruited from peripheral blood but whose expression is lost upon further differentiation (Soulas *et al.*, 2011). This fact together with the differences observed in the H-score for Ki-67 protein—a cellular marker for cell proliferation— leads to the hypothesis that a high number of macrophages forming granulomas in diffuse lesions would have been recently recruited from blood, while in focal forms, these would be multiplying in situ, supporting the latent character of this type of lesion and the active and progressive character of diffuse forms, seen in the advanced and uncontrolled cases of paratuberculosis (Buergelt *et al.*, 1978; González *et al.*, 2005).

Supporting this, Valheim *et al.* (2004) also found a high number of macrophages expressing Ki-67 in granulomas from subclinically paratuberculosis-affected goats, and high levels of calprotectin in plasma have been associated with severe and active tuberculosis in humans (Pechkovsky *et al.*, 2000). Opposed to this hypothesis, Jenkins *et al.* (2011) have pointed out that local macrophage proliferation is a signature of a Th2 inflammation. However, their study was conducted in pleural macrophages from rodents infected with a nematode, while Map is an intracellular pathogen affecting the intestine. Probably these facts together with the different methods used for macrophage evaluation in both studies could explain the different results. In any case, this hypothesis should be carefully considered, since lesions in paratuberculosis can show a dynamic character (Koets *et al.*, 2015), as seen in this study by the coexistence of multifocal and diffuse lesions in the same animal and that in this work only one single time point has been evaluated.

Multifocal lesions, with a majority of M1-polarized macrophages showing high H-scores for iNOS and TNF- α (Mantovani *et al.*, 2004; Martínez

and Gordon, 2014) could represent transient lesions between focal and diffuse forms. This is supported by the simultaneous higher expression of TGF- β and lower expression of calprotectin and Ki-67 compared to focal lesions. Thus, although there is a reduced *Map* multiplication and low numbers of new macrophages recruited from the blood, the increased expression of TGF- β could indicate that they are starting to progress to more severe and uncontrolled lesions (Khalifeh *et al.*, 2009; Muñoz *et al.*, 2009).

CD68 and lysozyme have been widely used as general macrophage markers (Ackermann *et al.*, 1994; Pérez *et al.*, 1996; Reddacliff *et al.*, 2004; Valheim *et al.*, 2004; Krüger *et al.*, 2015), which is in agreement with our findings, since they have been found in all the lesion types. However, their expression is shown to be positively correlated with the number of AFB, with the highest H-score levels observed in diffuse multibacillary lesions, as previously reported in paratuberculosis (Ackermann *et al.*, 1994; Hostetter *et al.*, 2005). The fact that CD68 antigen is located in lysosomal membranes, especially in phagolysosomes, and that lysozyme is also produced in the lysosomes (Keshav *et al.*, 1991) would explain why its expression is increased when the number of intracellular bacteria is high (Holness *et al.*, 1993; Reddacliff *et al.*, 2004). A marked expression of Iba-1 has been found in all the lesion types with no differences in the H-score between them. This is a marker for a calcium binding protein that has been considered to be specific for macrophages/microglia (Ohsawa *et al.*, 2004). According to our results, it may be used as a general macrophage marker in granulomatous lesions.

According to the results of this study, the macrophages composing the granulomas associated with *Map* infection show differences in the expression of several proteins, reflecting changes in their functionality based on the type of lesion. M1-type macrophages will predominate in focal and multifocal forms, suggesting their latent character and the ability to control *Map*

infection, and partially in diffuse paucibacillary lesions. M2 are the main type in diffuse multibacillary forms, with an immunoregulatory profile that would permit intracellular *Map* growth. The immunohistochemical analysis of macrophage subsets within *Map* infection–associated lesions has contributed to increased knowledge on the pathogenesis of this disease.

Acknowledgements

We acknowledge the excellent technical assistance of Gloria Belver, Carmen Espiniella, and María Jesús González. We also thank F. Javier Giráldez for his help with the statistical analysis.

Declaration of Conflicting Interests

The author(s) declared no potential conflict of interest with respect to the research, authorship and/or publication of this article.

Funding

The author(s) disclosed receipt of the following financial support for the research, authorship, and/or publication of this article: The study was financially supported by grant AGL2012-39818-C02-01 of the Spanish Ministry of Economy and Competitiveness. M. Fernández and P. Castaño are the recipients of a predoctoral contract from the “Junta de Castilla y León”, partially funded by the European Social Found (European Union). J. Benavides and M. Royo are supported by a “Ramón y Cajal” and a “Predoctoral” contract of the Spanish Ministry of Economy and Competitiveness, respectively.

References

- Abendaño N, Juste RA, Alonso-Hearn M (2013). Anti-inflammatory and antiapoptotic responses to infection: a common denominator of human and bovine macrophages infected with *Mycobacterium avium* subsp. *paratuberculosis*. *Biomed Res Int*. 2013:908348.
- Ackermann MR, DeBey BM, Stabel TJ, Gold JH, Register KB, Meehan JT (1994). Distribution of anti-CD-68 (EBM11) immunoreactivity in formalin-fixed, paraffin-embedded bovine tissues. *Vet Pathol*. 31:340–348.

- Barros MH, Hauck FM, Dreyer JH, Kempkes B, Niedobitek G (2013). Macrophage polarisation: an immunohistochemical approach for identifying M1 and M2 macrophages. *PLoS One*. 8:e80908.
- Barton CH, Biggs TE, Baker ST, Bowen H, Atkinson PG (1999). Nramp1: a link between intracellular iron transport and innate resistance to intracellular pathogens. *J Leuk Biol*. 66:757–762.
- Benoit M, Desnues B, Mege JL (2008). Macrophage polarization in bacterial infections. *J Immunol*. 181:3733–3739.
- Buergelt CD, Hall C, McEntee K, Duncan JR (1978). Pathological evaluation of paratuberculosis in naturally infected cattle. *Vet Pathol*. 15:196–207.
- Campos N, Magro F, Castro AR, Cabral J, Rodrigues P, Silva R, Appelberg R, Rodrigues S, Lopes S, Macedo G, Sarmento A (2011). Macrophages from IBD patients exhibit defective tumour necrosis factor- α secretion but otherwise normal or augmented pro-inflammatory responses to infection. *Immunobiology*. 216: 961–970.
- Charafe-Jauffret E, Tarpin C, Bardou VJ, Bertucci F, Ginestier C, Braud AC, Puig B, Geneix J, Hassoun J, Birnbaum D, Jacquemier J, Viens P (2004). Immuno-phenotypic analysis of inflammatory breast cancers: identification of an “inflammatory signature”. *J Pathol*. 202:265–273.
- Davies LC, Jenkins SJ, Allen E, Taylor PR (2013). Tissue-resident macrophages. *Nat Immunol*. 14:986–995.
- Delgado F, Estrada-Chávez C, Romano M, Paolicchi F, Blanco-Viera F, Capellino F, Chavez-Gris G, Pereira-Suárez AL (2010). Expression of NRAMP1 and iNOS in *Mycobacterium avium* subsp. *paratuberculosis* naturally infected cattle. *Comp Immunol Microbiol Infect Dis*. 33:389–400.
- Delgado L, Marín JF, Muñoz M, Benavides J, Juste RA, García-Pariente C, Fuertes M, González J, Ferreras MC, Pérez V (2013). Pathological findings in young and adult sheep following experimental infection with 2 different doses of *Mycobacterium avium* subsp. *paratuberculosis*. *Vet Pathol*. 50:857–866.
- Detre S, Saclani Jotti G, Dowsett M (1995). A “quickscore” method for immunohistochemical semiquantitation: validation for oestrogen receptor in breast carcinomas. *J Clin Pathol*. 48:876–878.
- Fedchenko N, Reifenrath J (2014). Different interpretation and reporting of immunohistochemistry analysis results in the bone tissue. A review. *Diagn Pathol*. 9:221.
- Fernández M, Benavides J, Sevilla IA, Fuertes M, Castaño P, Delgado L, García- Marín JF, Garrido JM, Ferreras MC, Pérez V (2014). Experimental infection of lambs with C and S-type strains of *Mycobacterium avium* subsp. *paratuberculosis*: immunological and pathological findings. *Vet Res*. 45:5.
- Flesch IE, Hess JH, Oswald IP, Kaufmann SH (1994). Growth inhibition of *Mycobacterium bovis* by IFN- γ stimulated macrophages: regulation by endogenous tumor necrosis factor- α and by IL-10. *Int Immunol*. 6:693–700.
- Frehel C, Canonne-Hergaux F, Gros P, De Chastellier C (2002). Effect of Nramp1 on bacterial replication and on maturation of *Mycobacterium avium*-containing phagosomes in bone marrow-derived mouse macrophages. *Cell Microbiol*. 4:541–556.
- Fries PN, Popowych YI, Guan LL, Griebel PJ (2011). Age-related changes in the distribution and frequency of myeloid and T cell populations in the small intestine of calves. *Cell Immunol*. 271:428–437.

- González J, Geijo MV, García-Pariente C, Verna A, Corpa JM, Reyes LE, Ferreras MC, Juste RA, García Marín JF, Pérez V (2005). Histopathological classification of lesions associated with natural paratuberculosis infection in cattle. *J Comp Pathol.* 133:184–196.
- Harris NB, Barletta RG (2001). *Mycobacterium avium* subsp. *paratuberculosis* in veterinary medicine. *Clin Microbiol Rev.* 14:489–512.
- Hermon-Taylor J, Bull TJ, Sheridan JM, Cheng J, Stellakis ML, Sumar N (2000). Causation of Crohn's disease by *Mycobacterium avium* subspecies *paratuberculosis*. *Can J Gastroenterol.* 14:521–539.
- Holness C, Simmons DL (1993). Molecular cloning of CD68, a human macrophage marker related to lysosomal glycoproteins. *Blood.* 81:1607–1613.
- Hostetter J, Huffmann E, Byl K, Steadham E (2005). Inducible nitric oxide synthase immunoreactivity in the granulomatous intestinal lesions of naturally occurring bovine Johne's disease. *Vet Pathol.* 43:241–249.
- Huang Z, Luo Q, Guo Y, Chen J, Xiong G, Peng Y, Ye J, Li J (2015). *Mycobacterium tuberculosis*-induced polarization of human macrophage orchestrates the formation and development of tuberculous granulomas in vitro. *PLoS One.* 10:e0129744.
- Jenkins SJ, Ruckerl D, Cook PC, Jones LH, Finkelman FD, van Rooijen N, MacDonald AS, Allen JE (2011). Local macrophage proliferation, rather than recruitment from the blood, is a signature of Th2 inflammation. *Science.* 332:1284–1288.
- Ka MB, Daumas A, Textoris J, Mege JL (2014). Phenotypic diversity and emerging new tools to study macrophage activation in bacterial infectious diseases. *Front Immunol.* 5:500.
- Keshav S, Chung P, Milon G, Gordon S (1991). Lysozyme is an inducible marker of macrophage activation in murine tissues as demonstrated by in situ hybridization. *J Exp Med.* 174:1049–1058.
- Khalifeh MS, Al-Majali AM, Stabel JR (2009). Role of nitric oxide production in dairy cows naturally infected with *Mycobacterium avium* subsp. *paratuberculosis*. *Vet Immunol Immunopathol.* 131:97–104.
- Koets AP, Eda S, Sreevatsan S (2015). The within host dynamics of *Mycobacterium avium* ssp. *paratuberculosis* infection in cattle: where time and place matter. *Vet Res.* 46:61.
- Krüger C, Köhler H, Liebler-Tenorio EM (2015). Cellular composition of granulomatous lesions in gut-associated lymphoid tissues of goats during the first year after experimental infection with *Mycobacterium avium* subsp. *paratuberculosis*. *Vet Immunol Immunopathol.* 163:33–45.
- Lugo-Villarino G, Vérollet C, Maridonneau-Parini I, Neyrolles O (2011). Macrophage polarization: convergence point targeted by *Mycobacterium tuberculosis* and HIV. *Front Immunol.* 2:43.
- Lybeck KR, Løvoll M, Johansen TB, Olsen I, Storset AK, Valheim M (2013). Intestinal strictures, fibrous adhesions and high local Interleukin-10 levels in goats infected naturally with *Mycobacterium avium* subsp *paratuberculosis*. *J Comp Pathol.* 148:157–172.
- Mantovani A, Sica A, Sozzani S, Allavena P, Vecchi A, Locati M (2004). The chemokine system in diverse forms of macrophage activation and polarization. *Trends Immunol.* 25:677–686.
- Marino S, Cilfone NA, Mattila JT, Linderman JJ, Flynn JL, Kirschner DE (2015). Macrophage polarization drives granuloma outcome during *Mycobacterium tuberculosis* infection. *Infect Immun.* 83:324–338.

- Martinez FO, Gordon S (2014). The M1 and M2 paradigm of macrophage activation: time for reassessment. *F1000 Prime Rep.* 6:13.
- Mills CD, Kincaid K, Alt JM, Heilman MJ, Hill AM (2000). M-1/M-2 macrophages and the Th1/Th2 paradigm. *J Immunol.* 164:6166–6173.
- Muñoz M, Delgado L, Verna A, Benavides J, García-Pariente C, Fuertes M, Ferreras MC, García-Marín JF, Pérez V (2009). Expression of transforming growth factor beta 1 (TGF- β 1) in different types of granulomatous lesions in bovine and ovine paratuberculosis. *Comp Immunol Microbiol Infect Dis.* 32:239–252.
- Muñoz M, García-Marín JF, García-Pariente C, Reyes LE, Verna AE, Moreno O, Fuertes M, Doce J, Puentes E, Garrido JM, Pérez V (2006). Efficacy of a killed vaccine (SILIRUM) in calves challenged with *Mycobacterium avium* subsp. *paratuberculosis*. In: Manning EJB, Nielsen SS, eds. *Proceedings of the 8th International Colloquium on Paratuberculosis*. Madison, WI: IAP. 208–217.
- Navarro JA, Ramis G, Seva J, Pallarés FJ, Sánchez J (1998). Changes in lymphocyte subsets in the intestine and mesenteric lymph nodes in caprine paratuberculosis. *J Comp Pathol.* 118:109–121.
- Ohsawa K, Imai Y, Sasaki Y, Kohsaka S (2004). Microglia/macrophage-specific protein Iba1 binds to fimbrin and enhances its actin-bundling activity. *J Neurochem.* 88:844–856.
- Palmer MV, Waters WR, Thacker TC (2007). Lesion development and immunohistochemical changes in granulomas from cattle experimentally infected with *Mycobacterium bovis*. *Vet Pathol.* 44:863–874.
- Pechkovsky DV, Zalutskaya OM, Ivanov GI, Misuno NI (2000). Calprotectin (MRP8/14 protein complex) release during mycobacterial infection in vitro and in vivo. *FEMS Immunol Med Microbiol.* 29:27–33.
- Pereira-Suárez AL, Estrada-Chávez C, Arriaga-Díaz C, Espinosa-Cueto P, Mancilla R (2006). Coexpression of NRAMP1, iNOS and nitrotyrosine in bovine tuberculosis. *Vet Pathol.* 43:709–717.
- Pérez V, García-Marín JF, Badiola JJ (1996). Description and classification of different types of lesion associated with natural paratuberculosis infection in sheep. *J Comp Pathol.* 114:107–122.
- Pérez V, Tellechea J, Badiola JJ, Gutiérrez M, García Marín JF (1997). Relation between serologic response and pathologic findings in sheep with naturally acquired paratuberculosis. *Am J Vet Res.* 58:799–803.
- Pérez V, Tellechea J, Corpa JM, Gutiérrez M, García Marín JF (1999). Relation between pathologic findings and cellular immune responses in sheep with naturally acquired paratuberculosis. *Am J Vet Res.* 60:123–127.
- Reddacliff LA, McClure SJ, Whittington RJ (2004). Immunoperoxidase studies of cell mediated immune effector cell populations in early *Mycobacterium avium* subsp. *paratuberculosis* infection in sheep. *Vet Immunol Immunopathol.* 97:149–162.
- Scholzen T, Gerdes J (2000). The Ki-67 protein: from the known and unknown. *J Cell Physiol.* 182:311–322.
- Sica A, Mantovani A (2012). Macrophage plasticity and polarization: in vivo veritas. *J Clin Invest.* 122:787–795.
- Sigurdardóttir OG, Valheim M, Press CM (2004). Establishment of *Mycobacterium avium* subsp. *paratuberculosis* infection in the intestine of ruminants. *Ann Drug Deliv Rev.* 56:819–834.

- Simeone R, Sayes F, Song O, Gröschel MI, Brodin P, Brosch R, Majlessi L (2015). Cytosolic access of *Mycobacterium tuberculosis*: critical impact of phagosomal acidification control and demonstration of occurrence in vivo. *PLoS Pathog.* 11:e1004650.
- Smeed JA, Watkins CA, Rhind S, Hopkins J (2007). Differential cytokine gene expression profiles in the three pathological forms of sheep paratuberculosis. *BMC Vet Res.* 3:18.
- Soulas C, Conerly C, Kim WK, Burdo TH, Alvarez X, Lackner AA, Williams KC (2011). Recently infiltrating MAC387+ monocytes/macrophages. A third macrophage population involved in SIV and HIV encephalic lesion formation. *Am J Pathol.* 178: 2121–2135.
- Tanaka S, Sato M, Onitsuka T, Kamata H, Yokomizo Y (2005). Inflammatory cytokine gene expression in different types of granulomatous lesions during asymptomatic stages of bovine paratuberculosis. *Vet Pathol.* 42:579–588.
- Thirunavukkarasu S, de Silva K, Begg DJ, Whittington RJ, Plain KM (2015). Macrophage polarization in cattle experimentally exposed to *Mycobacterium avium* subsp. *paratuberculosis*. *Pathog Dis.* 73:ftv085.
- Valheim M, Sigurdardóttir OG, Sotorset AK, Aune LG, Press CM (2004). Characterization of macrophages and occurrence of T cells in intestinal lesions of subclinical paratuberculosis in goats. *J Comp Pathol.* 131:221–232.
- Vázquez P, Garrido JM, Juste RA (2013). Specific antibody and interferon-gamma responses associated with immunopathological forms of bovine paratuberculosis in slaughtered Friesian cattle. *PLoS One.* 8:e64568.
- Weiss DJ, Evanson OA, McClenahan D, Abrahamsen MS, Walcheck BK (2001). Regulation of expression of major histocompatibility antigens by bovine macrophages infected with *Mycobacterium avium* subsp. *paratuberculosis* and *Mycobacterium avium* subsp. *avium*. *Infect Immun.* 69:1002–1008.
- Whittington RJ, Begg DJ, de Silva K, Plain KM, Purdie AC (2012). Comparative immunological and microbiological aspects of paratuberculosis as a model of mycobacterial infection. *Vet Immunol Immunopathol.* 148:29–47.

4.4. CUARTO ESTUDIO

FOURTH STUDY



Fernández M, Fuertes M, Elguezábal N,
Castaño C, Royo M, Ferreras MC,
Benavides J, Pérez V.

**Immunohistochemical expression of
interferon- γ in different types of granulomatous lesions
associated with bovine paratuberculosis. *Comp Immunol
Microbiol Infect Dis.* 2017; 51:1-8.**

Factor de impacto 1,943

Veterinary Sciences 17/133

4.4. Immunohistochemical expression of interferon- γ in different types of granulomatous lesions associated with bovine paratuberculosis

Miguel Fernández¹, Miguel Fuertes¹, Natalia Elguezabal², Pablo Castaño¹, Marcos Royo¹, M. Carmen Ferreras¹, Julio Benavides¹, Valentín Pérez^{1*}

¹Departamento de Sanidad Animal, Instituto de Ganadería de Montaña (CSIC-ULE), Facultad de Veterinaria, Universidad de León, Campus de Vegazana s/n, León 24071, Spain.

²Departamento de Sanidad Animal, NEIKER-Tecnalia, Berreaga 1, Derio, Bizkaia 48160, Spain.

* Corresponding author: Valentín Pérez (vperp@unileon.es)

Received: 17 August 2016.

Accepted: 7 January 2017.

Abstract

Animals infected with *Mycobacterium avium* subsp. *paratuberculosis* (*Map*) show a variety of lesions, from focal forms, seen in subclinical stages to diffuse lesions in clinical cases. The purpose of this study was to evaluate the local expression of IFN- γ by immunohistochemistry in relation with the type of lesion in naturally *Map*-infected cows. The number of immunolabelled cells, –the majority morphologically consistent with lymphocytes–, was higher in focal and diffuse paucibacillary forms than in diffuse multibacillary lesions, where they appeared closely related to epithelioid cells. Diffuse multibacillary lesions had the lowest numbers, but higher than controls, and positive cells were intermingled among the macrophages. The peripheral IFN- γ production was higher in all *Map*-infected cows and a positive correlation was found with

the number of immunolabelled cells in the intestine. The findings of this study show that IFN- γ would play a role in the development of the different types of lesions in paratuberculosis, and also points out the importance of adequate sampling of lymphoid tissue containing samples when studying the local immune response in which IFN- γ expression may be involved, especially in cases where focal lesions are present.

4.4.1. Introduction

Paratuberculosis or Johne's disease is a worldwide distributed infectious disease that causes a negative impact on domestic livestock, characterized by a decrease in productivity associated with a progressive loss of weight and eventual death of affected animals (Harris and Barletta, 2001; Arsenault *et al.*, 2014). It is caused by *Mycobacterium avium* subspecies *paratuberculosis* (*Map*) and characterized by a chronic granulomatous enteritis and lymphadenitis that concerns domestic and wild ruminants (Harris and Barletta, 2001; Sweeney, 2011; Arsenault *et al.*, 2014). Furthermore, speculation on the possibility of *Map* representing a zoonotic threat, as a possible causative agent of Crohn's disease, has elevated the priority of this disease to an issue of food safety (Arsenault *et al.*, 2014).

Many studies support that animals get infected at an early age through ingestion of *Map* contained in feces shed by infected animals but only some of them develop clinical disease that appears only in adulthood (Sweeney, 2011; Arsenault *et al.*, 2014). *Map*-infected animals can show a variety of granulomatous lesions, according to their location, intensity, cellular types and number of acid-fast bacilli (AFB) (Buergelt *et al.*, 1978; Pérez *et al.*, 1996; González *et al.*, 2005). Three main types of lesions, related to the stage of the disease, have been considered: *focal* forms, seen in subclinical phases of infection, are characterized by few, well-demarcated granulomas located exclusively in the intestinal lymphoid tissue; *diffuse*

lesions, associated with clinical cases, show a widespread granulomatous enteritis that affects both the lymphoid tissue and lamina propria. According to the main cell types present in the inflammatory infiltrate and the number of AFB in diffuse lesions, two different categories have been distinguished: *diffuse multibacillary* forms, where epithelioid cells containing large numbers of AFB are the hallmark, and *diffuse paucibacillary* lesions characterized by an infiltrate formed by lymphocytes with isolated granulomas without AFB or a scarce number of them (Pérez *et al.*, 1996; González *et al.*, 2005).

Several studies have shown a relationship between the type of lesion and the peripheral immune response (Pérez *et al.*, 1997, 1999; Vázquez *et al.*, 2013). Traditionally, it has been considered that a Th1 type immune response would predominate in the early and subclinical stages of *Map* infection shifting to a Th2 type response in the late phases of the disease (Stabel, 2007; Stabel and Robbe-Austerman, 2011). However, recent evidence suggests that an overlap of these pathways can occur in some animals (Begg *et al.*, 2011; Vázquez *et al.*, 2013; Fernández *et al.*, 2014; Koets *et al.*, 2015). The strong Th1 bias dominated by an enhanced expression and secretion of interferon- γ (IFN- γ) in the early stages of *Map* infection suggests that this cytokine is critical for controlling the infection (Pérez *et al.*, 1999; Stabel, 2007; Stabel and Robbe-Austerman, 2011; Arsenault *et al.*, 2014). IFN- γ is produced predominantly by CD4+ Th1 cells and natural killer (NK) cells, and activates macrophages classically to bestow protection against *Map* infection by killing mycobacteria during phagocytosis (Cooper *et al.*, 2002; Stable, 2007; Arsenault *et al.*, 2014).

In any case, scant information is available in relation to the local immune response. Furthermore, previous studies have mentioned that the peripheral immune response in *Map* infection does not correlate directly with the immune response at the intestinal lymph node level (Begara-McGorum *et*

al., 1998; Shu *et al.*, 2011). Concerning the role of IFN- γ at the local level, most of the previous research has focused on the quantification of gene transcription of this cytokine in tissue samples –intestine or lymph nodes- and has shown an upregulation of IFN- γ mRNA transcription associated with *Map* infection in cattle (Lee *et al.*, 2001; Coussens *et al.*, 2004; Shu *et al.*, 2011) or sheep (Begara-McGorum *et al.*, 1998). However, the relationship between transcription levels and lesion types is not clear. While some studies have failed to detect significant differences in the local IFN- γ gene transcription between diffuse multibacillary and paucibacillary forms in cattle (Tanaka *et al.*, 2005) or sheep (Gillan *et al.*, 2010), other studies have shown higher IFN- γ transcription levels in paucibacillary forms in sheep (Smeed *et al.*, 2007) or increased gene transcription that is directly correlated with the severity of the lesion, regardless of the type (Shu *et al.*, 2011). An increase of IFN- γ secretion by lymphocytes derived from intestine or lymph nodes after stimulation with johnin-PPD has been also recorded in sheep with paucibacillary lesions respect to multibacillary forms (Burrells *et al.*, 1999).

However, there are no studies focused on the immunohistochemical detection of IFN- γ expression in relation to the types of lesion. Only Reddacliff *et al.* (2004) used immunoperoxidase methods for the evaluation of IFN- γ expressing cells in sheep positive to *Map* isolation but without gross or microscopic lesions, where few immunostained cells were detected and no comparison with the uninfected controls was possible.

Thus, bearing in mind the scarcity of studies that investigate the local expression of IFN- γ at the primary site of infection using immunohistochemical techniques, the main purpose of this study was the evaluation of the local expression of IFN- γ in relation with the different types of lesions associated with *Map* infection, in both control and naturally infected cows using these type of methods. Particular attention was paid to

the assessment of the amount of positively immunolabelled cells and their distribution along the granulomatous infiltrate that characterizes each type of lesion as well as the relationship with the IFN- γ production after peripheral blood stimulation.

4.4.2. Material and methods

Experimental design

A total of twenty adult Holstein female cattle were analyzed in the study. They were adult animals (between 3 and 6 years-old), non-pregnant, dry cows that belonged to a herd that was undergoing a follow-up study on losses due to paratuberculosis. Infection was confirmed in 15 of them by both bacteriological culture of frozen tissues (González *et al.*, 2005) and nested-PCR for *Map* DNA detection in the paraffin-embedded tissues used in the study (Fernández *et al.*, 2014). The remaining 5 cows were examined as negative controls. All the cows were killed according to the standard methods in the current legislation in an authorized slaughterhouse.

Tissue samples

Gut and related lymph nodes were macroscopically evaluated and samples were collected for histopathological and immunohistochemical analysis. Particularly, samples from ileocecal valve, distal, middle or proximal ileum and jejunum (with and without Peyer's patches) as well as ileocecal, ileal and jejunal mesenteric lymph nodes were taken from each animal. Samples were fixed in 10% buffered formalin for less than 48 h and conventionally processed through a graded alcohol series before being embedded in paraffin wax. Sections 3.5 μm thick were obtained from each sample and stained with Mayer's haematoxylin and eosin and Ziehl-Neelsen method for AFB identification. A subjective classification of the sections according to the number of AFB present was made, from 0 (no detectable

bacilli), 1 (scant AFB in the cytoplasm of macrophages, seen with difficulty), 2 (moderate, easily detectable bacilli) to 3 (high load of AFB).

Classification of lesions

No lesion consistent with *Map* infection was observed in the five uninfected control cattle, while granulomatous lesions were detected in different samples from the intestine and lymph nodes from the remaining animals. Lesions were categorized following the guidelines previously proposed (González *et al.*, 2005) for paratuberculosis lesions –according to the presence and location of granulomas in the different intestinal compartments, cell types present in the infiltrate and the amount of AFB-, as focal, diffuse multibacillary and diffuse paucibacillary. Only in the two latter types grossly visible thickening of the intestinal wall was noted. Each animal was classified based on the most severe lesion found in the studied intestinal samples. Focal lesions were composed of small, well-demarcated granulomas, up to 40–50 epithelioid cells, located exclusively in the interfollicular areas of the intestinal lymphoid tissue. Granulomas were also detected in the paracortical areas of the lymph nodes. None or very few AFB was detected. This type of lesion was present in 5 *Map*-infected cows.

Diffuse lesions were characterized by a widespread granulomatous lymphadenitis and enteritis where the normal intestinal architecture was notably distorted. Lesions were present in areas of the intestine with and without lymphoid tissue. In Peyer's patches, macrophages and occasional Langhan's type giant cells were seen both in the interfollicular areas and in the lymphoid follicles. The lamina propria was markedly distended due to the presence of abundant inflammatory cells. According to the cellular type and number of AFB, two different diffuse forms were considered: diffuse multibacillary lesions, seen in 5 *Map*-infected cows, were characterized by the predominance of epithelioid cells harbouring large numbers of AFB

(categories 2 and 3); diffuse paucibacillary lesions, identified in another 5 *Map*-infected cows, showed large numbers of lymphocytes in the infiltrate, with some epithelioid and giant cells, with none or occasional AFB (categories 0 and 1).

Immunohistochemistry

Immunohistochemical studies were performed in a total of 20 intestinal tissue sections, one from each animal included in the study. From each animal, a sample from middle jejunum containing Peyer's patches was examined. This section was representative of the lesion category assigned to the animal. In total, five tissue sections from each type of lesion, from five different animals, were included, as well as five samples of middle jejunum (with Peyer's patches) without *Map* associated lesions, from the control cows. A primary monoclonal antibody (IgG1 isotype) against bovine IFN- γ (Clone CC330; Bio-Rad laboratories Inc[®], Hercules, USA) was used. After deparaffinization, rehydration and drying, sections were immersed into a 3% H₂O₂ in methanol solution during 30 min at room temperature and darkness, to block endogenous peroxidase. Heat mediated antigen retrieval was performed by means of PT Link[®] system, using the pH 6.0 target retrieval solution (Dako-Agilent technologies, Glostrup, Denmark) for 20 min. Samples were incubated overnight at 4°C with the primary anti-body at a 1:250 dilution in PBS in a humidified chamber. After washing, immunolabelling was performed using a ready-to-use kit EnVision System[®] (Dako-Agilent technologies, Glostrup, Denmark) where slides were incubated for 40 min at room temperature. After washing twice in PBS, antibody localization was determined using 3,3-diaminobenzidine (Dako-Agilent technologies, Glostrup, Denmark) as chromogenic substrate for peroxidase. Finally, slides were counterstained with Mayer's haematoxylin. Appropriate -species and isotype-matched immunoglobulins were used as negative controls.

Evaluation of immunolabelling

Samples were scored according to the number of positively immunolabelled cells. In each slide, a total of 40 randomly chosen fields containing granulomatous lesions were selected and photographed at 400X. In tissues showing diffuse lesions, the inflammatory infiltrate occupying all the intestinal mucosa and granulomas were evaluated regardless of their location in the lamina propria or lymphoid tissue. In each of the 5 tissue sections presenting focal lesions, cell counting was performed in 40 microscopic fields in areas of lymphoid tissue with granulomatous lesions, 40 in the lymphoid tissue with no granulomas and another 40 fields in the lamina propria. Similarly, in the control cows, positively immunolabelled cells were counted in 40 fields each of the lamina propria and the lymphoid tissue areas independently. Immunolabelled cells were counted on digital images using the Cell Counting add-on of Image J program® (U.S. National Institutes of Health, Bethesda, Maryland, USA).

The final value for each type of lesion was obtained firstly calculating the average value for the 40 fields with granulomas examined in each tissue section and then, extracting the mean value between the 5 tissue slides evaluated. For the control cows, the average value for the 40 areas examined in the lymphoid tissue and lamina propria respectively was calculated independently and then, the mean value for each animal and finally the average between the 5 slides analyzed. Evaluation of the different tissue sections for lesion classification as well as immunohistochemical stain, was performed independently by two pathologists (M. Fernández, V. Pérez) and discordant results were reviewed with a multiheaded microscope to reach consensus.

Interferon- γ release assay (IGRA) in peripheral blood

Between 2–4 days before slaughter, whole blood samples were collected from the tail vein in 5 ml vacutainer tubes (Venoject®, Terumo Europe N. V., Leuven, Belgium) with heparin. For the IFN- γ release assay (IGRA), two separate aliquots of 1.5 ml of blood were mixed with either 100 μ l of a sterile PBS or an avian purified protein derivative (PPD) antigen (CZ Veterinaria, Porriño, Spain) at a final concentration of 30 μ g/mL, within 3 h from the time of blood collection. After 20 h of whole-blood culture at 37°C, the plasma supernatant was removed and frozen at –20°C until required. Then, the assay for the IFN- γ determination was carried out following the manufacturer’s instructions (BOVIGAM TB Kit®, ThermoFisher Scientific, Waltham, USA). In order to avoid inter-plate variations, all the O.D. values were adjusted by dividing the sample O.D. minus the negative control O.D., by the positive control O.D. minus the negative control O.D. from each plate. Once the raw values were standardised, results were expressed as a ratio between the mean OD of the avian PPD-stimulated plasma and the mean O.D. of the same plasma incubated with PBS.

Statistical analysis

As data for cell counting and IGRA index were not normally distributed, they were analyzed with nonparametric methods of statistical assessment. The Kruskal-Wallis test was used to compare the cell counts for the different groups of lesions (focal, diffuse multibacillary, diffuse paucibacillary) and the Mann-Whitney test was applied for post hoc comparison when significant differences were observed. A $P < 0.05$ was considered to indicate statistical significance. Correlation between cell counts and IGRA indexes for the different animals was evaluated using the Spearman test. All statistical analyses were performed using the statistical software Stata/SE version 12.0 (Stata Corp., Texas, USA).

4.4.3. Results

Distribution of immunolabelled cells

IFN- γ positively immunolabelled cells showed the cytoplasm markedly brown-colored and their identification was made according to their morphological features. The majority of positively immunostained cells had round nuclei and scant cytoplasm, morphologically consistent with lymphocytes, although the existence of larger positive cells that could be compatible with macrophages was also detected, always in low numbers. Epithelioid or multinucleated giant cells present in the granulomas of the different types of lesion did not show any immunostaining. Positively immunolabelled cells were always located in the lamina propria and in the intestinal lymphoid tissue.

In the control cows, very few cells were positively immunolabelled and they were scattered both in the lamina propria and the interfollicular area of the lymphoid tissue (Fig. 1A and B). In samples with focal lesions, a high number of immunolabelled cells were seen in close relationship with the epithelioid cells forming the granulomas in the lymphoid tissue, where they appeared intermingled or in their vicinity (Fig. 1C and D). In the rest of the intestine, both in the lamina propria or lymphoid tissue with no lesions, few, scattered positively immunolabelled cells were detected with a similar distribution as in the control uninfected cows.

Regarding diffuse multibacillary lesions, few positive cells were intermingled with the epithelioid cells that were the main component of the inflammatory infiltrate, showing a similar distribution along the entire tissue section (Fig. 1E and F). However, in diffuse paucibacillary lesions, the number of positively immunolabelled cells was higher than in diffuse multibacillary lesions. They were more abundant in relation with the epithelioid or giant

cells that formed the granulomas, appearing intermingled or surrounding them. They were frequently disposed forming aggregates or clusters. Positively immunolabelled cells were also found among the entire inflammatory infiltrate but to a lesser extent than in the areas with granulomas (Fig. 1G and H).

Number of immunolabelled cells for IFN- γ in relation to the type of lesion

The results of the cell counting in the tissue sections representing the different types of lesion are shown in Fig. 2. The number of cells labelled for IFN- γ was significantly higher ($P < 0.001$) in tissue sections presenting *Map*-associated lesions than in those from the control animals. The highest number of immunolabelled cells was observed in samples with focal lesions and was significantly higher ($P < 0.001$) than in the rest of the groups. Among the different types of lesion, sections with diffuse multibacillary forms showed significantly lower ($P < 0.001$) number of immunolabelled cells than the other two types.

In tissue sections with focal lesions, the number of labelled cells in areas without granulomas was assessed and the results are shown in Fig. 3. In this case, no significant differences were observed in the number of cells stained for IFN- γ both in the lamina propria or lymphoid tissue, between sections from control, uninfected cows and those with focal lesions.

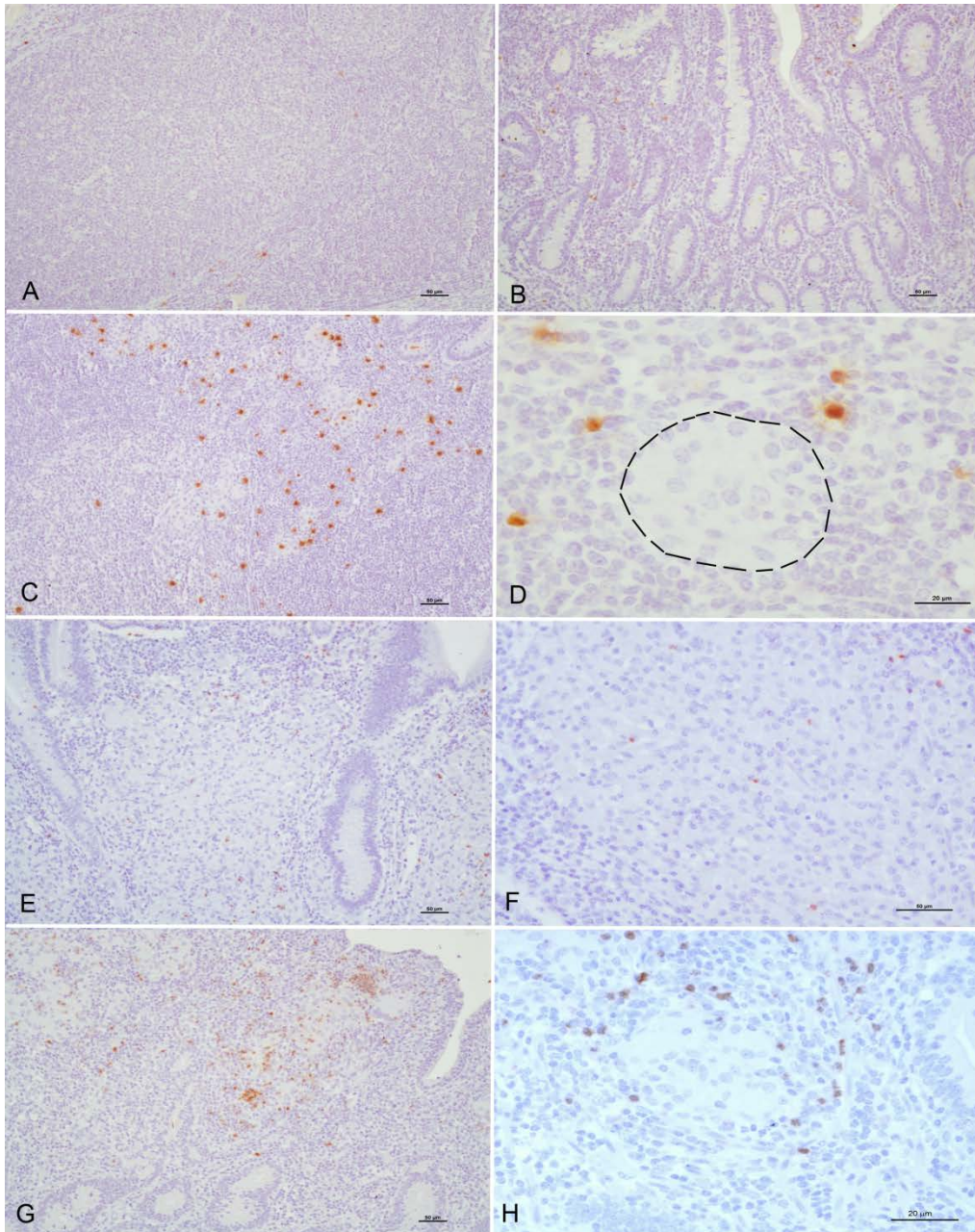


Figure 1. Tissue sections from control and infected animals showing different types of lesions associated with *Map* infection, immunolabelled for IFN- γ . Positively immunostained cells show a brown-colored cytoplasm. Very few IFN- γ + cells in the interfollicular areas of the Peyer's patches (A) and intestinal lamina propria (B) in a control uninfected cow. Focal lesion. Positively immunolabelled cells are mainly located in relation with the granulomatous infiltrate. (C) Focal lesion. A higher magnification field showing IFN- γ + cells disposed close to the epithelioid cells (delimited by a line) that show no immunolabelling. Diffuse multibacillary lesion. Few, scattered immunolabelled cells are intermingled between the epithelioid cells

forming the inflammatory infiltrate (E, F). Diffuse paucibacillary lesion. Numerous IFN- γ + cells mainly located in relation with epithelioid and giant cells where they can be seen forming aggregates or clusters and also intermingled between the granulomatous infiltrate (G, H).

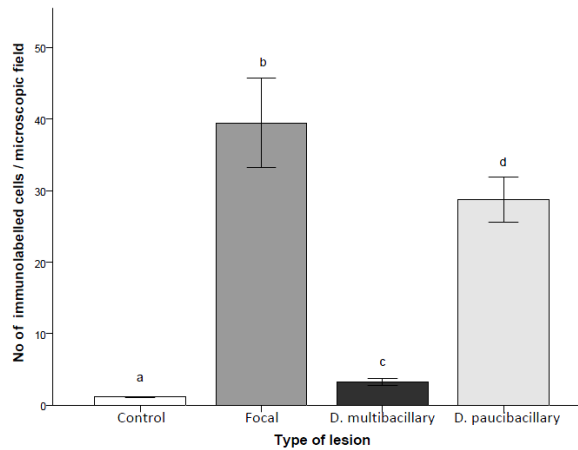


Figure 2. Mean number of immunolabelled cells for IFN- γ per microscopic field, according to the type of lesion. Each type of lesion was assessed in 5 cows. A total of 40 microscopic fields was evaluated per animal. Different superscript letters indicate statistical significance ($P<0.05$). Error bars: standard error.

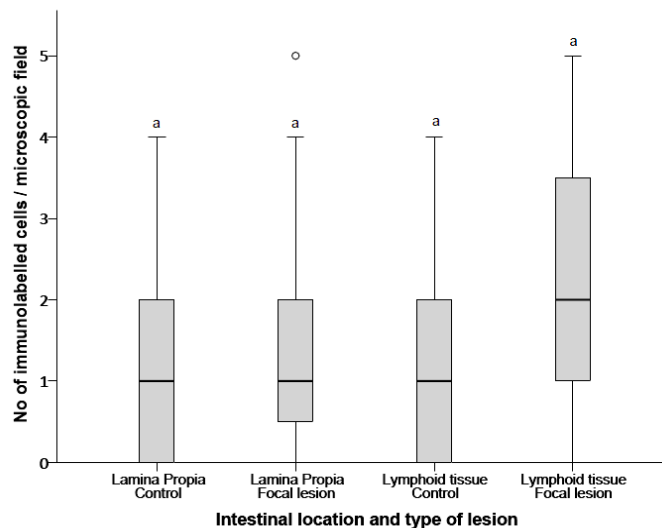


Figure 3. Box-plot showing the mean number of immunolabelled cells for IFN- γ in the different intestinal compartments (lamina propria or lymphoid tissue) in the 5 control animals and in the 5 cows with focal lesions (in areas devoid of granulomatous infiltrate). A total of 40 microscopic fields were evaluated per location and animal. The solid lines show the median values and the open circles represent outlier values. Different superscript letters indicate statistical significance ($P<0.05$).

Peripheral production of IFN- γ measured by IGRA

Fig. 4 shows the mean of the IFN- γ production indexes after blood stimulation in IGRA, according to the lesion category of the animals. Significant differences were observed ($P < 0.001$) between the control cows and the rest of the groups. The highest values were seen in animals with diffuse paucibacillary lesions, that were significantly higher than in those showing diffuse multibacillary forms ($P < 0.001$), whereas no statistical difference was observed in cows with focal lesions. Likewise, no significant differences were detected in the IFN- γ index between animals with focal lesions and those with diffuse multibacillary forms. As seen in Fig. 5, a positive correlation ($r_s = 0.6184$; $P < 0.05$) could be established between the number of cells positively immunolabelled for IFN- γ in the intestinal sections examined for each animal and the peripheral production of IFN- γ by IGRA of the same cow after blood stimulation.

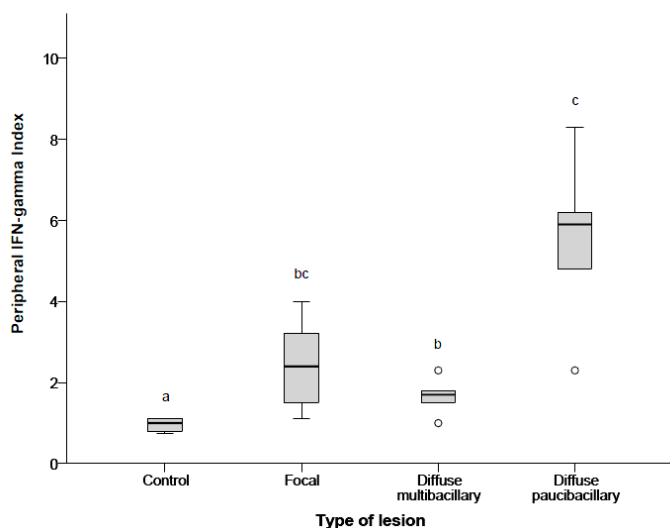


Figure 4. Box-plot that shows the IFN- γ index obtained after peripheral blood stimulation with avian-PPD, according to the type of lesion showed by the cows. The solid lines show the median values and the open circles represent outlier values. Different superscript letters indicate statistical significance ($P < 0.05$).

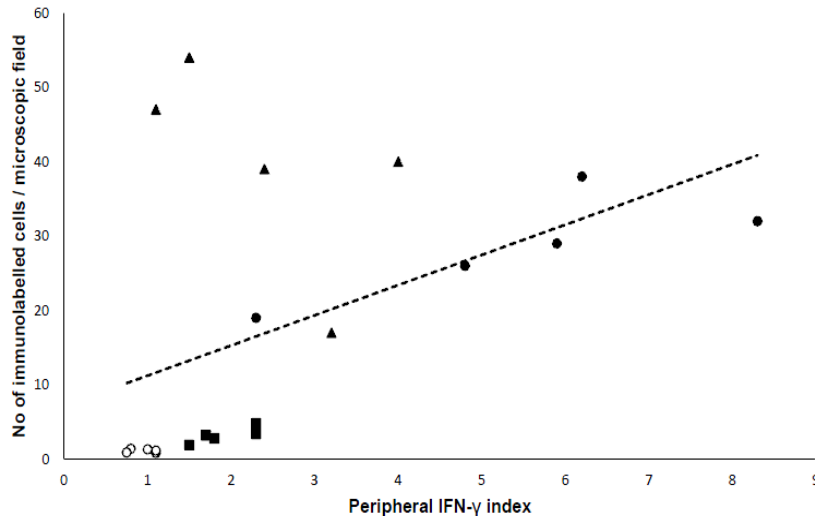


Figure 5. Relationship between the number of immunolabelled cells for IFN- γ per microscopic field and the IFN- γ index obtained after peripheral blood stimulation with avian-PPD. Each type of lesion was assessed in 5 cows. A total of 40 microscopic fields was evaluated per animal. \circ control uninfected cows; \blacktriangle animals with focal lesions; \blacksquare diffuse multibacillary lesion; \bullet diffuse paucibacillary lesion.

4.4.4. Discussion

The results of this study have shown that IFN- γ could play a role in the development of the different types of granulomatous lesions associated with *Map* infection, since an increase in the number of IFN- γ positively immunolabelled cells has been observed in lesion containing samples in contrast to uninfected controls. Although lymphocytes are the main cells that produces this cytokine (Zuñiga *et al.*, 2012) other types of cells such as macrophages or dendritic cells have been also identified as able to produce IFN- γ (Gessani and Belardelli, 1998; Vremec *et al.*, 2007; García-Jiménez *et al.*, 2012). In our study, we have not specifically identified the positively immunolabelled cells, although the majority of them were morphologically consistent with lymphocytes. In a previous work in tuberculosis lesions in deer (García-Jiménez *et al.*, 2012) positive IFN- γ immunohistochemical

labelling has been also found in cells morphologically compatible with epithelioid and multinucleated giant cells (Gessani and Belardelli, 1998) that in our study have been always negative, suggesting the existence of differences between both mycobacterial infections or both animal species.

The critical function of IFN- γ in the immune defense against intracellular pathogens, including mycobacteria, has been widely documented (Cooper *et al.*, 2002; Stabel, 2007; Zuñiga *et al.*, 2012; Arsenault *et al.*, 2014). This cytokine is essential for the activation of phagocytes and antigen presentation so that after infection, respiratory burst contributing to reactive oxygen and nitrogen intermediates production is induced in macrophages, with a known bactericidal activity (Cooper *et al.*, 2002; Arsenault *et al.*, 2014).

Animals infected with *Map* can develop a variety of lesions, from focal forms seen in the subclinical phase of the disease to diffuse lesions usually related to clinical signs (Buergelt *et al.*, 1978; Pérez *et al.*, 1996; González *et al.*, 2005). The highest number of IFN- γ immunolabelled cells was detected in focal lesions. They are related to initial or latent phases of paratuberculosis, with AFB rarely present, and are characterized by a very well demarcated inflammatory infiltrate composed of granulomas located exclusively in the intestinal lymphoid tissue (Pérez *et al.*, 1996; González *et al.*, 2005; Fernández *et al.*, 2014). This finding suggests that IFN- γ has activated macrophages and limited *Map* growth. In this sense, it has recently been reported that macrophages present in focal lesions show an M1 or classically activated profile (Fernández *et al.*, 2017) characterized by iNOS production and mycobacteria growth inhibition (Mantovani *et al.*, 2004; Fernández *et al.*, 2017).

IFN- γ is one of the main stimuli that drive macrophages to a M1 phenotype (Mantovani *et al.*, 2004; Martínez and Gordon, 2014) and the

results of this study suggest that the production of this cytokine by lymphocytes located in the vicinity of the granulomas would be responsible of macrophage activation. Similarly, in tuberculosis caused by *Mycobacterium bovis* in deer, an increase in the number of cells expressing IFN- γ evaluated by immunohistochemistry has been found in stage I granulomas -considered as initial lesions with no AFB-, in comparison with more advanced forms (García-Jiménez *et al.*, 2012).

In diffuse paucibacillary lesions, IFN- γ would play a similar role to that played in focal forms, since the number of immunolabelled cells was also high and they were located closely to granulomas with no or few AFB. Moreover, the presence of M1 or classically activated macrophages has been reported in this type of lesion (Fernández *et al.*, 2017). Some other cytokines or other factors different from IFN- γ should be responsible for the development, in the *Map*-infected animal, either of focal or diffuse paucibacillary lesions (Smeed *et al.*, 2007; Gillan *et al.*, 2010). In diffuse multibacillary lesions, the low levels of IFN- γ expressing cells would fit with the presence of abundant AFB in the cytoplasm of the macrophages. These macrophages show a M2 phenotype (Fernández *et al.*, 2017) and are associated with low levels of IFN- γ (Mantovani *et al.*, 2004; Martínez y Gordon, 2014). The presence of a widespread and non-organized granulomatous infiltrate in the intestine in this type of lesion, seems therefore related to low local expression of IFN- γ . It has been shown, in *M. avium* or other opportunistic mycobacterial species infections, that the presence of IFN- γ is necessary for the development of organized granulomas and in its absence, there is a disorganized accumulation of mixed cellular infiltrates (Ehlers and Ritcher, 2001).

Thus IFN- γ , in addition to its role as a limiting factor in lymphocyte accumulation (Cooper *et al.*, 2002), would also play a role in granuloma formation. All these findings would be broadly consistent with the already

proposed model of a Th1 to Th2 transition in the immune response in paratuberculosis (Stabel, 2007). Although this paradigm may not be present in all infected animals (Begg *et al.*, 2011; Vázquez *et al.*, 2013; Fernández *et al.*, 2014), the findings from this study would indicate that, at a local level, in initial or latent, sub-clinical forms of the disease, a Th1 response characterized by the presence of high numbers of IFN- γ producing cells is predominant whereas, when the infection progresses to diffuse multibacillary forms, with high numbers of AFB, lesions are associated with low levels of cells expressing IFN- γ .

However, in those animals in which infection has progressed to diffuse paucibacillary lesions, a Th1 response would be operating, although it is not able to control the inflammatory response. The factors responsible for this shift are still unknown (Koets *et al.*, 2015) and deserve further investigation. Probably a complex coordination of immune responses occurs with these responses shifting as the host transits through the different stages of infection and disease (Stabel and Robbe-Austerman, 2011). It has been seen that the *Map* strain (Verna *et al.*, 2007; Fernández *et al.*, 2014), the age of the animals at infection (Delgado *et al.*, 2012) or individual factors such as pattern recognition receptor expression (Nalubamba *et al.*, 2008) can play a role in the development of different immune or pathological responses, but other factors such as infection load, T cell exhaustion or hormonal changes have been also considered (Koets *et al.*, 2015). In our case, all were adult cows from the same breed, herd and managed under the same conditions so that presumably infected with the same *Map* strain. Although the age of infection was unknown, it seems feasible that individual factors would have played a role in the development of the different forms.

There are multiple studies that have outlined the importance of IFN- γ to the pathogenesis of paratuberculosis. In most of them, the role of this

cytokine at local level has been investigated by the measurement of its production in stimulated lymphocytes extracted from the mesenteric lymph nodes (Burrells *et al.*, 199) or by the gene transcription analysis (Begara-McGorum *et al.*, 1998; Lee *et al.*, 2001; Coussens *et al.*, 2004; Shu *et al.*, 2011) that is usually higher in *Map* infected animals. However, when the relationship with pathology has been determined, the results are variable and discordant. While in some studies in cattle, gene transcription for IFN- γ is directly correlated with the severity of the lesion (Shu *et al.*, 2011), in other works it is higher in subclinically rather than in clinically infected animals, presumably with more severe lesions (Sweeney *et al.*, 1998).

There is also discordance in the results from the studies analyzing the relation between IFN- γ mRNA transcription and the type of lesion. While there seems to be no differences between uninfected cattle and those showing lesions equivalent to diffuse multibacillary or paucibacillary forms (Gillan *et al.*, 2010), a higher gene transcription has been seen but in sheep suffering from paucibacillary lesions in comparison to uninfected animals (Smeed *et al.*, 2007). In our study, however, clear differences have been found in the number of cells immunolabelled for IFN- γ between diffuse multibacillary and paucibacillary lesions. Nevertheless, the main variations were observed in asymptomatic but infected animals that in most of these studies (Coussens *et al.*, 2004; Tanaka *et al.*, 2005; Smeed *et al.*, 2007; Gillan *et al.*, 2010; Shu *et al.*, 2011) did not show differences with the uninfected controls, while in our case, those animals with focal lesions showed the highest number of immunolabelled cells for IFN- γ .

Considering the small size and demarcation of granulomas in focal forms and their exclusive presence in the intestinal lymphoid tissue, when a piece of tissue is taken for gene expression analysis, the likelihood of having a granulomatous lesion would be very low.

Since the majority of immunomarked cells were located closely associated with the granulomas and in areas where no lesion was present no differences in the number of cells with the controls was observed, as demonstrated in this study, it seems feasible that no differences in gene expression with control animals could be obtained. This hypothesis could explain the absence of IFN- γ gene expression in infected but asymptomatic animals already mentioned (Smeed *et al.*, 2007; Gillan *et al.*, 2010; Shu *et al.*, 2011). A similar situation could occur when diffuse lesions are analyzed, since the number of lymphocytes expressing IFN- γ can vary among tissue sections, especially in paucibacillary forms. Thus, in further studies, the sampling of areas of the intestine with lymphoid tissue (ileocecal union or jejunal Peyer's patches) would increase the probability of having focal granulomatous lesions in the tissue sample. Furthermore, it has to be considered that these variations in the results can be due to the different nature of the methodology employed.

The role of post-transcriptional modifications of IFN- γ expression (Maarifi *et al.*, 2015) has also to be taken into account. A direct correlation has been found between the number of immunolabelled cells for IFN- γ in the intestine and the released levels of this cytokine in plasma after blood stimulation. This result suggests that, in this study, the peripheral immune response can be a reflection of the local immune response and sensitized peripheral lymphocytes could have migrated from the intestine to the blood (Rothkötter *et al.*, 1999). However, this possibility has to be carefully taken, considering that in the present work we have measured different parameters such as the number of cells that are producing IFN- γ in the intestine, and the quantity of this cytokine produced by peripheral blood cells after their stimulation.

The results of this study show that lymphocytes expressing IFN- γ would play a role in the development of the lesion types with *Map* infection and also that the presence of positively immunolabelled cells is closely related to the macrophages that form the granulomas and the quantity of AFB. Bearing this in mind, and in order to increase the chance of analyzing focal lesions, the choice of tissue samples with lymphoid tissue, especially in subclinically affected animals is recommended when evaluating the effects of this cytokine. Finally, the fact that all the animal groups with lesions, even severe, have shown higher levels of IFN- γ immunolabelled cells than the control group, suggest that this cytokine cannot prevent the development of diffuse forms, related clinical signs, although it is associated with *Map* growth inhibition inside the macrophages that are present in these lesions.

Competing interests

The authors declared no potential conflicts of interest with respect to the research, authorship and/or publication of this article.

Acknowledgements

This study was funded by grants AGL2012-39818-C02-01 and AGL2015-66540-C2-1 from the Spanish Ministry of Economy and Competitiveness. M. Fernández and P. Castaño are supported by a predoctoral contract from the “Junta de Castilla y León” and “Fondo Social Europeo” (European Union). J. Benavides and M. Royo are the recipients of a “Ramón y Cajal” and a “Predoctoral” contract of the Spanish Ministry of Economy and Competitiveness, respectively.

References

- Arsenault RJ, Maattanen P, Daible J, Potter A, Griebel P, Napper S (2014). From mouth to macrophage: mechanisms of innate immune subversion by *Mycobacterium avium* subsp. *paratuberculosis*. *Vet Res.* 45: 54.
- Begara-McGorum I, Wildblood LA, Clarke CJ, Connor KM, Stevenson K, McInnes CJ, Sharp JM, Jones DG (1998). Early immunopathological events in experimental ovine paratuberculosis. *Vet Immunol Immunopathol.* 63:265–287.

- Begg DJ, de Silva K, Carter N, Plain KM, Purdie A, Whittington RJ (2011). Does a Th1 over Th2 dominancy really exists in the early stages of *Mycobacterium avium* subspecies *paratuberculosis* infections. *Immunobiology*. 216:840–846.
- Buergelt CD, Hall C, McEntee K, Duncan JR (1978). Pathological evaluation of paratuberculosis in naturally infected cattle. *Vet Pathol*. 15:196–207.
- Burrells C, Clarke CJ, Colston A, Kay JM, Porter J, Little D, Sharp JM (1999). Interferon-gamma and interleukin-2 release by lymphocytes derived from the blood, mesenteric lymph nodes and intestines of normal sheep and those affected with paratuberculosis (Johne's disease). *Vet Immunol Immunopathol*. 68:139–148.
- Cooper AM, Adams LB, Dalton DK, Appelberg R, Ehlers S (2002). IFN- γ and NO in mycobacterial disease: new jobs for old hands. *Trends Microbiol*. 10:221–226.
- Coussens PM, Verman N, Coussens MA, Elftman MD, McNulty AM (2004). Cytokine gene expression in peripheral blood mononuclear cells and tissues of cattle infected with *Mycobacterium avium* subsp. *paratuberculosis*: evidence for an inherent proinflammatory gene expression pattern. *Infect Immun*. 72: 1409–1422.
- Delgado L, Juste RA, Muñoz M, Morales S, Benavides J, Ferreras MC, García-Marín JF, Pérez V (2012). Differences in the peripheral immune responses between lambs and adult ewes experimentally infected with *Mycobacterium avium* subsp. *paratuberculosis*. *Vet Immunol Immunopathol*. 145:23–31.
- Ehlers S, Richter E (2001). Differential requirement for interferon- γ to restrict the growth of or eliminate some recently identified species of non tuberculous mycobacteria in vivo. *Clin Exp Immunol*. 124:229–238.
- Fernández M, Benavides J, Castaño P, Elguezabal N, Fuertes M, Muñoz M, Royo M, Ferreras MC, Pérez V (2017). Macrophage subsets within granulomatous intestinal lesions in bovine paratuberculosis. *Vet Pathol*. 54:82–93.
- Fernández M, Benavides J, Sevilla IA, Fuertes M, Castaño P, Delgado L, García Marín JF, Garrido JM, Ferreras MC, Pérez V (2014). Experimental infection of lambs with C and S-type strains of *Mycobacterium avium* subspecies paratuberculosis: immunological and pathological findings. *Vet Res*. 45:5.
- García-Jiménez WL, Fernández-Llario P, Gómez L, Benítez-Medina JM, García-Sánchez A, Martínez R, Risco D, Gough J, Ortiz-Peláez A, Smith NH, Hermoso de Mendoza J, Salguero FJ (2012). Histological and immunohistochemical characterisation of *Mycobacterium bovis* induced granulomas in naturally infected fallow deer (*Dama dama*). *Vet Immunol Immunopathol*. 149:66–75.
- Gessani S, Belardelli F (1998). IFN- γ expression in macrophages and its possible biological significance. *Cytokine Growth Factor Rev*. 9:117–123.
- Gillan S, O'Brien R, Hughes AD, Griffin JFT (2010). Identification of immune parameters to differentiate disease states among sheep infected with *Mycobacterium avium* subsp. *paratuberculosis*. *Clin Vaccine Immunol*. 17:108–117.

- González J, Geijo MV, García-Pariente C, Verna A, Corpa JM, Reyes LE, Ferreras MC, Juste RA, García Marín JF, Pérez V (2005). Histopathological classification of lesions associated with natural paratuberculosis infection in cattle. *J Comp Pathol.* 133:184–196.
- Harris NB, Barletta RG (2001). *Mycobacterium avium* subsp. *paratuberculosis* in veterinary medicine. *Clin Microbiol Rev.* 14:489–512.
- Koets AP, Shigetosi E, Sreevatsan S (2015). The within host dynamics of *Mycobacterium avium* ssp. *paratuberculosis* infection in cattle: where time and place matter. *Vet Res.* 46:61.
- Lee H, Stabel JR, Kehrli Jr ME (2001). Cytokine gene expression in ileal tissues of cattle infected with *Mycobacterium paratuberculosis*. *Vet Immunol Immunopathol.* 82:73–85.
- Maarifi G, Maroui MA, Dutrieux J, Dianoux L, Nisole S, Chelbi-Alix MK (2015). Small ubiquitin-like modifier alters IFN response. *J Immunol.* 195:2312–2324.
- Mantovani A, Sica A, Sozzani S, Allavena P, Vecchi A, Locati M (2004). The chemokine system in diverse forms of macrophage activation and polarization. *Trends Immunol.* 25:677–686.
- Martínez FO, Gordon S (2014). The M1 and M2 paradigm of macrophage activation: time for reassessment. *F1000 Prime Rep.* 6:13.
- Nalubamba K, Smeed J, Gossner A, Watkins C, Dalziel R, Hopkins J (2008). Differential expression of pattern recognition receptors in the three pathological forms of sheep paratuberculosis. *Microbes Infect.* 10:598–604.
- Pérez V, García-Marín JF, Badiola JJ (1996). Description and classification of different types of lesion associated with natural paratuberculosis infection in sheep, *J. Comp Pathol.* 114:107–122.
- Pérez V, Tellechea J, Badiola JJ, Gutiérrez M, García-Marín JF (1997). Relation between serologic response and pathologic findings in sheep with naturally acquired paratuberculosis. *Am J Vet Res.* 58:7099–7803.
- Pérez V, Tellechea J, Corpa JM, Gutiérrez M, García-Marín JF (1999). Relation between pathologic findings and cellular immune responses in sheep with naturally acquired paratuberculosis. *Am J Vet Res.* 60:123–127.
- Reddacliff LA, McClure SJ, Whittington RJ (2004). Immunoperoxidase studies of cell mediated immune effector cell populations in early *Mycobacterium avium* subsp. *paratuberculosis* infection in sheep. *Vet Immunol Immunopathol.* 97:149–162.
- Rothkötter HJ, Pabst R, Bailey M (1999). Lymphocyte migration in the intestinal mucosa: entry, transit and emigration of lymphoid cells and the influence of antigen. *Vet Immunol Immunopathol.* 72:157–165.
- Shu D, Subharat S, Wedlock DN, Luo D, de Lisle GW, Buddle BM (2011). Diverse cytokine profile from mesenteric lymph node cells of cull cows severely affected with Johne's disease. *Clin Vaccine Immunol.* 18:1467–1476.

- Smeed JA, Watkins CA, Rhind SM, Hopkins J (2007). Differential cytokine gene expression profiles in the three pathological forms of sheep paratuberculosis. *BMC Vet Res.* 3:18.
- Stabel JR, Robbe-Austerman S (2011). Early immune markers associated with *Mycobacterium avium* subsp. *paratuberculosis* infection in a neonatal calf model. *Clin Vaccine Immunol.* 18:393–405.
- Stabel JR (2007). Host responses to *Mycobacterium avium* subsp. *paratuberculosis*: a complex arsenal. *Anim Health Res Rev.* 7:61–70.
- Sweeney RW, Jones DE, Habecker P, Scott P (1998). Interferon-gamma and interleukin 4 gene expression in cows infected with *Mycobacterium paratuberculosis*. *Am J Vet Res.* 59:842–847.
- Sweeney RW (2011). Pathogenesis of paratuberculosis. *Vet Clin Food Anim.* 27:537–546.
- Tanaka S, Sato M, Onitsuka T, Kamata H, Yokomizo Y (2005). Inflammatory cytokine gene expression in different types of granulomatous lesions during asymptomatic stages of bovine paratuberculosis. *Vet Pathol.* 42:579–588.
- Vázquez P, Garrido JM, Juste RA (2013). Specific antibody and interferon-gamma responses associated with immunopathological forms of bovine paratuberculosis in slaughtered Friesian cattle. *PLoS One.* 8:e64568.
- Verna AE, García-Pariente C, Muñoz M, Moreno O, García-Marin JF, Romano MI, Paolicchi F, Pérez V (2007). Variations in the immunopathological responses of lambs after experimental infection with different strains of *Mycobacterium avium* subsp. *paratuberculosis*. *Zoonoses Public Health.* 54: 243–252.
- Vremec D, O’Keefe M, Hochrein H, Fuchsberger M, Caminschi I, Lahoud M, Shortman K (2007). Production of interferons by dendritic cells, plasmacytoid cells, natural killer cells, and interferon-producing killer dendritic cells. *Blood.* 109:1165–1173.
- Zuñiga J, Torres-García D, Santos-Mendoza T, Rodríguez-Reyna TS, Granados J, Yunis EJ (2012). Cellular and humoral mechanisms involved in the control of tuberculosis. *Clin Dev Immunol.* 193923.

5. DISCUSIÓN GENERAL

GENERAL DISCUSSION

La paratuberculosis sigue siendo una de las enfermedades crónicas de los rumiantes que suscita mayor interés a nivel mundial a causa de las pérdidas económicas que ocasiona ya que las medidas de control con las que se cuenta presentan diversos problemas que restringen su eficacia. Esto se debe, en parte, al desconocimiento de muchos de los factores que participan en la patogenia de esta enfermedad.

Por este motivo, el objetivo principal de esta Tesis es contribuir a mejorar el conocimiento de dicha patogenia, tomando como referencia el estudio de factores que puedan estar relacionados con los diferentes tipos de lesión que se observan en la infección por *Map* y que, según se ha demostrado en estudios previos, están asociados a las fases de desarrollo de la paratuberculosis, desde formas de latencia, subclínicas, hasta fases avanzadas o clínicas (Pérez *et al.*, 1996; González *et al.*, 2005; Brady *et al.*, 2008). El conocimiento de cómo operan dichos factores en cada forma lesional y por lo tanto en cada fase de la enfermedad, podría permitir en un futuro, el diseño de estrategias para modular la respuesta inmunitaria del hospedador hacia formas de control de la infección, el perfeccionamiento de los métodos de diagnóstico y el desarrollo de vacunas más eficaces.

En este trabajo, se han realizado cuatro estudios, dos de ellos dirigidos a conocer la influencia del agente etiológico, y los restantes, a estudiar algunos factores que dependen del hospedador, mediante la caracterización de las células que forman las lesiones granulomatosas, en concreto las variaciones en la producción de citocinas y mediadores de la inflamación según el tipo de lesión. Los resultados obtenidos en cada uno de estos trabajos se discuten y contrastan a continuación con los obtenidos en otros estudios sobre esta enfermedad.

En primer lugar, se realizó una infección experimental sobre un modelo ovino para valorar no solo la capacidad de reproducir la infección de

forma experimental en esa especie sino, fundamentalmente, la influencia que distintas cepas de *Map* pueden tener sobre la respuesta inmunitaria y el desarrollo de lesiones en el hospedador. A diferencia de estudios anteriores, en nuestro caso se han empleado cepas previamente conocidas y tipificadas como Tipo S o C procedentes de cultivo puro, incluyendo la cepa de referencia K-10 de *Map*.

En trabajos previos se ha comprobado que el resultado de la infección experimental con *Map* es diferente según el inóculo se haya purificado directamente de tejido intestinal de animales infectados o bien sea producto del aislamiento y posterior crecimiento en medios de cultivo de laboratorio, si bien se habían utilizado cepas de distinto origen (Stewart *et al.*, 2006, 2007; Begg *et al.*, 2010). Por ello, el segundo estudio, basado en una infección experimental en ovinos, se llevó a cabo para conocer la influencia del crecimiento en medios de cultivo de un mismo aislado Tipo S de *Map*, sobre la patogenia de la enfermedad. En este estudio, el inóculo procedente de un mismo animal se administró directamente tras su purificación del intestino de una oveja enferma o después de su aislamiento y crecimiento en laboratorio.

Los resultados del primer estudio reflejaron que el ganado ovino se puede infectar experimentalmente con cepas Tipo S y con cepas Tipo C de *Map*, tal y como se ha descrito previamente (Stewart *et al.*, 2004; Verna *et al.*, 2007), aunque con diferencias en la respuesta inmunitaria y especialmente en el desarrollo de las lesiones en función de la cepa. Las lesiones inducidas por las cepas C se caracterizan por tener un carácter delimitado, presentar abundante necrosis, un número elevado de células gigantes y distintos grados de fibrosis, a diferencia de las observadas en los animales infectados con las cepas ovinas. En estudios previos, se describen hallazgos similares con cepas Tipo C en corderos a los 150 dpi (Verna *et al.*, 2007). Estos resultados situarían a estas lesiones más cercanas a las descritas

en casos naturales de paratuberculosis bovina (González *et al.*, 2005) a diferencia de las lesiones ovinas, donde la presencia de células gigantes es poco común (Pérez *et al.*, 1996; Clarke, 1997). Dado que en el presente estudio y en el de Verna *et al.* (2007) se emplearon diferentes cepas Tipo C con resultados similares, parece posible que la diferencia en la morfología de las lesiones sea consecuencia de la diferente interacción entre el hospedador ovino y una cepa Tipo C, al contrario de lo que sucede con cepas más adaptadas a dicha especie como las S.

En este primer estudio también se observaron diferencias en la evolución de las lesiones a lo largo del experimento, que se extendió hasta los 390 dpi. A los 150 dpi, algunos de los corderos infectados con cepas Tipo C mostraron lesiones difusas distribuidas por zonas de la mucosa intestinal no asociadas al tejido linfoide que han sido descritas en estados avanzados de la enfermedad (Pérez *et al.*, 1996; González *et al.*, 2005; Verna *et al.*, 2007; Delgado *et al.*, 2013). En cambio, las lesiones observadas al final del experimento (390 dpi) en animales de estos mismos grupos reflejaron un marcado descenso en su gravedad, con tendencia a la resolución. Estas lesiones estaban constituidas por un pequeño número de granulomas bien delimitados y fibrosados, que se localizaban mayoritariamente en el tejido linfoide intestinal. Sin embargo, en el grupo de corderos infectados con cepas Tipo S las lesiones fueron de menor entidad y no mostraron un descenso de su gravedad a lo largo del experimento. En este sentido, Verna *et al.* (2007) también describieron fibrosis en los granulomas asociados a las cepas Tipo C, pero únicamente a los 150 dpi, sin conocer su posterior evolución, ya que su estudio finalizó en ese momento.

Los granulomas con diversos grados de fibrosis se han considerado como lesiones “regresivas” y han sido encontrados en corderos vacunados e infectados experimentalmente con *Map* (Juste *et al.*, 1994; Gwozdz *et al.*,

2000) y en cobayas infectadas experimentalmente con *Mtb* (Gil *et al.*, 2010) como resultado de la contención de la infección. Nuestros resultados sugieren que, en los corderos infectados con cepas Tipo C, la infección se habría contenido y, en caso de haberse prolongado el experimento, incluso podríamos suponer que las lesiones habrían podido regresar completamente y el intestino recuperar su morfología normal. La existencia de un cordero del grupo infectado con la cepa bovina K-10, sacrificado a los 390 dpi, sin lesiones y en el cual no se pudo demostrar la presencia de ADN de *Map* en los tejidos, a pesar de que mostró una respuesta inmunitaria celular específica, apoyaría esta hipótesis.

En los pequeños rumiantes vacunados frente a paratuberculosis, la eficacia de la vacuna para controlar el progreso de la infección se asocia con la inducción de una respuesta inmunitaria celular efectiva (Gwozdz *et al.*, 2000; Begg y Griffin, 2005). En este sentido, en nuestro estudio, los corderos infectados con las cepas Tipo C mostraron una intensa liberación de IFN- γ en sangre periférica, tras su estimulación con PPD aviar, lo que podría relacionarse con la regresión de las lesiones. De forma similar, Delgado *et al.* (2012, 2013) también asociaron un menor desarrollo lesional, en ovinos adultos infectados con *Map* respecto a corderos jóvenes, a la mayor respuesta inmunitaria desarrollada en los primeros. Nuestros resultados también coinciden con un estudio previo con ovejas merinas en el que se observó que con las cepas Tipo S la respuesta celular era más débil en comparación con las Tipo C, si bien las lesiones no fueron evaluadas (Stewart *et al.*, 2004).

Según nuestro estudio, la infección inducida por las cepas Tipo C alcanzaría su máximo desarrollo en torno a los 150 dpi. A partir de ese momento, los corderos serían capaces de establecer una respuesta inmunitaria eficiente que influiría en la regresión de las lesiones observadas a

los 390 dpi. Hubiera sido interesante prolongar el estudio de estos animales durante un periodo de tiempo más largo y con sacrificios a intervalos de tiempo menores para confirmar o no la resolución completa de las lesiones. En cambio, los corderos infectados con las cepas Tipo S únicamente mostraron lesiones granulomatosas de tipo focal localizadas en el tejido linfoide intestinal sin una respuesta inmunitaria periférica evidente. Estas lesiones, descritas también en otras infecciones experimentales en ovejas (Juste *et al.*, 1994; Begg *et al.*, 2010; Delgado *et al.*, 2013) y en casos naturales en animales adultos, se atribuyen a fases latentes o infecciones recientes (Pérez *et al.*, 1996). La presencia de lesiones granulomatosas similares a los 150 y 390 dpi en los animales infectados del presente experimento reforzaría la hipótesis del carácter latente de las mismas.

Tanto en casos de infección natural como en infecciones experimentales se ha descrito que la mayoría de las ovejas con lesiones focales muestran una fuerte respuesta inmunitaria periférica celular (Pérez *et al.*, 1999; Delgado *et al.*, 2012). En cambio, en el presente estudio, y de forma esporádica, solo algunos corderos fueron positivos al IGRA, pero sin diferencias significativas al compararlos con los controles, a pesar de que mediante IDR si se apreció una respuesta inmunitaria celular aunque leve. Este hecho podría indicar que la IDR sería más sensible que el IGRA, de acuerdo con estudios previos (Pérez *et al.*, 1999; Dunn *et al.*, 2005). Sin embargo, difiere de los resultados obtenidos en los grupos infectados con las cepas Tipo C, donde la respuesta a la IDR fue similar a los grupos inoculados con las cepas Tipo S, aunque con mayor producción de IFN- γ .

En casos naturales de paratuberculosis bovina Vázquez *et al.* (2013) consideran la posibilidad de que los animales con lesiones focales no desarrollen una respuesta inmunitaria periférica celular con niveles de IFN- γ detectable y se asocien a un estado de resistencia. Según nuestros resultados

esto habría ocurrido mayoritariamente en los corderos infectados con las cepas Tipo S, por lo que de acuerdo a lo señalado en estudios *in vitro* (Janagama *et al.*, 2006; Abendaño *et al.*, 2013), existirían diferencias en la respuesta inmunitaria periférica inducida por ambos tipos de cepas, C y S.

Por otra parte, los resultados de este estudio muestran que la respuesta inmunitaria periférica observada a lo largo del experimento no apoya el modelo estándar de inmunidad frente a la paratuberculosis. Según este modelo en las etapas tempranas de la enfermedad existiría una respuesta de tipo Th1, asociada a una elevada expresión periférica de IFN- γ , que disminuye conforme la enfermedad y las lesiones avanzan bajo un predominio de una respuesta humoral Th2 (Stabel, 2000a; Whittington *et al.*, 2012). Los corderos del presente estudio infectados con cepas Tipo C reflejaron una respuesta mixta, celular y humoral, entre los 120 y 330 dpi, probablemente en consonancia con una mayor respuesta inflamatoria, mientras que en aquellos infectados con las cepas Tipo S, las lesiones fueron mínimas y sin producción de IFN- γ . Estos resultados coinciden con otros estudios que cuestionan el predominio de la respuesta Th1 en las fases tempranas de la infección por *Map* (Stewart *et al.*, 2004; Begg *et al.*, 2010; Whittington *et al.*, 2012) y con lo señalado por Vázquez *et al.* (2013) en casos naturales en la especie bovina.

A diferencia de lo observado en otras infecciones experimentales con cepas Tipo S llevadas a cabo por nuestro grupo de investigación (Verna *et al.*, 2007; Delgado *et al.*, 2013), en los corderos del ensayo actual no se identificaron lesiones difusas. Posiblemente, los resultados obtenidos en nuestro experimento imitarían lo que sucede en condiciones naturales, donde la mayoría de las lesiones también son focales y latentes (Pérez *et al.*, 1996; Vázquez *et al.*, 2013). Se refuerza esta hipótesis con el estudio llevado a cabo por Begg *et al.* (2010) en corderos infectados con cepas Tipo S, en los

cuales únicamente observaron lesiones difusas de forma esporádica en animales sacrificados entre los 10 y 19 mpi. Así, parece factible que de prolongarse la duración de la infección, las lesiones podrían progresar hacia formas difusas en algunos animales infectados con cepas Tipo S. Sin embargo, tampoco se puede descartar una menor patogenicidad de las cepas Tipo S empleadas. En este sentido, se han documentado diferencias en la patogenicidad entre diferentes tipos de cepas de *Map* (Verna *et al.*, 2007; Begg y Whittington, 2008) como hemos demostrado en el presente estudio entre las cepas Tipo C, ya que el aislado bovino 764 indujo una respuesta inmunitaria y lesional más intensa que la cepa K-10. Sin embargo, en este estudio no se observaron diferencias entre las dos cepas Tipo S empleadas, ambas aisladas de casos clínicos de paratuberculosis, aunque se ha considerado que las cepas ovinas pigmentadas son más patógenas (Taylor, 1951; Stamp y Watt, 1954).

La ausencia de lesiones difusas unida a la falta de una respuesta inmunitaria celular marcada en los animales infectados con cepas S, podría indicar que su virulencia se ha atenuado tras su paso por cultivo, lo que no parece haber ocurrido con las cepas Tipo C que han mostrado mayor patogenicidad. En este sentido, existen estudios previos donde no se ha podido reproducir la paratuberculosis experimentalmente con cepas de *Map* ovinas cultivadas en laboratorio (Thorel *et al.*, 1992; Pérez, 1992). Esta hipótesis también podría explicar la menor patogenicidad encontrada para la cepa K-10, que presenta numerosos pases por cultivo (Radosevich *et al.*, 2007; Begg y Whittington, 2008).

De todas formas hay que considerar que, si bien en varios trabajos se ha demostrado que las infecciones con *Map* purificado a partir de un preparado intestinal de ovejas enfermas son más fácilmente reproducibles que a partir de cultivo puro (Stewart *et al.*, 2004; Begg *et al.*, 2005; Begg y

Whittington, 2008), existen otros donde no se aprecian diferencias tan claras (Begg *et al.*, 2010). En todos estos estudios tanto el homogeneizado como el cultivo procedían de rebaños diferentes, por lo que no se puede descartar la posibilidad de que se hayan inoculado diferentes cepas (Stewart *et al.*, 2004).

Teniendo en cuenta los resultados del primer experimento y los antecedentes previos, en el segundo estudio experimental que compone esta Tesis Doctoral, se infectaron ovinos por vía oral con *Map* purificado directamente de la mucosa intestinal de una oveja enferma, y con el aislado procedente de dicho inóculo, tras su crecimiento en un medio de cultivo. En el diseño del estudio se tuvo en cuenta la posibilidad de que en el inóculo hubiera cepas de *Map* que no pudiesen ser aisladas en medios de cultivo. Para evitarlo en medida de lo posible, se emplearon métodos bacteriológicos recomendados para el aislamiento de cepas ovinas (Adúriz *et al.*, 1995; Hines II *et al.*, 2007; Whittington *et al.*, 2011; Stevenson, 2015).

La necesidad de un tejido homogeneizado fresco para evitar la pérdida de viabilidad que pudiera ocasionar la congelación prolongada, y el crecimiento lento de las cepas Tipo S supuso que la infección experimental con la cepa cultivada se llevase cabo un año más tarde. Para minimizar las variaciones entre los dos desafíos, se mantuvieron las mismas condiciones en cuanto al origen de los animales y al diseño experimental. En ambos experimentos se emplearon corderos del mismo rebaño y época de paridera y, si bien es cierto que no se realizaron estudios genéticos acerca de la resistencia a la infección por *Map*, se podría asumir que no hubo variaciones relevantes entre los corderos empleados.

En este estudio se pudo constatar una clara diferencia tanto en el número e intensidad de las lesiones como en la respuesta inmunitaria desarrollada en los corderos, que fueron significativamente más elevadas en los infectados con el inóculo que en los que recibieron el cultivo. Teniendo en

cuenta todas las consideraciones previas, la principal causa que podría explicar dichas diferencias sería el paso de la micobacteria por los medios de cultivo, que ocasionaría cambios en las propiedades patógenas de *Map*. Tampoco se puede descartar que, a pesar del pre-tratamiento enzimático y antibiótico utilizado en la preparación del inóculo, la presencia de otros microorganismos haya potenciado el progreso de la infección (Wu *et al.*, 2007; Begg *et al.*, 2010) o favorecido cambios en el microambiente para una más fácil instauración (Tomasello *et al.*, 2011). Se han documentado pérdidas de virulencia tras varios cultivos *in vitro* (Rosseels y Huygen, 2008) asociados con cambios en el genotipo de *Map* (Bull *et al.*, 2013; Kasnitz *et al.*, 2013). A pesar de que en nuestro estudio el número de pases ha sido reducido, hay estudios donde se ha observado que el factor de virulencia *kdpC* de *Map* solo se encuentra activado en las muestras obtenidas directamente de vacas infectadas y no en los aislados de cultivo (Wu *et al.*, 2007). En algunos trabajos se ha señalado que es común que en algunos microorganismos, en particular los de crecimiento lento, no se expresen genes asociados a la patogenicidad dado que no son necesarios para la supervivencia *in vitro* (DiRita *et al.*, 2000; Zheng *et al.*, 2008). Algo similar podría haber ocurrido en el presente experimento, por lo que serían necesarios análisis genéticos concretos de este aislado para su completa caracterización.

El menor poder patógeno del inóculo cultivado podría estar también relacionado con la dificultad que tienen las cepas Tipo S para su aislamiento y multiplicación en laboratorio (Adúriz *et al.*, 1995; Whittington *et al.*, 1999, 2011) de modo que, de forma adaptativa, exista una selección de los clones de *Map* más adecuados para el cultivo que no tienen por qué coincidir con los más virulentos, que sí estarían presentes en el purificado completo. Esto también explicaría por qué los aislados de Tipo C empleados en el primer experimento mostraron todos un poder patógeno mucho más elevado,

valorado por la intensidad de la respuesta inmunitaria y las lesiones, que los aislados ovinos.

En la bibliografía consultada son numerosas las infecciones con cepas bovinas aisladas en laboratorio que han reproducido la infección (Begg y Whittington, 2008) mientras que en el caso de cepas ovinas, los resultados han sido muy variables y aunque hay estudios que han logrado desarrollar la enfermedad clínica (Stewart *et al.*, 2004; Begg *et al.*, 2005) en la mayoría de los casos, las infecciones han sido inaparentes (Thorel *et al.*, 1992; Begg *et al.*, 2005).

En los corderos infectados con el homogeneizado intestinal, se observaron lesiones granulomatosas más graves, en número y localización en zonas de la lámina propia intestinal, según el modelo de desarrollo lesional propuesto con anterioridad para explicar la patogenia de la enfermedad (Juste *et al.*, 1994; Kurade *et al.*, 2004; Delgado *et al.*, 2013). En cambio, los animales inoculados con la cepa cultivada o bien no mostraron lesiones o fueron solo de tipo focal, de carácter inicial o latente (Pérez *et al.*, 1996; Delgado *et al.*, 2013), lo que indicaría que los corderos de este grupo fueron capaces de controlar la infección mejor que los infectados con el homogeneizado. Estos hallazgos se acompañaban de una débil y discontinua respuesta inmunitaria periférica celular, similar a la encontrada en bovinos infectados naturalmente con formas de lesión semejantes (Vázquez *et al.*, 2013), lo que lleva a plantear la hipótesis de que el control efectivo estaría más relacionado con la respuesta que se desarrolla a nivel local que no tiene por qué ser idéntica a la periférica (Charavaryamath *et al.*, 2013). Por otro lado, la fuerte respuesta humoral y celular periférica mostrada por los corderos infectados con el homogeneizado refuerza la hipótesis de que la intensidad de la respuesta periférica se asociaría con la extensión de las lesiones, como ya señalaron Vázquez *et al.* (2013).

En ambos grupos experimentales la tasa de aislamiento de *Map* en los tejidos fue muy baja. En el grupo infectado con el homogeneizado se aisló *Map* sólo en la válvula ileocecal de la mitad de los animales mientras que en el grupo inoculado con la cepa cultivada no hubo aislamientos positivos. Este resultado no es de extrañar dada la reducida extensión de las lesiones y presumiblemente de la infección, y las dificultades que presentan las cepas Tipo S para su cultivo (Whittington *et al.*, 2011).

Otro factor que también ha condicionado el éxito de las infecciones experimentales ha sido la dosis de *Map* administrada a los animales (Nisbet *et al.*, 1962; Hines II *et al.*, 2007; Begg y Whittington, 2008; Delgado *et al.*, 2013). En nuestros experimentos se han utilizado dosis similares a las empleadas previamente por otros autores para reproducir la infección, utilizando otras cepas o el homogeneizado (Stewart *et al.*, 2004; Verna *et al.*, 2007; Begg y Whittington, 2008; Delgado *et al.*, 2013). Sin embargo, no se puede descartar que, si la dosis del inóculo hubiera sido mayor o bien se hubiera administrado durante más tiempo, se pudiera haber conseguido una mejor evidencia de la infección.

Estos dos estudios experimentales han puesto de manifiesto la importancia del tejido linfoide intestinal como lugar de establecimiento de la infección, independientemente de la cepa, dado que la mayoría de las lesiones aparecen en esa localización, coincidiendo con lo señalado en trabajos previos (Juste *et al.*, 1994; Pérez *et al.*, 1996; Kurade *et al.*, 2004; Verna *et al.*, 2007; Delgado *et al.*, 2013). Así, las placas de Peyer actuarían como punto de entrada y lugar de permanencia de *Map* formando granulomas focales que pueden persistir durante largos periodos de tiempo (formas de latencia o de resistencia), ya que es en esta localización donde se han encontrado, en todos los casos, lesiones focales. Respecto a la distribución e intensidad de las lesiones, se observaron diferencias

significativas entre las distintas partes del intestino y entre los animales, al igual que sucede en casos naturales y experimentales (Nisbet *et al.*, 1962; Begg y Whittington, 2008; Begg *et al.*, 2010; Delgado *et al.*, 2013). En todos los grupos desafiados, la placa de Peyer yeyunal fue la región que más lesiones presentó seguida de la válvula ileocecal mientras que en las placas de Peyer ileales las lesiones fueron minoritarias y aparecieron exclusivamente en los grupos infectados con las cepas Tipo C. Estos hallazgos han sido documentados previamente (Valheim *et al.*, 2004; Delgado *et al.*, 2013) e indicarían un patrón funcional distinto entre las placas de Peyer yeyunales e ileales que muestran diferencias en su morfología y distribución de linfocitos (Corpa *et al.*, 2001; Valheim *et al.*, 2004).

En los nódulos linfáticos las lesiones fueron escasas y solo aparecían cuando ya estaban presentes en el intestino. Estos resultados, apoyados por observaciones previas (Juste *et al.*, 1994; Delgado *et al.*, 2013; Muñoz, 2014; Krüger *et al.*, 2015), confirmarían el protagonismo del tejido linfoide intestinal en el comienzo de la infección por *Map* en la especie ovina, que puede ser detectada en los nódulos linfáticos mesentéricos una vez que se ha instaurado por completo en el intestino.

El cultivo de *Map* a partir muestras ovinas es dificultoso y lento (Juste *et al.*, 1991; Whittington *et al.*, 2011). Por ello en nuestros estudios se ha utilizado la PCR anidada para la identificación de *Map* en los animales infectados como complemento a los estudios histopatológicos ya que este método se había empleado satisfactoriamente en otros trabajos donde demostró tener una mayor sensibilidad que el cultivo u otras técnicas de PCR (Bull *et al.*, 2003; Stabel y Bannantine, 2005; Gao *et al.*, 2009; Delgado *et al.*, 2013). Sin embargo, se debe tener en cuenta que a través de la PCR se identifica ADN que puede proceder de bacilos no viables. En el primero de los estudios, se pudo identificar ADN micobacteriano en todos los animales

infectados (excepto en uno perteneciente al grupo K-10 sacrificado a los 390 dpi en el que no se apreció ninguna lesión), a pesar del bajo recuento de granulomas que mostraban los animales a los 390 dpi. Al igual que lo sucedido en un estudio anterior (Delgado *et al.*, 2013), dos corderos infectados con cepas Tipo S que no presentaban lesiones fueron positivos a PCR. En el segundo experimento, se identificó ADN micobacteriano en la mitad de los animales infectados con la cepa cultivada y en todos los animales del grupo inoculado con el homogeneizado purificado. Por el contrario, a pesar de la notoria prevalencia de lesiones en las placas de Peyer yeyunales, no se observaron diferencias en la positividad mediante PCR entre las regiones del intestino analizadas, lo que sugiere que el ADN de *Map* puede estar presente en diferentes puntos del intestino delgado sin que se observen lesiones evidentes, que sólo aparecerían en localizaciones concretas, posiblemente debido a factores locales.

Aunque en esta Tesis Doctoral no se han investigado las causas que determinarían las distintas respuestas del hospedador en función de la cepa en estudios recientes realizados en macrófagos bovinos infectados *in vitro* con diferentes cepas de *Map* se ha puesto de manifiesto que los perfiles de citocinas expresados han sido diferentes (Janagama *et al.*, 2006; Abendaño *et al.*, 2013). Los macrófagos infectados con cepas Tipo C presentaron un alto grado de supervivencia micobacteriana intracelular asociada a una respuesta anti-inflamatoria con una elevada expresión de IL-10 y, por el contrario, los macrófagos infectados con cepas Tipo S, con menor persistencia intracelular, mostraron un predominio de IL-4, citocina de carácter pro-inflamatorio. Estos hallazgos indicarían que la supervivencia de *Map* en los macrófagos estaría estrechamente relacionada con el hospedador del cual procede el aislado (Abendaño *et al.*, 2013), apoyando nuestros resultados, donde las lesiones en los corderos infectado con cepas Tipo C tienen un carácter regresivo, con

tendencia a disminuir de intensidad, mientras que las lesiones asociadas a las cepas Tipo S serían de carácter latente.

Los resultados de estos estudios así como nuestros resultados, sugieren que los macrófagos juegan un papel muy importante en el desarrollo de las lesiones, como reflejo de la interacción entre el patógeno y el hospedador en la paratuberculosis. La segunda parte de esta Tesis Doctoral ha tenido como objetivo conocer el papel que jugarían algunos factores del hospedador en la patogenia de la paratuberculosis mediante la valoración de las diferencias fenotípicas en algunas de las células inflamatorias que se observan en los diferentes tipos de lesión. Los macrófagos son las células principales que aparecen en la respuesta inflamatoria granulomatosa; teniendo en cuenta que los animales infectados por *Map* muestran una variabilidad de lesiones, asociadas a las distintas fases de la enfermedad, y que en todas ellas el macrófago es la célula principal, parece plausible pensar que puedan existir diferencias fenotípicas en estas células según la forma lesional.

Esta hipótesis se confirmó con los resultados del tercer estudio de esta Tesis Doctoral, que sugieren que tras la infección por *Map*, dependiendo del tipo de lesión, se distinguen dos fenotipos de macrófagos funcionalmente diferentes según su polarización hacia perfiles pro- o anti-inflamatorios, denominados M1 y M2 respectivamente (Sica y Mantovani, 2012; Martínez y Gordon, 2014). En las lesiones focales, de carácter latente, localizadas en el tejido linfoide, predominarían los macrófagos M1 o clásicamente activados implicados en la secreción de citocinas pro-inflamatorias, mientras que los macrófagos M2 o alternativamente activados, con funciones inmunorreguladoras y de remodelación tisular, serían mayoritarios en lesiones difusas multibacilares (Mantovani *et al.*, 2004; Sica y Mantovani, 2012; Ka *et al.*, 2014; Martínez y Gordon, 2014). Para llegar a esta conclusión,

hemos empleado métodos inmunohistoquímicos que han permitido valorar la expresión diferencial de diferentes citocinas y mediadores de la inflamación. Así, los macrófagos presentes en las lesiones granulomatosas focales expresan marcadores de tipo M1, iNOS y TNF- α , mientras que en la lesiones difusas multibacilares expresan TGF- β , CD163 e IL-10, característicos de un perfil M2. Para valorar su expresión, se ha empleado el índice H, un método semiquantitativo que ha demostrado su utilidad para evaluar la inmunopositividad y poder comparar estadísticamente los niveles de expresión de los marcadores. Este método ya había sido previamente utilizado para cuantificar determinados receptores hormonales en células neoplásicas (Detre *et al.*, 1995) y diferentes poblaciones celulares (Charafe-Jauffret *et al.*, 2004).

Aunque la polarización de los macrófagos ha sido investigada en otras micobacteriosis como la tuberculosis (Huang *et al.*, 2015; Marino *et al.*, 2015), los estudios sobre este aspecto son escasos en paratuberculosis. En un trabajo reciente llevado a cabo en monocitos sanguíneos de terneros infectados subclínicamente con *Map*, se ha descrito una población heterogénea compuesta por macrófagos clásica y alternativamente activados (Thirunavukkarasu *et al.*, 2015). En este estudio, los animales con bajos niveles periféricos de IFN- γ mostraron una mayor proporción de monocitos que expresaban CD163 (marcador M2) y de forma minoritaria iNOS (marcador M1), de acuerdo con nuestros resultados.

Sin embargo, no existen estudios sobre polarización de macrófagos en las poblaciones que forman parte de las lesiones intestinales. En nuestro estudio, los macrófagos de las lesiones de tipo focal, típicos de la fase subclínica (Pérez *et al.*, 1996; González *et al.*, 2005; Delgado *et al.*, 2013), mostraron un fenotipo M1 con escaso número de BAAR y elevados niveles de citocinas pro-inflamatorias iNOS y TNF- α (Mantovani *et al.*, 2004; Martínez y

Gordon, 2014), de forma similar a lo que sucede en las lesiones granulomatosas iniciales producidas tras la infección por *M. bovis* (Pereira-Suárez *et al.*, 2006; Palmer *et al.*, 2007). Se sabe que IFN- γ y TNF- α son los principales factores estimuladores hacia el fenotipo M1 (Mantovani *et al.*, 2004; Martínez y Gordon, 2014). Se ha descrito la producción de TNF- α por los macrófagos tras la infección por otras micobacterias y se considera que esta citocina es, junto al IFN- γ , la principal molécula endógena inductora de la inhibición del crecimiento de *Map* (Flesch *et al.*, 1994).

Por su parte iNOS induce la síntesis de óxido nítrico que ha demostrado ser una molécula efectora de los mecanismos de eliminación de la micobacteria por los macrófagos (Hostetter *et al.*, 2005; Palmer *et al.*, 2007) y cuya expresión se ha relacionado con las fases subclínicas de la paratuberculosis (Khalifeh *et al.*, 2009). La existencia de un perfil M1 en las formas focales reforzaría la hipótesis del efecto protector asociado a las lesiones iniciales, de tipo focal, de la paratuberculosis, en las que el animal no muestra una respuesta inflamatoria desmesurada, y que podrían permanecer latentes en el tiempo en aquellos animales subclínicamente infectados, tal y como ha sucedido en los dos experimentos de esta Tesis con las cepas Tipo S.

En cambio, en los macrófagos de las lesiones multibacilares se desarrolla un perfil de tipo M2, con elevada expresión de CD163, IL-10 y TGF- β y bajos niveles de iNOS y TNF- α . Dentro de los subtipos de los macrófagos M2, los de las lesiones multibacilares pertenecerían al subtipo M2c, por la elevada presencia de IL-10, TGF- β y CD163, y ejercerían funciones anti-inflamatorias e inmunorreguladoras (Mantovani *et al.*, 2004; Martínez y Gordon, 2014) descritas también en los estadios tardíos y graves de la tuberculosis (Lugo-Villarino *et al.*, 2011) y que, según se ha sugerido, también podrían aparecer en paratuberculosis (Khalifeh *et al.*, 2009; Abendaño *et al.*, 2013). Las funciones anti-inflamatorias de los macrófagos en este tipo de

lesión explicarían la elevada carga de BAAR (Pérez *et al.*, 1996; Tanaka *et al.*, 2005; Muñoz *et al.*, 2009), escasa presencia de otras células inflamatorias como linfocitos (González *et al.*, 2005) y la baja expresión de iNOS (Hostetter *et al.*, 2005) y de TNF- α al igual que lo descrito en nuestro estudio. Las acciones inmunorreguladoras se relacionarían fundamentalmente con la producción de TGF- β e IL-10, las cuales disminuirían la síntesis de NO (Mills *et al.*, 2000; Khalifeh *et al.*, 2009; Muñoz *et al.*, 2009).

La expresión de MHC II, molécula que juega un papel importante en la presentación de antígenos, se ha descrito previamente en los macrófagos M1 (Mantovani *et al.*, 2004; Benoit *et al.*, 2008) pero de forma débil en aquellos con bajo número de micobacterias en las fases iniciales de la paratuberculosis caprina (Valheim *et al.*, 2004; Krüger *et al.*, 2015) tal y como se observa en nuestro trabajo. En esta línea, hay estudios *in vitro* donde se ha reflejado que, poco tiempo después de la infección con *Map*, los monocitos disminuyen la expresión de MHC II (Weiss *et al.*, 2001). De manera opuesta, la expresión de MHC II fue significativamente elevada en lesiones difusas multibacilares con elevada carga de BAAR, en consonancia con otros estudios (Lybeck *et al.*, 2013; Krüger *et al.*, 2015). Sin embargo, Navarro *et al.* (1998) no observaron inmunopositividad de este marcador en las células epitelioides con gran número de BAAR.

NRAMP1 es una proteína estrechamente relacionada con la resistencia innata a los patógenos intracelulares (Benoit *et al.*, 2008) que disminuiría la susceptibilidad a la lisis del fagosoma en macrófagos infectados con *M. tuberculosis* (Simeone *et al.*, 2015). La presencia de NRAMP1 en las lesiones multibacilares indicaría un estado de activación de los macrófagos ya que en fases inactivas su presencia es residual (Delgado *et al.*, 2009). En nuestro estudio, la fuerte expresión de NRAMP1 en lesiones multibacilares, que debería haber provocado la inhibición de la capacidad de la micobacteria

para bloquear la maduración del fagosoma y evitar su lisis (Frehel *et al.*, 2002; Simeone *et al.*, 2015), no sería eficaz ya que estas lesiones se caracterizan por el crecimiento y multiplicación de *Map*. Estos resultados, en apariencia contradictorios, deberían ser corroborados por nuevos estudios sobre el tema.

En el caso de las lesiones paucibacilares, los macrófagos se polarizan hacia fenotipos M1, con una fuerte expresión de iNOS y bajos índices H de CD163, IL-10 y TGF- β coincidiendo con lo señalado por otros autores (Mantovani *et al.*, 2004; Martínez y Gordon, 2014). Sin embargo, a diferencia de las lesiones focales, los granulomas paucibacilares expresan bajos niveles de TNF- α que, según otros estudios, se relacionaría con la presencia de numerosos linfocitos T en ese tipo de lesión (Navarro *et al.*, 1998; Tanaka *et al.*, 2005; Smeed *et al.*, 2007) al igual que sucede en la enfermedad de Crohn en humanos (Hermon-Taylor *et al.*, 2000). Otro hallazgo interesante de este estudio fueron las diferencias existentes entre las lesiones focales y difusas en los niveles de expresión de calprotectina, proteína citosólica de los monocitos que se expresa en los macrófagos recientemente migrados desde la sangre (Soulas *et al.*, 2011). Este hecho confirmaría que los macrófagos de las lesiones difusas habrían sido recientemente reclutados de la circulación sanguínea, respaldando el carácter activo y progresivo de este tipo de forma lesional observada en los casos graves y avanzados de paratuberculosis (Pérez *et al.*, 1996; González *et al.*, 2005; Vázquez *et al.*, 2013). Por el contrario, los macrófagos en las lesiones focales, más que estar siendo reclutados a partir de los monocitos sanguíneos, se estarían multiplicando *in situ*, hecho confirmado por la elevada expresión de la proteína de proliferación Ki67 y que estaría de acuerdo con trabajos previos (Scholzen *et al.*, 2000; Valheim *et al.*, 2004). Todas estas hallazgos deben ser analizados cuidadosamente dado el carácter dinámico de las lesiones asociadas a la infección por *Map* que hacen que en un mismo animal, y en distintas zonas del intestino, puedan

coexistir diferentes formas lesionales (González *et al.*, 2005; Koets *et al.*, 2015).

Las lesiones multifocales tendrían un carácter transitorio hacia formas difusas y se compondrían mayoritariamente de macrófagos M1, dada la elevada expresión de iNOS y TNF- α , pero se alejarían del perfil típico de las lesiones focales por la baja expresión de Ki67 detectada, lo que indica que dichas formas ya habrían abandonado su carácter de latencia y comenzado a reclutar nuevos macrófagos, progresando hacia formas difusas más graves, posiblemente multibacilares, con un incremento en la expresión de TGF- β (Khalifeh *et al.*, 2009; Muñoz *et al.*, 2009) y que es la forma más frecuente de lesión difusa (Pérez *et al.*, 1996; González *et al.*, 2005; Vázquez *et al.*, 2013).

De acuerdo con otros estudios (Ackermann *et al.*, 1994; Pérez *et al.*, 1996; Ohsawa *et al.*, 2004; Reddacliff *et al.*, 2004; Valheim *et al.*, 2004), las proteínas Iba-1, CD68 y lisozima se podrían considerar marcadores generales de macrófagos puesto que en nuestro trabajo se han identificado en todos los tipos de lesión. Sin embargo, la intensidad de la expresión de las dos últimas está directamente relacionada con la presencia de BAAR (Huang *et al.*, 2015), lo cual, a su vez, estaría en relación con un incremento del número de fagolisosomas donde estarían las micobacterias, ya que CD68 se localiza en los lisosomas (Keshav *et al.*, 1991) y la producción de lisozima aumenta tras la fagocitosis (Reddacliff *et al.*, 2004). En cuanto a la proteína Iba-1, la ausencia de diferencias entre los tipos lesionales le adjudicaría un carácter de marcador general de macrófagos que no variaría según el estado de polarización de estas células.

En los resultados de este trabajo se ha observado que, además de otros mediadores como el iNOS y TNF- α , el IFN- γ es la principal molécula que participa en activación clásica y por tanto en la polarización hacia el fenotipo M1 de los macrófagos presentes en las lesiones focales (Mantovani *et al.*,

2004; Martínez y Gordon, 2014). El IFN- γ es una citocina esencial en la defensa frente a patógenos intracelulares -incluido *Map*- a través de la activación de fagocitosis, mediante la inducción de la síntesis de reactivos oxigenados y nitrogenados de acción bactericida (Cooper *et al.*, 2002; Stabel, 2006; Arsenault *et al.*, 2014). Las lesiones granulomatosas focales se asocian generalmente con elevados niveles plasmáticos de IFN- γ obtenidos la estimulación de la sangre periférica de los animales que las presentan con antígenos micobacterianos aviáres, mientras que sucede lo contrario con las formas difusas multibacilares (Pérez *et al.*, 1999; Valheim *et al.*, 2004). Sin embargo, son escasos los estudios que evalúan la expresión local de IFN- γ en el intestino en relación con los distintos tipos de lesión, y casi todos han empleado técnicas de expresión génica (Lee *et al.*, 2001; Coussens *et al.*, 2004; Shu *et al.*, 2011). Por ello, en el último trabajo de esta Tesis Doctoral se ha querido valorar, mediante técnicas inmunohistoquímicas, la relación entre los distintos tipos lesionales de la paratuberculosis y la expresión *in situ* de IFN- γ .

Los resultados obtenidos muestran que el IFN- γ está relacionado con los distintos tipos de lesiones granulomatosas dadas las diferencias en inmunopositividad encontradas en los animales con lesión respecto a los controles no infectados. Los linfocitos son las principales células productoras de IFN- γ (Zúñiga *et al.*, 2012) pero también pueden sintetizarlo los macrófagos y células dendríticas en menor medida (Gessani *et al.*, 1998; Vremec *et al.*, 2007). En el presente estudio la morfología de las células inmunopositivas se correspondía mayoritariamente con linfocitos, lo que coincidiría con la acción de esta citocina, la cual es sintetizada mayoritariamente por linfocitos CD4+ y NK, para lograr la activación de los macrófagos (Cooper *et al.*, 2002; Arsenault *et al.*, 2014). En cambio, en lesiones tuberculosas de ciervos (García-Jiménez *et al.*, 2012) la inmunopositividad se observó también en células epitelioides y gigantes,

negativas en nuestro caso, lo que sugiere la posible existencia de diferencias debidas a la especie animal o a las micobacterias infectantes.

Las lesiones focales mostraron el mayor recuento de células inmunoteñidas frente a IFN- γ . En estas lesiones, relacionadas con fases latentes o iniciales de la infección, la mayor producción de esta citocina por parte de los linfocitos localizados en las placas de Peyer activaría a los macrófagos y limitaría el crecimiento de *Map*, polarizándolos hacia un fenotipo M1 que, en el tercer estudio, se ha demostrado como dominante en este tipo de lesión. En las lesiones difusas paucibacilares, que también continen pocas micobacterias, también se ha encontrado un elevado número de linfocitos que expresan IFN- γ , lo que indicaría que su acción es similar a la de las formas focales. En cambio, en las lesiones de tipo difuso multibacilar formadas por macrófagos M2, los niveles de células inmunomarcadas frente a IFN- γ fueron muy bajos, coincidiendo con una elevada cantidad de BAAR. Este hecho estaría también de acuerdo con lo ya descrito previamente en otros estudios que relacionan la polarización hacia formas M2 con niveles reducidos de IFN- γ (Mantovani *et al.*, 2004; Martínez y Gordon, 2014).

Según estos resultados, la producción local de IFN- γ parece estar en relación no solo con la polarización de los macrófagos, observada en los diferentes tipos de lesión paratuberculosa, sino también con su distribución en las lesiones granulomatosas, ya que la presencia de un infiltrado difuso desorganizado en el intestino, como el que se observa en las formas difusas multibacilares, se ha relacionado con bajos niveles locales de IFN- γ , según lo descrito en infecciones por *M. avium* u otras micobacterias, donde la presencia de esta citocina parece ser indispensable para el desarrollo de granulomas bien organizados (Ehlers y Richter, 2001).

Todos estos resultados sustentarían el modelo sobre patogenia propuesto en paratuberculosis según el cual habría una transición de

respuesta inmunitaria Th1 hacia una Th2 (Stabel, 2006). A nivel local, en las lesiones focales, iniciales o latentes, donde la producción de IFN- γ es elevada, los macrófagos tendrían un perfil M1 y la respuesta inmunitaria sería de tipo Th1. En las lesiones difusas paucibacilares, también predominaría este tipo de respuesta Th1, que no sería capaz de controlar la respuesta inflamatoria pero sí la multiplicación de *Map*. Sin embargo, en las lesiones difusas multibacilares, los macrófagos, polarizados hacia un perfil M2 asociados a bajos niveles de linfocitos que expresan IFN- γ , no habrían logrado controlar la multiplicación de *Map* y tampoco la respuesta inflamatoria. De todas formas, hay que tener en cuenta que esta evolución de una respuesta Th1 a Th2 no se produciría en todos los animales infectados, tal y como ya ha sido señalado (Begg *et al.*, 2011; Vázquez *et al.*, 2013) y se ha demostrado en los animales infectados con la cepa Tipo S en los primeros estudios que conforman esta Tesis Doctoral.

Como ya se ha indicado anteriormente, son escasos los estudios que han valorado la expresión de IFN- γ a nivel local, y sus resultados son variables (Tanaka *et al.*, 2005; Smeed *et al.*, 2007; Gillan *et al.*, 2010; Shu *et al.*, 2011). En la mayoría de ellos se ha estudiado la producción *in vitro* a partir de linfocitos estimulados procedentes de nódulos linfáticos (Burrells *et al.*, 1999) o se han valorado los niveles de transcripción génica (Begara-McGorum *et al.*, 1998; Lee *et al.*, 2001; Shu *et al.*, 2011). En algunos de ellos, los niveles de transcripción se relacionan positivamente con la intensidad de las lesiones (Shu *et al.*, 2011) y en otros no (Sweeney *et al.*, 1998). También existen discrepancias analizando los niveles de mRNA de IFN- γ en función del tipo de lesión (Tanaka *et al.*, 2005; Smeed *et al.*, 2007), a diferencia de nuestro estudio, donde se han podido identificar diferencias claras entre ellos.

En la mayoría de los estudios realizados hasta el momento no se han encontrado diferencias en los niveles de transcripción génica de IFN- γ entre

los animales infectados subclínicamente y los controles (Coussens *et al.*, 2004; Tanaka *et al.*, 2005; Smeed *et al.*, 2007; Gillan *et al.*, 2010; Shu *et al.*, 2011). Posiblemente esos animales referidos como subclínicos mostraran lesiones identificadas en nuestro estudio como focales, en las que sí se han hallado diferencias en la expresión de esta citocina respecto a los animales no infectados. En este sentido, es de destacar que la mayoría de células que expresaban IFN- γ se localizaban exclusivamente en las proximidades de los granulomas focales, sin que existieran diferencias en su número con los controles en otras áreas. Dado el carácter focal y reducido de este tipo de lesión, la probabilidad de tomar una muestra que la contenga para realizar el análisis de transcripción génica de IFN- γ es baja. Algo similar puede ocurrir en las lesiones paucibacilares donde la expresión de esta citocina puede variar en función del tramo intestinal estudiado.

Teniendo en cuenta estos factores, en el diseño de futuros estudios para valorar la respuesta inmunitaria local, debería contemplarse siempre la elección de muestras con tejido linfoide intestinal ya que aumentaría notablemente la probabilidad de tomar lesiones en las mismas, o emplear técnicas que permitan su análisis en relación con las lesiones (inmunohistoquímica, microdissección láser, etc.). De todas formas, estos resultados deben ser analizados con precaución, ya que la metodología empleada ha sido diferente (métodos inmunohistoquímicos frente a PCR cuantitativa) y cabe la posibilidad de que los niveles de transcripción no se correlacionen con la expresión de la proteína detectada con el anticuerpo empleado, posiblemente por modificaciones post-transcripcionales en la expresión de IFN-, que se ha señalado que pueden ocurrir (Maarifi *et al.*, 2015).

De acuerdo con nuestros resultados, existiría una correlación directa entre el número de células inmunomarcadas frente a IFN- γ y los niveles de

producción de esta citocina a nivel periférico tras la estimulación de la sangre con *Map*. Aunque en la respuesta inmunitaria frente a la paratuberculosis intervienen también otros linfocitos, los que están en el intestino expresando IFN- γ , próximos al granuloma, jugarían un papel relevante en la aparición de los distintos tipos de lesión, como demuestra el hecho de que los animales con lesión muestren una elevada cantidad de células inmunopositivas respecto de los animales control. La relación entre el número de células inmunomarcadas frente a IFN- γ , el tipo de lesión y la cantidad de BAAR, sugiere que esta citocina no previene la evolución hacia formas difusas pero si el crecimiento de *Map* en esas lesiones.

Los factores responsables de que la infección por *Map* resulte en formas de lesión y evoluciones diferentes aún no se conocen con exactitud (Koets *et al.*, 2015) pero se ha señalado que podrían estar relacionados con la interferencia en la coordinación de la respuesta inmunitaria del hospedador conforme avanza la infección (Stabel y Robbe-Austerman, 2011). Uno de ellos sería el tipo de cepa de *Map* que, según nuestros resultados, en los corderos infectados con cepas Tipo C induciría una respuesta celular intensa, que evitaría la evolución de las lesiones hacia formas difusas multibacilares. Otros factores como la edad de infección (Delgado *et al.*, 2012), factores de resistencia individual (Nalubamba *et al.*, 2008), carga bacteriana, efectos hormonales o el agotamiento de los mecanismos de acción de linfocitos T (Koets *et al.*, 2015) podrían también participar, posiblemente de forma conjunta.

Por último, hay que señalar que los dos primeros experimentos se realizaron en la especie ovina, debido a las ventajas que posee como modelo experimental de paratuberculosis respecto al bovino (menor coste, fácil manejo, ser un hospedador natural, etc.). En cambio, para la realización de los dos últimos estudios, se emplearon muestras de tejidos procedentes de

bovinos infectados de forma natural y experimental que nos permitieron disponer de todo el espectro lesional de la paratuberculosis para alcanzar los objetivos planteados, unido a una mayor disponibilidad de anticuerpos para caracterizar los macrófagos y la respuesta inmunitaria. En el caso del cuarto estudio, no se incluyeron lesiones multifocales para estudiar la presencia de células que expresen IFN- y debido al carácter poco definido, de transición, que parecen tener dichas lesiones, según los resultados del tercer estudio, por lo que se optó por caracterizar lesiones con un perfil definido.

Aunque los dos grupos de estudios (en ovinos y bovinos) se han realizado bajo la premisa de que, en líneas generales, la infección se comporta igual en las dos especies, no puede obviarse que podría haber diferencias entre ambas por ejemplo, con un diferente comportamiento de los macrófagos en los tipos de lesión. Sin embargo, este hecho no parece probable porque, aunque con pequeñas diferencias, los rasgos morfológicos básicos y los perfiles inmunitarios de los tipos lesionales de la paratuberculosis se mantienen entre las distintas especies de rumiantes (Pérez *et al.*, 1996, 1997, 1999; González *et al.*, 2005; Vázquez *et al.*, 2013).

6. CONCLUSIONES

CONCLUSIONS

En relación a la influencia que el agente etiológico de la paratuberculosis (*Map*) puede jugar sobre la patogenia de la enfermedad en un modelo experimental ovino:

- 1- Tanto las cepas de *Map* Tipo S (ovinas, Tipos I y III) como las de Tipo C (bovinas, Tipo II) pueden infectar a la especie ovina, colonizar el intestino y ocasionar la aparición de lesiones.
- 2- Existen diferencias en la evolución y morfología de las lesiones en función del tipo de cepa de *Map*: las asociadas a las cepas Tipo S presentan carácter persistente y latente, con granulomas formados por macrófagos y escasos linfocitos, mientras que las inducidas por las cepas Tipo C muestran un marcado carácter regresivo, con un grado variable de fibrosis y tienden a desaparecer con el tiempo.
- 3- También existen diferencias en la respuesta inmunitaria periférica en función del tipo de cepa de *Map*: en los corderos infectados con cepas Tipo C la respuesta inmunitaria celular es más precoz e intensa que en los inoculados con cepas Tipo S.
- 4- El empleo como inóculo, tanto de una cepa cultivada como de micobacterias purificadas a partir del homogeneizado intestinal del que aquella fue aislada, permite reproducir la infección por *Map* en un modelo experimental ovino, con diferencias en la presencia de lesiones y la respuesta inmunitaria específica, que son menos intensas tras la infección con la cepa cultivada.
- 5- A la hora de elegir el inóculo para reproducir la infección por *Map* de forma experimental con -al menos- cepas Tipo S, se debe considerar la pérdida de virulencia que puede experimentar la micobacteria tras su aislamiento y posterior cultivo *in vitro*.

Respecto al estudio de la relación entre la respuesta inmunitaria local del hospedador y los distintos tipos de lesión en la paratuberculosis bovina:

- 6- La población de macrófagos que forma parte de los diferentes tipos de lesión muestra distintos fenotipos, caracterizados por variaciones en la expresión de citocinas y otros mediadores de la respuesta inflamatoria.
- 7- Los macrófagos en las lesiones focales presentan un perfil tipo M1 de carácter proinflamatorio que impediría la multiplicación de *Map* mientras que en los granulomas de las formas difusas multibacilares son de tipo M2, de naturaleza antiinflamatoria incapaz de contener la multiplicación de *Map*. En las lesiones difusas paucibacilares, los macrófagos muestran un fenotipo M1 pero diferenciado de las formas focales por la menor expresión de TNF- α .
- 8- La presencia de células productoras de IFN- γ a nivel local está relacionada con los distintos tipos de lesión, de forma que su número es mayor en las lesiones focales y difusas paucibacilares que en las difusas multibacilares.
- 9- Existe una relación directa entre el número de células productoras de IFN- γ y la cantidad de *Map*, pero no así con la gravedad de la lesión inflamatoria.
- 10- En las lesiones asociadas a la infección por *Map*, las células productoras de IFN- γ están estrechamente asociadas a los granulomas lo que -junto al pequeño tamaño de las lesiones focales- debería considerarse a la hora de diseñar el muestreo de tejidos y su análisis en los estudios de respuesta inmunitaria a nivel local.

- 11- Existe una correlación positiva entre los niveles periféricos de IFN- γ , tras la estimulación de la sangre con PPD aviar, y el número de células que expresan IFN- γ en relación con las lesiones intestinales.
- 12- La tinción inmunohistoquímica de diversos marcadores fenotípicos celulares y la valoración semicuantitativa de su expresión permite evaluar y establecer diferencias en la respuesta inmunitaria local.

In relation to the analysis of the influence that the etiological agent of paratuberculosis (*Map*) could exert over the pathogenesis of the disease in an experimental ovine model:

- 1- Both Type S (ovine, Types I and III) and Type C (bovine, Type II) strains of *Map* can infect sheep, colonize the intestine and cause the development of lesions.
- 2- There are differences in the evolution and morphology of the lesions depending on the type of strain: lesions related to the Type S strains, with a persistent and latent nature, are formed by granulomas composed of macrophages and scant lymphocytes whereas lesions induced by Type C strains, which show a clear regressive behavior, have a variable degree of fibrosis and tend to disappear over time.
- 3- There are also differences in the peripheral immune response depending on the strain of *Map*: lambs infected with Type C strains develop an earlier and stronger cellular immune response than those inoculated with Type S strains.
- 4- The inoculation of either micobacteria purified from an intestinal homogenate or obtained as a cultured strain from that homogenate, are able to reproduce *Map* infection in an ovine experimental model, with differences in the presence of lesions and development of a specific immune response, that are less intense after infection with cultured *Map*.
- 5- When choosing the inoculum in order to reproduce *Map* infection experimentally, it should be borne in mind the virulence attenuation that mycobacteria can experience after its purification and subsequent laboratorial culture.

Regarding the study of the relation between the host local immune response and the different types of lesion in bovine paratuberculosis:

- 6- The macrophage population that form the different types of lesion shows distinct phenotypes characterized by variations in the expression of cytokines and other inflammatory response mediators.
- 7- Macrophages in the focal lesions showed a M1 phenotype, with pro-inflammatory character, which would hamper the multiplication of *Map* whereas those present in the granulomas of the diffuse multibacillary lesions are mainly M2, with anti-inflammatory character, unable to control the multiplication of *Map*. Macrophages from the diffuse paucibacillary lesions showed a M1 profile differentiated from focal lesions by the lower expression of TNF- α .
- 8- The presence of local IFN- γ -producing cells would be related to the different types of lesion, as they are more numerous in focal and diffuse paucibacillary than in diffuse multibacillary lesions.
- 9- There is a positive correlation between the number of IFN- γ -producing cells and the amount of *Map*, but not with the severity of the lesion.
- 10- In *Map*-associated lesions, IFN- γ -producing cells are closely associated with the granulomas. This fact, together with the small size of the focal lesions, should be taken into account for designing the sampling and analysis procedures when studying the local immune response.
- 11- There is a positive correlation between IFN- γ released after whole blood stimulation with avian PPD, and the number of IFN- γ -expressing cells in relation to the intestinal lesions.

12- Immunohistochemical labeling of different phenotypic cellular markers and the semi-quantitative analysis of their expression allows the assessment of differences in the local immune response.

7. RESUMEN

SUMMARY

La paratuberculosis es una enfermedad intestinal crónica de los rumiantes domésticos y silvestres causada por la bacteria *Mycobacterium avium* subespecie *paratuberculosis* (*Map*). Actualmente su distribución es mundial y se le atribuyen numerosas pérdidas económicas en la producción ganadera. La ausencia de medidas eficaces de control reside, entre otras razones, en el desconocimiento de muchos aspectos de la patogenia de la enfermedad. Se asume que los animales se infectan a edades tempranas donde son más susceptibles y, a partir de ese momento, los animales infectados pueden evolucionar de diferente forma: resistir a la infección, infectarse y permanecer asintomáticos durante largos tiempo o desarrollar la enfermedad. Además, se ha descrito que pueden presentar distintos tipos de lesión, relacionados con las distintas fases de la enfermedad, sin que hasta el momento se conozca qué factores determinan esas diferentes respuestas. El objetivo general de esta Tesis Doctoral es contribuir a mejorar el conocimiento de la patogenia de la paratuberculosis, en concreto a evaluar la relación que diferentes factores, tanto del agente etiológico como del hospedador, pueden tener con los tipos de lesión, y por lo tanto, con las fases de la enfermedad.

El primer objetivo concreto se centra en valorar la influencia que las diferentes cepas de *Map* pueden jugar sobre el desarrollo de lesiones y la respuesta inmunitaria en un modelo experimental ovino. Para ello, se ha llevado a cabo una infección experimental en 30 corderos de 1 mes y medio de edad, de raza Assaf que fueron divididos en 4 grupos de 6 animales infectados con dos cepas de Tipo S -ovinas- (22G y Ovicap49- pigmentada), una cepa de Tipo C -bovina- (764) y la cepa estándar de referencia K-10 de *Map*, también de Tipo C, respectivamente inoculando a cada uno un total de 2×10^9 micobacterias/40 mL de PBS. Excepto la cepa K-10, el resto procedían de aislados de casos naturales locales de paratuberculosis y el inóculo se obtuvo tras tres pases en cultivo laboratorial. Los restantes 6 corderos

permanecieron como animales control no infectados. Los animales fueron sacrificados a los 150 y 390 días post-infección (dpi). Durante el experimento se valoró la respuesta inmunitaria periférica mediante ELISA indirecto para la determinación de anticuerpos serológicos, la prueba de liberación del IFN- γ y la intradermorreacción. Se observó que la producción de anticuerpos y de IFN- γ fue significativamente mayor en los animales infectados con las cepas Tipo C. Tras el sacrificio, no se observaron lesiones macroscópicas y se llevó a cabo el recuento del número de granulomas presentes en las distintas localizaciones intestinales. El número de granulomas fue siempre mayor en los corderos infectados con las cepas Tipo C. En los animales infectados con las cepas Tipo S, las lesiones fueron de carácter focal, restringidas al tejido linfoide intestinal, y no se observaron diferencias en su intensidad a lo largo del experimento. Sin embargo, en los dos grupos infectados con las cepas Tipo C, las lesiones eran más graves, con necrosis caseosa, células gigantes y diferentes grados de fibrosis. Además, su número se redujo significativamente a lo largo del estudio. En conclusión, ambos tipos de cepas son capaces de infectar a la especie ovina, pero con diferencias en la morfología de las lesiones y en su evolución, de forma que las producidas por las cepas Tipo C tienen un carácter regresivo y van disminuyendo en gravedad, en asociación con una mayor respuesta inmune periférica de tipo celular.

El segundo objetivo fue valorar la influencia que el cultivo en laboratorio ejerce sobre un aislado de campo ovino de *Map* en cuanto a su patogenicidad en una infección experimental en corderos, valorando el desarrollo de las lesiones y la respuesta inmunitaria. A un grupo de 7 corderos se les administraron por vía oral 40 mL de un inóculo compuesto por 4×10^6 UFC/mL de micobacterias obtenido tras su purificación a partir del homogeneizado de tejido intestinal de una oveja afectada de paratuberculosis y que posteriormente se comprobó que se correspondía con

una cepa Tipo S. Además, un año más tarde, a otro grupo de 7 corderos se les administraron 40 mL de un inóculo compuesto de 5×10^7 UFC/mL obtenido tras 3 pases por cultivo laboratorial de la cepa de *Map* aislada del inóculo anterior. Otro grupo de 7 corderos se mantuvo como control no infectado. En estos animales, se valoraron también las respuestas inmunitarias celular y humoral periféricas, empleando los procedimientos ya señalados, así como el recuento de las lesiones granulomatosas encontradas a los animales sacrificados a los 120 y 240 dpi. Tanto la respuesta inmunitaria periférica (celular y humoral) como el número de granulomas fueron significativamente inferiores en los animales inoculados con la cepa cultivada. Si bien no se encontraron diferencias en la morfología de las lesiones, en el grupo de corderos infectados con la cepa cultivada estaban restringidas al tejido linfoide intestinal, mientras que los animales infectados con la micobacteria procedente del homogeneizado se encontraron en un mayor número de localizaciones, incluyendo zonas de intestino sin tejido linfoide. Mediante una técnica de PCR anidada se identificó ADN de *Map* en corderos de los dos grupos, pero en menor proporción en los del grupo infectado con el inóculo cultivado. Estos resultados sugieren que el cultivo en medios laboratoriales habría inducido una atenuación de la virulencia de la cepa Tipo S empleada, que se ha manifestado en un menor número de lesiones y una menor intensidad de la respuesta inmunitaria.

La segunda parte de esta Tesis Doctoral se centra en conocer la asociación de algunos factores inherentes al hospedador, como la respuesta inmunitaria local, con los distintos tipos de lesión, evaluando la expresión de diferentes mediadores de la respuesta inflamatoria en los principales tipos celulares que participan en la formación de los granulomas, mediante técnicas inmunohistoquímicas. Debido a la disponibilidad de un mayor número de anticuerpos, los dos siguientes estudios se han llevado a cabo sobre tejidos de origen bovino. El tercer objetivo tiene como misión

caracterizar las poblaciones de macrófagos que participan en los distintos tipos de lesión asociados a la infección por *Map*. Se estudiaron secciones de yeyuno procedentes de 23 bovinos infectados natural o experimental con *Map* y que mostraban lesiones granulomatosas de carácter focal, restringidas al tejido linfoide, o difusas con abundantes (multibacilares) o escasas (paucibacilares) micobacterias. En ellas, se llevaron a cabo técnicas inmunohistoquímicas con anticuerpos frente a iNOS, TNF- α , CD163, IL-10, TGF- β , MHC II, NRAMP1, calprotectina, Ki-67, CD68, lisozima e Iba-1.

El número de células inmunomarcadas y la intensidad de la inmunotinción se valoraron de forma semicuantitativa empleando el índice H. Se observaron diferencias significativas entre los principales tipos de lesión. En las focales, con pocos o ningún bacilo ácido alcohol resistente (BAAR), los macrófagos con elevada expresión de iNOS y TNF- α , estarían polarizados hacia un fenotipo M1 mientras que en las formas difusas multibacilares mostrarían un fenotipo M2, con expresión elevada de CD163, IL-10, TGF- β , MHC II y NRAMP1. Por su parte, los macrófagos presentes en las lesiones difusas paucibacilares, también estarían polarizados hacia un fenotipo M1 pero su expresión de TNF- α era mucho menor. Los macrófagos de las lesiones difusas expresaron niveles elevados de calprotectina y bajos de Ki-67, indicando el carácter progresivo de este tipo de lesión, al que llegan macrófagos reclutados recientemente desde la sangre, mientras en las focales, con niveles bajos de calprotectina y elevados de Ki-67, los macrófagos se dividen mayoritariamente *in situ*, apoyando su carácter latente. La expresión de lisozima y CD68 se asoció a la alta presencia de *Map* en los macrófagos. Según estos resultados, la población de macrófagos que forma las distintas formas de lesión en paratuberculosis es heterogénea con diferentes fenotipos en función del tipo.

El cuarto objetivo ha sido valorar la expresión local de IFN- γ , principal molécula efectora de la respuesta inmunitaria celular y de la activación clásica M1 de los macrófagos, en relación con los distintos tipos de lesión mediante métodos inmunohistoquímicos. Se evaluó la expresión local de IFN- γ en muestras de yeyuno de 20 casos de paratuberculosis bovina en relación al tipo de lesión (focales y difusas). Las células positivas, de morfología compatible con linfocitos, predominaron en las lesiones focales y difusas paucibacilares siempre en la proximidad de los macrófagos que formaban los granulomas y cuya presencia podría estar relacionada con la polarización de los macrófagos hacia un fenotipo M1 encontrada en estos tipos de lesión en el estudio anterior. En cambio, el número de células inmunopositivas para IFN- γ fue escaso pero mayor que en los controles, en las lesiones difusas multibacilares, apareciendo células positivas entremezcladas con los macrófagos. La producción de IFN- γ en sangre periférica fue mayor en los animales infectados respecto de los controles y se observó una correlación con el número de células inmunomarcadas en las lesiones intestinales.

En conclusión, existe una relación entre la presencia de células inmunoteñidas frente a IFN- γ en el intestino con los distintos tipos de lesión asociados a la paratuberculosis bovina, de forma que la existencia de un mayor número de células productoras de esta citocina se relaciona con una menor presencia de BAAR, pero no con la intensidad de la lesión granulomatosa intestinal.

Johne's disease, or paratuberculosis, is a chronic bowel disease of livestock and wildlife ruminants caused by the bacteria *Mycobacterium avium* subspecies *paratuberculosis* (*Map*). It has a worldwide distribution and a huge economic impact on livestock production. The absence of effective control procedures is due, among other reasons, to the lack of complete knowledge of the pathogenesis of the disease. It is assumed that animals become infected early in life, when they are more susceptible, and from that moment, the evolution of infected animals could follow different paths: overcome the infection, get infected and remain asymptomatic for long periods of time or develop the disease. Besides, various types of lesions have been described in relation to the different stages of the disease, although the reasons behind those variations are still unknown. The main objective of this PhD Thesis is to contribute to the improvement of the knowledge of the pathogenesis of paratuberculosis, by studying the relationship that different factors, either from the etiologic agent or from the host could have with the different types of lesion and therefore, with the stages of the disease.

The first specific objective is focused on the analysis of the influence that different strains of *Map* could exert over the development of lesions and the immune response in an experimental ovine model. With this purpose, 30 Assaf lambs 35 days old were allocated in 4 groups, 6 lambs each, and respectively orally inoculated with 2×10^9 mycobacteria diluted in 40 mL of PBS of two S type, ovine, strains, (22G and Ovicap49, a pigmented strain), one C type, bovine, strain (764) and K-10, a reference *Map* strain, also C type. Apart from K-10 strain, the other strains were obtained from local natural cases of the disease and the inocula were obtained after three passages in bacterial culture. The remaining 6 lambs were kept as non-infected control group. Animals were culled at 150 and 390 days post-infection (dpi). Peripheral immune response was studied during the experiment through an indirect ELISA for serological antibodies determination, IFN- γ release test and

intra-dermal reaction. Serological antibody production and IFN- γ release was significantly increased in those lambs infected with C Type strains. Post-mortem studies showed no differences regarding the macroscopic lesions, but the number of granulomata, microscopically counted at different locations of the intestine, was always higher in lambs infected with C type strains. Lambs infected with S type strains showed focal lesions, located in the GALT (gut associated lymphoid tissue), whose severity remained similar along the experiment. On the other hand, lambs from the two groups infected with C type strains showed more severe lesions, with caseous necrosis, giant cells and different degree of fibrosis. Furthermore, their number decreased significantly during the study. In conclusion, both types of strains can infect sheep but showed differences regarding the morphology of the lesions and their evolution, as those lesions caused by C type strains show characteristics of regression and evolve toward milder lesions, in association with a more intense peripheral cellular immune response.

The second objective of this thesis was to evaluate how the laboratorial culture could influence the virulence of *Map* ovine strain isolated from a natural case of paratuberculosis with regard to the development of lesions and immune response. For this, a group formed by 7 lambs was orally challenged with 40 mL of a 4×10^6 UFC/mL suspension of mycobacteria purified from an intestinal homogenate obtained from a sheep naturally infected with an S type *Map* strain. One year later, another group of 7 lambs were inoculated with 40 mL 5×10^7 UFC/mL suspension of mycobacteria obtained after three passages in culture of the *Map* strain isolated from that natural case of paratuberculosis. Another group of 7 lambs remained as non infected control group. Peripheral cellular and humoral immune responses were studied in these animals using aforementioned methods as well as granulomata count in lambs culled at 120 and 240 dpi. Both, the immune response (cellular and humoral) as the number of granulomata were

significantly lower in those animals inoculated with the laboratory cultured strain. Although no differences were found regarding the morphology of the lesions, those lambs inoculated with the cultured bacteria showed lesions only located at GALT, while in those animals infected with the mycobacteria from the intestinal homogenate were found at more locations, including areas of intestine without lymphoid tissue. Although DNA from *Map* was found, through a nested PCR technique, in lambs from the two infected groups, the number of positive animals was lower in the group infected with cultured bacteria. These results suggest that bacterial culture would have induced the attenuation of the S type strain used in this experiment, denoted by fewer lesions and less intense immune response.

The second part of this PhD thesis is focused on the study of the association of some factors inherent to the host, as local immune response, with the different types of lesion. This is attempted through the immunohistochemical labelling of different inflammatory response mediators found in those cells that participate in the formation of granulomata. Due to the availability of a wider range of antibodies, the following two studies have been carried out on bovine tissues. The third objective of this thesis is aimed to characterize the populations of macrophages that participate in the different types of lesions associated with *Map* infection. With this purpose, sections from the jejunum of 23 cattle, naturally or experimentally infected with *Map*, showing granulomatous lesions, either focal, located at GALT, or diffuse, with abundant (multibacillary) or low (paucibacillary) acid and alcohol fast bacilli (AFB), were studied. iNOS, TNF- α , CD163, IL-10, TGF- β , MHC II, NRAMP1, calprotectin, Ki-67, CD68, lysozyme and Iba-1 were immunohistochemically labelled in these sections. The number of labelled cells and the intensity of labelling were evaluated with a semi-quantitative score, using H-index. Significant differences were found between the main types of lesion. In focal lesions, with few or no AFB, macrophages showed

increased expression of iNOS and TNF- α , what would denote a polarization towards M1 phenotype, while a M2 phenotype would predominate in diffuse multibacillary lesions, where macrophages showed increased expression of CD163, IL-10, TGF- β , MHC II and NRAMP1. Macrophages found in diffuse paucibacillary lesions would also show a M1 phenotype, although the expression of TNF- α was lower than in focal lesions. Macrophages from diffuse lesions had increased expression of calprotectin and decreased expression of Ki-67, suggesting a progressive nature of these lesions, to which new macrophages would be recruited from blood, while in focal lesions, with low calprotectin and high Ki-67, macrophages would divide *in situ*, supporting the concept of their latent nature. According to these findings, macrophages found in the different types of lesion in paratuberculosis are heterogeneous populations with different phenotypes depending on the type of lesion.

The fourth objective of this thesis was to analyse the local expression of IFN- γ , main effector molecule in the cellular immune response and in the classical activation -M1- of macrophages, in relation to the different types of lesion through immunohistochemical labelling. The relation between local expression of IFN- γ and the type of lesion was evaluated in 20 samples of jejunum cases of paratuberculosis showing diffuse and focal lesions. Positively labelled cells, morphologically suggestive of lymphocytes, were abundant in focal and paucibacillary diffuse lesions and always in close association with the macrophages of the granulomata. Their presence could be related to the polarization of macrophages toward a M1 phenotype, already found in these types of lesion in the above mentioned study. By contrast, the number of IFN- γ -labelled cells was fewer, although higher than in controls, in the multibacillary diffuse lesions, where positive cells were intermingled with macrophages. IFN- γ release test on whole blood showed higher levels of the cytokine in infected animals when compared to control ones and there was a positive correlation with the number of labelled cells in

the intestine. In conclusion, there is a relationship between the presence of IFN- γ -producer cells in the intestine and the different types of lesion associated with bovine paratuberculosis. A higher number of IFN- γ -immunolabelled cells is related to low amounts of AFB but not to the intensity of the intestinal granulomatous lesions.

8. BIBLIOGRAFÍA

REFERENCES

- Abbas B, Riemann HP (1988). IgG, IgM and IgA in the serum of cattle naturally infected with *Mycobacterium paratuberculosis*. *Comp Immunol Microbiol Infect Dis*. 11:171–5.
- Abendaño N, Sevilla IA, Prieto JM, Garrido JM, Juste RA, Alonso-Hearn M. (2013). *Mycobacterium avium* subspecies *paratuberculosis* isolates from sheep and goats show reduced persistence in bovine macrophages than cattle, bison, deer and wild boar strains regardless of genotype. *Vet Microbiol*. 163:325–34.
- Achkar JM, Casadevall A. (2013). Antibody-mediated immunity against tuberculosis: implications for vaccine development. *Cell Host Microbe*. 13:250–62.
- Ackermann MR, DeBey BM, Stabel TJ, Gold JH, Register KB, Meehan JT (1994). Distribution of anti-CD68 (EBM11) immunoreactivity in formalin-fixed, paraffin-embedded bovine tissues. *Vet Pathol*. 31:340–8.
- Adúriz JJ, Juste RA, Cortabarria N (1995). Lack of mycobactin dependence of mycobacteria isolated on Middlebrook 7H11 from clinical cases of ovine paratuberculosis. *Vet Microbiol*. 45:211–7.
- Adúriz JJ, Juste RA, Sáez de Ocariz C (1994). An epidemiologic study of sheep paratuberculosis in the Basque Country of Spain: serology and productive data. En: Chiodini RJ, Collins MT, Bassey EOE. (Eds.). *Proc 4th Int. Coll. PTBC. IAP.Providence. EEUU*. 19–26.
- Allen AJ, Park K-T, Barrington GM, Lahmers KK, Abdellrazeq GS, Rihan HM, Sreevatsan S, Davies C, Hamilton MJ, Davis WC (2011). Experimental infection of a bovine model with human isolates of *Mycobacterium avium* subsp. *paratuberculosis*. *Vet Immunol Immunopathol*. 141:258–66.
- Allen AJ, Park KT, Barrington GM, Lahmers KK, Hamilton MJ, Davis WC (2009). Development of a bovine ileal cannulation model to study the immune response and mechanisms of pathogenesis of paratuberculosis. *Clin Vaccine Immunol*. 16:453–63.
- Alonso-Hearn M, Molina E, Geijo M, Vazquez P, Sevilla IA, Garrido JM, Juste RA (2012). Immunization of adult dairy cattle with a new heat-killed vaccine is associated with longer productive life prior to cows being sent to slaughter with suspected paratuberculosis. *J Dairy Sci*. 95:618–29.
- Aly SS, Mangold BL, Whitlock RH, Sweeney RW, Anderson RJ, Jiang J, Schukken YH, Hovingh E, Wolfgang D, Van Kessel JAS, Karns JS, Lombard JE, Smith JM, Gardner IA (2010). Correlation between Herrold egg yolk medium culture and real-time quantitative polymerase chain reaction results for *Mycobacterium avium* subspecies *paratuberculosis* in pooled fecal and environmental samples. *J Vet Diagn Invest*. 22:677–83.
- Alzuherri HM, Little D, Clarke CJ (1997). Altered intestinal macrophage phenotype in ovine *paratuberculosis*. *Res Vet Sci*. 63:139–43.
- Alzuherri HM, Woodall CJ, Clarke CJ (1996). Increased intestinal TNF-alpha, IL-1 beta and IL-6 expression in ovine *paratuberculosis*. *Vet Immunol Immunopathol*. 49:331–45.
- Arrazuria R, Juste RA, Elguezabal N (2016a). Mycobacterial Infections in Rabbits: From the Wild to the Laboratory. *Transbound Emerg Dis*. tbed.12474.
- Arrazuria R, Molina E, Garrido JM, Pérez V, Juste RA, Elguezabal N (2016b). Vaccination sequence effects on immunological response and tissue bacterial burden in paratuberculosis infection in a rabbit model. *Vet Res*. 47:77.
- Arrazuria R, Molina E, Mateo-Abad M, Arostegui I, Garrido JM, Juste RA, Elguezabal N (2015). Effect of various dietary regimens on oral challenge with *Mycobacterium avium* subsp. *paratuberculosis* in a rabbit model. *Res Vet Sci*. 101:80–3.
- Arsenault RJ, Li Y, Bell K, Doig K, Potter A, Griebel PJ, Kusalik A, Napper S (2012). *Mycobacterium avium* subsp. *paratuberculosis* inhibits gamma interferon-induced signaling in bovine monocytes: insights into the cellular mechanisms of Johne's disease. *Infect Immun*. 80:3039–48.

- Arsenault RJ, Maattanen P, Daigle J, Potter A, Griebel P, Napper S (2014). From mouth to macrophage: mechanisms of innate immune subversion by *Mycobacterium avium* subsp. *paratuberculosis*. *Vet Res* 45:54.
- Bafica A, Scanga CA, Feng CG, Leifer C, Cheever A, Sher A (2005). TLR9 regulates Th1 responses and cooperates with TLR2 in mediating optimal resistance to *Mycobacterium tuberculosis*. *J Exp Med*. 202:1715–24.
- Baldwin CL, Sathiyaseelan T, Rocchi M, McKeever D (2000). Rapid changes occur in the percentage of circulating bovine WC1(+) gamma delta Th1 cells. *Res Vet Sci*. 69:175–80.
- Balseiro A (2004). Paratuberculosis bovina: valoración de las reacciones cruzadas con la prueba de la tuberculina, evaluación de técnicas diagnósticas y prevalencia en Asturias. Tesis Doctoral. Universidad de León.
- Balu S, Reljic R, Lewis MJ, Pleass RJ, McIntosh R, van Kooten C, van Egmond M, Challacombe S, Woof JM, Ivanyi J (2011). A novel human IgA monoclonal antibody protects against tuberculosis. *J Immunol*. 186:3113–9.
- Bannantine JP, Bayles DO, Waters WR, Palmer M V, Stabel JR, Paustian ML (2008). Early antibody response against *Mycobacterium avium* subspecies *paratuberculosis* antigens in subclinical cattle. *Proteome Sci*. 6:5.
- Bannantine JP, Bermudez LE (2013). No holes barred: invasion of the intestinal mucosa by *Mycobacterium avium* subsp. *paratuberculosis*. *Infect Immun*. 81:3960-5.
- Bannantine JP, Huntley JFJ, Miltner E, Stabel JR, Bermudez LE (2003). The *Mycobacterium avium* subsp. *paratuberculosis* 35 kDa protein plays a role in invasion of bovine epithelial cells. *Microbiology*. 149:2061–9.
- Bannantine JP, Talaat AM (2010). Genomic and transcriptomic studies in *Mycobacterium avium* subspecies *paratuberculosis*. *Vet Immunol Immunopathol*. 138:303–11.
- Baquero MM, Plattner BL (2016). Bovine WC1(+) $\gamma\delta$ T lymphocytes modify monocyte-derived macrophage responses during early *Mycobacterium avium* subspecies *paratuberculosis* infection. *Vet Immunol Immunopathol*. 170:65–72.
- Barkema HW, Green MJ, Bradley AJ, Zadoks RN (2009). Invited review: The role of contagious disease in udder health. *J Dairy Sci*. 92:4717–29.
- Barros MHM, Hauck F, Dreyer JH, Kempkes B, Niedobitek G (2013). Macrophage polarisation: an immunohistochemical approach for identifying M1 and M2 macrophages. *PLoS One*. 8:e80908.
- Bauman CA, Jones-Bitton A, Jansen J, Kelton D, Menzies P (2016a). Evaluation of fecal culture and fecal RT-PCR to detect *Mycobacterium avium* ssp. *paratuberculosis* fecal shedding in dairy goats and dairy sheep using latent class Bayesian modeling. *BMC Vet Res*. 12:212.
- Bauman CA, Jones-Bitton A, Menzies P, Toft N, Jansen J, Kelton D (2016b). Prevalence of paratuberculosis in the dairy goat and dairy sheep industries in Ontario, Canada. *Can Vet J*. 57:169–75.
- Beard PM, Rhind SM, Buxton D, Daniels MJ, Henderson D, Pirie A, Rudge K, Greig A, Hutchings MR, Stevenson K, Sharp JM (2001a). Natural paratuberculosis infection in rabbits in Scotland. *J Comp Pathol*. 124:290–9.
- Beard PM, Rhind SM, Sinclair MC, Wildblood LA, Stevenson K, McKendrick IJ, Sharp JM, Jones DG (2000). Modulation of $\gamma\delta$ T cells and CD1 in *Mycobacterium avium* subsp. *paratuberculosis* infection. *Vet Immunol Immunopathol*. 77:311–9.

- Beard PM, Stevenson K, Pirie A, Rudge K, Buxton D, Rhind SM, Sinclair MC, Wildblood LA, Jones DG, Sharp JM (2001b). Experimental paratuberculosis in calves following inoculation with a rabbit isolate of *Mycobacterium avium* subsp. *paratuberculosis*. *J Clin Microbiol.* 39:3080–4.
- Begara-McGorum I, Wildblood LA, Clarke CJ, Connor KM, Stevenson K, McInnes CJ, Sharp JM, Jones DG (1998). Early immunopathological events in experimental ovine paratuberculosis. *Vet Immunol Immunopathol.* 63:265–87.
- Begg DJ, de Silva K, Bosward K, Di Fiore L, Taylor DL, Jungersen G, Whittington RJ (2009). Enzyme-linked immunospot: an alternative method for the detection of interferon gamma in Johne's disease. *J Vet Diagn Invest.* 21:187–96.
- Begg DJ, de Silva K, Carter N, Plain KM, Purdie A, Whittington RJ (2011). Does a Th1 over Th2 dominance really exist in the early stages of *Mycobacterium avium* subspecies *paratuberculosis* infections? *Immunobiology.* 216:840–6.
- Begg DJ, de Silva K, Di Fiore L, Taylor DL, Bower K, Zhong L, Kawaji S, Emery D, Whittington RJ (2010). Experimental infection model for Johne's disease using a lyophilised, pure culture, seedstock of *Mycobacterium avium* subspecies *paratuberculosis*. *Vet Microbiol.* 141:301–11.
- Begg DJ, de Silva K, Plain KM, Purdie AC, Dhand N, Whittington RJ (2015). Specific faecal antibody responses in sheep infected with *Mycobacterium avium* subspecies *paratuberculosis*. *Vet Immunol Immunopathol.* 166:125–31.
- Begg DJ, Griffin JFT (2005). Vaccination of sheep against *M. paratuberculosis*: immune parameters and protective efficacy. *Vaccine.* 23:4999–5008.
- Begg DJ, O'Brien R, Mackintosh CG, Griffin JFT (2005). Experimental infection model for Johne's disease in sheep. *Infect Immun.* 73:5603–11.
- Begg DJ, Whittington RJ (2008). Experimental animal infection models for Johne's disease, an infectious enteropathy caused by *Mycobacterium avium* subsp. *paratuberculosis*. *Vet J.* 176:129–45.
- Bellamy R (1999). The natural resistance-associated macrophage protein and susceptibility to intracellular pathogens. *Microbes Infect.* 1:23–7.
- Benazzi S, el Hamidi M, Schliesser T (1996). Paratuberculosis in sheep flocks in Morocco: a serological, microscopical and cultural survey. *Zentralbl Veterinarmed B.* 43:213–9.
- Benedictus G, Kalis CJH (2003). Paratuberculosis: eradication, control and diagnostic methods. *Acta Vet Scand.* 44:231–41.
- Bennett R, McClement I, McFarlane I (2010). An economic decision support tool for simulating paratuberculosis control strategies in a UK suckler beef herd. *Prev Vet Med.* 93:286–93.
- Benoit M, Desnues B, Mege J-L (2008). Macrophage polarization in bacterial infections. *J Immunol.* 181:3733–9.
- Beran V, Havelkova M, Kaustova J, Dvorska L, Pavlik I (2006). Cell wall deficient forms of mycobacteria: a review. *Vet. Med.* 51:365-389.
- Bergey DH; Harrison FC, Breed RS, Hammer BW, Huntoon FM (1923). *Bergey's manual of determinative bacteriology.* 1ª ed. Baltimore, EE.UU.
- Bermudez LE, Petrofsky M, Sommer S, Barletta RG (2010). Peyer's patch-deficient mice demonstrate that *Mycobacterium avium* subsp. *paratuberculosis* translocates across the mucosal barrier via both M cells and enterocytes but has inefficient dissemination. *Infect Immun.* 78:3570–7.
- Bezos J, Álvarez J, Mínguez O, Marqués S, Martín O, Vigo V, Pieltain C, Romero B, Rodríguez S, Casal C, Mateos A, Domínguez L, de Juan L (2012). Evaluation of specificity of tuberculosis diagnostic assays in caprine flocks under different epidemiological situations. *Res Vet Sci.* 93:636–40.

- Bhide MR, Mucha R, Mikula I, Kisova L, Skrabana R, Novak M, Mikula I (2009). Novel mutations in TLR genes cause hyporesponsiveness to *Mycobacterium avium* subsp. *paratuberculosis* infection. BMC Genet. 10:21.
- Biet F, Sevilla IA, Cochard T, Lefrançois LH, Garrido JM, Heron I, Juste RA, McLuckie J, Thibault VC, Supply P, Collins DM, Behr MA, Stevenson K (2012). Inter- and intra-subtype genotypic differences that differentiate *Mycobacterium avium* subspecies *paratuberculosis* strains. BMC Microbiol. 12:264.
- Billman-Jacobe H, Carrigan M, Cockram F, Corner LA, Gill IJ, Hill JF, Jessep T, Milner AR, Wood PR (1992). A comparison of the interferon gamma assay with the absorbed ELISA for the diagnosis of Johne's disease in cattle. Aust Vet J. 69:25–8.
- Biswas SK, Mantovani A (2010). Macrophage plasticity and interaction with lymphocyte subsets: cancer as a paradigm. Nat Immunol. 11:889–96.
- Blackwell JM, Goswami T, Evans CA, Sibthorpe D, Papo N, White JK, Searle S, Miller EN, Peacock CS, Mohammed H, Ibrahim M (2001). SLC11A1 (formerly NRAM1) and disease resistance. Cell Microbiol. 3:773–84.
- Blackwell JM, Searle S, Mohamed H, White JK (2003). Divalent cation transport and susceptibility to infectious and autoimmune disease: continuation of the Ity/Lsh/Bcg/Nram1/Slc11a1 gene story. Immunol Lett. 85:197–203.
- Borrmann E, Möbius P, Diller R, Köhler H (2011). Divergent cytokine responses of macrophages to *Mycobacterium avium* subsp. *paratuberculosis* strains of Types II and III in a standardized in vitro model. Vet Microbiol. 152:101–11.
- Bosshard C, Stephan R, Tasara T (2006). Application of an F57 sequence-based real-time PCR assay for *Mycobacterium paratuberculosis* detection in bulk tank raw milk and slaughtered healthy dairy cows. J Food Prot. 69:1662–7.
- Brady C, O'Grady D, O'Meara F, Egan J, Bassett H (2008). Relationships between clinical signs, pathological changes and tissue distribution of *Mycobacterium avium* subspecies *paratuberculosis* in 21 cows from herds affected by Johne's disease. Vet Rec. 162:147–52.
- Brotherston JG, Gilmour NJL, Samuel JM (1961). Quantitative studies of *Mycobacterium johnei* in the tissues of sheep. I. Routes of infection and assay of viable *M. johnei*. J. Comp. Pathol. 71: 286-299.
- Brown CC, Baker DC, Barker IK (2007). The Alimentary System. Paratuberculosis (Johne's disease). En: Jubb KVF, Kennedy PC, Palmer N. (Eds.). Pathology of Domestic Animals. 5th ed. Elsevier Saunders. Londres. Reino Unido. 2: 222-225.
- Bryant B, Blyde D, Eamens G, Whittington R (2012). *Mycobacterium avium* subspecies *paratuberculosis* cultured from the feces of a Southern black rhinoceros (*Diceros bicornis minor*) with diarrhea and weight loss. J Zoo Wildl Med. 43:391–3.
- Buendía AJ, Navarro JA, Salinas J, McNair J, de Juan L, Ortega N, Cámara P, Torreblanca P, Sanchez J (2013). Ante-mortem diagnosis of caprine tuberculosis in persistently infected herds: influence of lesion type on the sensitivity of diagnostic tests. Res Vet Sci. 95:1107–13.
- Buergelt CD, Hall C, McEntee K, Duncan JR (1978). Pathological evaluation of paratuberculosis in naturally infected cattle. Vet Pathol. 15:196–207.
- Bull TJ, McMinn EJ, Sidi-Boumedine K, Skull A, Durkin D, Neild P, Rhodes G, Pickup R, Hermon-Taylor J (2003). Detection and verification of *Mycobacterium avium* subsp. *paratuberculosis* in fresh ileocolonic mucosal biopsy specimens from individuals with and without Crohn's disease. J Clin Microbiol. 41:2915–23.

- Bull TJ, Schock A, Sharp JM, Greene M, McKendrick IJ, Sales J, Linedale R, Stevenson K (2013). Genomic variations associated with attenuation in *Mycobacterium avium* subsp. *paratuberculosis* vaccine strains. *BMC Microbiol.* 13:11.
- Burrells C, Clarke CJ, Colston A, Kay JM, Porter J, Little D, Sharp JM (1999). Interferon-gamma and interleukin-2 release by lymphocytes derived from the blood, mesenteric lymph nodes and intestines of normal sheep and those affected with paratuberculosis (Johne's disease). *Vet Immunol Immunopathol.* 68:139–48.
- Burrells C, Clarke CJ, Colston A, Kay JM, Porter J, Little D, Sharp JM (1998). A study of immunological responses of sheep clinically-affected with paratuberculosis (Johne's disease). The relationship of blood, mesenteric lymph node and intestinal lymphocyte responses to gross and microscopic pathology. *Vet Immunol Immunopathol.* 66:343–58.
- Carrigan MJ, Seaman JT (1990). The pathology of Johne's disease in sheep. *Aust Vet J.* 67:47–50.
- Castellanos E, Aranaz A, de Juan L, Alvarez J, Rodríguez S, Romero B, Bezos J, Stevenson K, Mateos A, Domínguez L (2009). Single nucleotide polymorphisms in the IS900 sequence of *Mycobacterium avium* subsp. *paratuberculosis* are strain type specific. *J Clin Microbiol.* 47:2260–4.
- Chacón-Salinas R, Serafín-López J, Ramos-Payán R, Méndez-Aragón P, Hernández-Pando R, Van Soolingen D, Flores-Romo L, Estrada-Parra S, Estrada-García I (2005). Differential pattern of cytokine expression by macrophages infected in vitro with different *Mycobacterium tuberculosis* genotypes. *Clin Exp Immunol.* 140:443–9.
- Charafe-Jauffret E, Tarpin C, Bardou V-J, Bertucci F, Ginestier C, Braud A-C, Puig B, Geneix J, Hassoun J, Birnbaum D, Jacquemier J, Viens P (2004). Immunophenotypic analysis of inflammatory breast cancers: identification of an "inflammatory signature". *J Pathol.* 202:265–73.
- Charavaryamath C, Gonzalez-Cano P, Fries P, Gomis S, Doig K, Scruten E, Potter A, Napper S, Griebel PJ (2013). Host responses to persistent *Mycobacterium avium* subspecies *paratuberculosis* infection in surgically isolated bovine ileal segments. *Clin Vaccine Immunol.* 20:156–65.
- Chevillat NF, Hostetter J, Thomsen B V, Simutis F, Vanloubbeeck Y, Steadham E (2001). Intracellular trafficking of *Mycobacterium avium* ss. *paratuberculosis* in macrophages. *Dtsch Tierarztl Wochenschr.* 108:236–43.
- Chiodini RJ (1989). Crohn's disease and the mycobacterioses: A review and comparison of two disease entities. *Clin Microbiol Rev.* 2:90–117.
- Chiodini RJ (1996). Immunology: resistance to paratuberculosis. *Vet Clin North Am Food Anim Pract.* 12:313–43.
- Chiodini RJ, Davis WC (1992). The cellular immunology of bovine paratuberculosis: the predominant response is mediated by cytotoxic gamma/delta T lymphocytes which prevent CD4+ activity. *Microb Pathog.* 13:447–63.
- Chiodini RJ, Van Kruiningen HJ, Merkal RS (1984). Ruminant paratuberculosis (Johne's disease): the current status and future prospects. *Cornell Vet.* 74:218–262.
- Clarke CJ (1997). The pathology and pathogenesis of *paratuberculosis* in ruminants and other species. *J Comp Pathol.* 116:217–61.
- Clarke CJ, Little D (1996). The pathology of ovine *paratuberculosis*: gross and histological changes in the intestine and other tissues. *J Comp Pathol.* 114:419–37.
- Coelho AC, Pinto ML, Silva S, Coelho AM, Rodrigues J, Juste RA (2007). Seroprevalence of ovine paratuberculosis infection in the Northeast of Portugal. *Small Rumin Res.* 71: 298-303.

- Collins DM, Gabric DM, De Lisle GW (1989). Identification of a repetitive DNA sequence specific to *Mycobacterium paratuberculosis*. FEMS Microbiol Lett. 51:175–8.
- Collins DM, Gabric DM, de Lisle GW (1990). Identification of two groups of *Mycobacterium paratuberculosis* strains by restriction endonuclease analysis and DNA hybridization. J Clin Microbiol. 28:1591–6.
- Collins MT (2011). Food safety concerns regarding paratuberculosis. Vet Clin North Am Food Anim Pract. 27:631–6.
- Cooper AM, Adams LB, Dalton DK, Appelberg R, Ehlers S (2002). IFN-gamma and NO in mycobacterial disease: new jobs for old hands. Trends Microbiol. 10:221–6.
- Cooper AM, Dalton DK, Stewart TA, Griffin JP, Russell DG, Orme IM (1993). Disseminated tuberculosis in interferon gamma gene-disrupted mice. J Exp Med. 178:2243–7.
- Cooper AM, Flynn JL (1995). The protective immune response to *Mycobacterium tuberculosis*. Curr Opin Immunol. 7:512–6.
- Corpa JM, Juste RA, García Marín JF, Reyes LE, González J, Pérez V (2001). Distribution of lymphocyte subsets in the small intestine lymphoid tissue of 1-month-old lambs. Anat Histol Embryol. 30:121–7.
- Corpa JM, Pérez V, Sánchez MA, Marín JF (2000). Control of paratuberculosis (Johne's disease) in goats by vaccination of adult animals. Vet Rec. 146:195–6.
- Corr SC, Gahan CCGM, Hill C (2008). M-cells: origin, morphology and role in mucosal immunity and microbial pathogenesis. FEMS Immunol Med Microbiol. 52:2–12.
- Coussens PM (2001). *Mycobacterium paratuberculosis* and the bovine immune system. Anim Heal Res Rev. 2:141–61.
- Coussens PM, Verman N, Coussens MA, Elftman MD, McNulty AM (2004). Cytokine gene expression in peripheral blood mononuclear cells and tissues of cattle infected with *Mycobacterium avium* subsp. *paratuberculosis*: evidence for an inherent proinflammatory gene expression pattern. Infect Immun. 72:1409–22.
- Curtis MM, Way SS (2009). Interleukin-17 in host defence against bacterial, mycobacterial and fungal pathogens. Immunology. 126:177–85.
- Damato JJ, Collins MT (1990). Growth of *Mycobacterium paratuberculosis* in radiometric, Middlebrook and egg-based media. Vet Microbiol. 22:31–42.
- Davidson MK, Lindsey JR, Davis JK (1987). Requirements and selection of an animal model. Isr J Med Sci. 23:551–5.
- Davies LC, Jenkins SJ, Allen JE, Taylor PR (2013). Tissue-resident macrophages. Nat Immunol. 14:986–95.
- Davies LC, Taylor PR (2015). Tissue-resident macrophages: then and now. Immunology. 144:541–8.
- Davis JM, Ramakrishnan L (2009). The role of the granuloma in expansion and dissemination of early tuberculous infection. Cell. 136:37–49.
- de Almeida DE, Colvin CJ, Coussens PM (2008). Antigen-specific regulatory T cells in bovine paratuberculosis. Vet Immunol Immunopathol. 125:234–45.
- de Juan L, Alvarez J, Romero B, Bezos J, Castellanos E, Aranaz A, Mateos A, Domínguez L (2006). Comparison of four different culture media for isolation and growth of type II and type I/III *Mycobacterium avium* subsp. *paratuberculosis* strains isolated from cattle and goats. Appl Environ Microbiol. 72:5927–32.

- de Juan L, Mateos A, Domínguez L, Sharp JM, Stevenson K (2005). Genetic diversity of *Mycobacterium avium* subspecies *paratuberculosis* isolates from goats detected by pulsed-field gel electrophoresis. *Vet Microbiol.* 106:249–57.
- de Silva K, Begg D, Whittington R (2011). The interleukin 10 response in ovine Johne's disease. *Vet Immunol Immunopathol.* 139:10–6.
- de Vallière S, Abate G, Blazevic A, Heuertz RM, Hoft DF (2005). Enhancement of innate and cell-mediated immunity by antimycobacterial antibodies. *Infect Immun.* 73:6711–20.
- Delgado F, Estrada-Chávez C, Romano M, Paolicchi F, Blanco-Viera F, Capellino F, Chavez-Gris G, Pereira-Suárez AL (2010). Expression of NRAMP1 and iNOS in *Mycobacterium avium* subsp. *paratuberculosis* naturally infected cattle. *Comp Immunol Microbiol Infect Dis.* 33:389–400.
- Delgado L, Juste RA, Muñoz M, Morales S, Benavides J, Ferreras MC, Marín JFG, Pérez V (2012). Differences in the peripheral immune response between lambs and adult ewes experimentally infected with *Mycobacterium avium* subspecies *paratuberculosis*. *Vet Immunol Immunopathol.* 145:23–31.
- Delgado L, Marín JFG, Muñoz M, Benavides J, Juste RA, García-Pariente C, Fuertes M, González J, Ferreras MC, Pérez V (2013). Pathological findings in young and adult sheep following experimental infection with 2 different doses of *Mycobacterium avium* subspecies *paratuberculosis*. *Vet Pathol.* 50:857–66.
- Delgado L (2010). Estudio de la patogenia de la paratuberculosis: relación entre la respuesta inmune y el desarrollo de las lesiones en ovinos jóvenes y adultos. Tesis doctoral. Universidad de León.
- Dennis MM, Reddacliff LA, Whittington RJ (2011). Longitudinal study of clinicopathological features of Johne's disease in sheep naturally exposed to *Mycobacterium avium* subspecies *paratuberculosis*. *Vet Pathol.* 48:565–75.
- Detre S, Saclani Jotti G, Dowsett M (1995). A quick score method for immunohistochemical semiquantitation: validation for oestrogen receptor in breast carcinomas. *J Clin Pathol.* 48:876–8.
- Diéguez FJ, Arnaiz I, Sanjuán ML, Vilar MJ, López M, Yus E (2007). Prevalence of serum antibodies to *Mycobacterium avium* subsp. *paratuberculosis* in cattle in Galicia (northwest Spain). *Prev Vet Med.* 82:321–6.
- Diéguez FJ, Arnaiz I, Sanjuán ML, Vilar MJ, Yus E (2008). Management practices associated with *Mycobacterium avium* subspecies *paratuberculosis* infection and the effects of the infection on dairy herds. *Vet Rec.* 162:614–7.
- Dimareli-Malli Z, Mazaraki K, Stevenson K, Tsakos P, Zdragas A, Giantzi V, Petridou E, Heron I, Vafeas G (2013). Culture phenotypes and molecular characterization of *Mycobacterium avium* subsp. *paratuberculosis* isolates from small ruminants. *Res Vet Sci.* 95:49–53.
- Dinarelli CA (1996). Cytokines as mediators in the pathogenesis of septic shock. *Curr Top Microbiol Immunol.* 216:133–65.
- DiRita VJ, Engleberg NC, Heath A, Miller A, Crawford JA, Yu R (2000). Virulence gene regulation inside and outside. *Philos Trans R Soc Lond B Biol Sci.* 355:657–65.
- Donat K, Schlotter K, Erhardt G, Brandt HR (2014). Prevalence of *paratuberculosis* in cattle and control measures within the herd influence the performance of ELISA tests. *Vet Rec.* 174:119.
- Donat K, Schmidt M, Köhler H, Sauter-Louis C (2016) Management of the calving pen is a crucial factor for *paratuberculosis* control in large dairy herds. *J Dairy Sci.* 99:3744–52.

- Doré E, Paré J, Côté G, Buczinski S, Labrecque O, Roy JP, Fecteau G (2012). Risk factors associated with transmission of *Mycobacterium avium* subsp. *paratuberculosis* to calves within dairy herd: a systematic review. *J Vet Intern Med.* 26:32–45.
- Dorman SE, Holland SM (1998). Mutation in the signal-transducing chain of the interferon-gamma receptor and susceptibility to mycobacterial infection. *J Clin Invest.* 101:2364–9.
- Dorshorst NC, Collins MT, Lombard JE (2006). Decision analysis model for *paratuberculosis* control in commercial dairy herds. *Prev Vet Med.* 75:92–122.
- Doyle AG, Herbein G, Montaner LJ, Minty AJ, Caput D, Ferrara P, Gordon S (1994). Interleukin-13 alters the activation state of murine macrophages in vitro: comparison with interleukin-4 and interferon-gamma. *Eur J Immunol.* 24:1441–5.
- Dukkipati VSR, Ridler AL, Thompson KG, Buddle BM, Hedgespeth BA, Price-Carter M, Begg DJ, Whittington RJ, Gicquel B, Murray A (2016). Experimental infection of New Zealand Merino sheep with a suspension of *Mycobacterium avium* subspecies *paratuberculosis* (*Map*) strain Telford: Kinetics of the immune response, histopathology and *Map* culture. *Vet Microbiol.* 195:136–143.
- Dunn JR, Kaneene JB, Grooms DL, Bolin SR, Bolin CA, Bruning-Fann CS (2005). Effects of positive results for *Mycobacterium avium* subsp *paratuberculosis* as determined by microbial culture of feces or antibody ELISA on results of caudal fold tuberculin test and interferon-gamma assay for tuberculosis in cattle. *J Am Vet Med Assoc.* 226:429–35.
- Dupuis S, Döffinger R, Picard C, Fieschi C, Altare F, Jouanguy E, Abel L, Casanova JL (2000). Human interferon-gamma-mediated immunity is a genetically controlled continuous trait that determines the outcome of mycobacterial invasion. *Immunol Rev.* 178:129–37.
- Ehlers S, Richter E (2001). Differential requirement for interferon-gamma to restrict the growth of or eliminate some recently identified species of nontuberculous mycobacteria in vivo. *Clin Exp Immunol.* 124:229–38.
- Eisenberg SWF, Koets AP, Nielen M, Heederik D, Mortier R, De Buck J, Orsel K (2011). Intestinal infection following aerosol challenge of calves with *Mycobacterium avium* subspecies *paratuberculosis*. *Vet Res.* 42:117.
- Elguezábal N, Chamorro S, Molina E, Garrido JM, Izeta A, Rodrigo L, Juste RA (2012). Lactase persistence, NOD2 status and *Mycobacterium avium* subsp. *paratuberculosis* infection associations to Inflammatory Bowel Disease. *Gut Pathog.* 4:6.
- Ellingson JL, Stabel JR, Bishai WR, Frothingham R, Miller JM (2000). Evaluation of the accuracy and reproducibility of a practical PCR panel assay for rapid detection and differentiation of *Mycobacterium avium* subspecies. *Mol Cell Probes.* 14:153–61.
- Ellingson JLE, Stabel JR, Radcliff RP, Whitlock RH, Miller JM (2005). Detection of *Mycobacterium avium* subspecies *paratuberculosis* in free-ranging bison (*Bison bison*) by PCR. *Mol Cell Probes.* 19:219–25.
- Eltholth MM, Marsh VR, Van Winden S, Guitian FJ (2009). Contamination of food products with *Mycobacterium avium paratuberculosis*: a systematic review. *J Appl Microbiol.* 107:1061–71.
- Espejo LA, Godden S, Hartmann WL, Wells SJ (2012). Reduction in incidence of Johne's disease associated with implementation of a disease control program in Minnesota demonstration herds. *J Dairy Sci.* 95:4141–52.
- Fecteau M-E, Pitta DW, Vecchiarelli B, Indugu N, Kumar S, Gallagher SC, Fyock TL, Sweeney RW (2016). Dysbiosis of the Fecal Microbiota in Cattle Infected with *Mycobacterium avium* subsp. *paratuberculosis*. *PLoS One.* 11:e0160353.

- Fecteau M-E, Whitlock RH (2011). Treatment and chemoprophylaxis for *paratuberculosis*. *Vet Clin North Am Food Anim Pract.* 27:547–57.
- Ferwerda G, Kullberg BJ, de Jong DJ, Girardin SE, Langenberg DML, van Crevel R, Ottenhoff THM, Van der Meer JWM, Netea MG (2007) *Mycobacterium paratuberculosis* is recognized by Toll-like receptors and NOD2. *J Leukoc Biol.* 82:1011–8.
- Fisher CA, Bhattarai EK, Osterstock JB, Dowd SE, Seabury PM, Vikram M, Whitlock RH, Schukken YH, Schnabel RD, Taylor JF, Womack JE, Seabury CM (2011). Evolution of the bovine TLR gene family and member associations with *Mycobacterium avium* subspecies *paratuberculosis* infection. *PLoS One.* 6:e27744.
- Fitzgerald LE, Abendaño N, Juste RA, Alonso-Hearn M (2014) Three-dimensional in vitro models of granuloma to study bacteria-host interactions, drug-susceptibility, and resuscitation of dormant mycobacteria. *Biomed Res Int.* 623856.
- Flesch IE, Hess JH, Oswald IP, Kaufmann SH (1994). Growth inhibition of *Mycobacterium bovis* by IFN-gamma stimulated macrophages: regulation by endogenous tumor necrosis factor-alpha and by IL-10. *Int Immunol.* 6:693–700.
- Flesch IE, Kaufmann SH (1999). Effect of fetal calf serum on cytokine release by bone marrow-derived macrophages during infection with intracellular bacteria. *Immunobiology.* 200:120–7.
- Florou M, Leontides L, Kostoulas P, Billinis C, Sofia M (2009). Strain-specific sensitivity estimates of *Mycobacterium avium* subsp. *paratuberculosis* culture in Greek sheep and goats. *Zoonoses Public Health.* 56: 49-52.
- Florou M, Leontides L, Kostoulas P, Billinis C, Sofia M, Kyriazakis I, Lykotrafitis F (2008). Isolation of *Mycobacterium avium* subspecies *paratuberculosis* from non-ruminant wildlife living in the sheds and on the pastures of Greek sheep and goats. *Epidemiol Infect.* 136:644–52.
- Francis J (1943). Infection of laboratory animals with *Mycobacterium johnei*. *J. Comp. Pathol.* 53: 140-150.
- Frehel C, Canonne-Hergaux F, Gros P, De Chastellier C (2002) Effect of Nramp1 on bacterial replication and on maturation of *Mycobacterium avium*-containing phagosomes in bone marrow-derived mouse macrophages. *Cell Microbiol.* 4:541–56.
- Fritsch I, Luyven G, Köhler H, Lutz W, Möbius P (2012). Suspicion of *Mycobacterium avium* subsp. *paratuberculosis* transmission between cattle and wild-living red deer (*Cervus elaphus*) by multitarget genotyping. *Appl Environ Microbiol.* 78:1132–9.
- Fritsche G, Dlaska M, Barton H, Theurl I, Garimorth K, Weiss G (2003). Nramp1 functionality increases inducible nitric oxide synthase transcription via stimulation of IFN regulatory factor 1 expression. *J Immunol.* 171:1994–8.
- Ganusov V V, Klinkenberg D, Bakker D, Koets AP (2015). Evaluating contribution of the cellular and humoral immune responses to the control of shedding of *Mycobacterium avium* spp. *paratuberculosis* in cattle. *Vet Res.* 46:62.
- Gao A, Odumeru J, Raymond M, Hendrick S, Duffield T, Mutharia L (2009). Comparison of milk culture, direct and nested polymerase chain reaction (PCR) with fecal culture based on samples from dairy herds infected with *Mycobacterium avium* subsp. *paratuberculosis*. *Can J Vet Res.* 73:58–64.
- Garcia AB, Shalloo L (2015). Invited review: The economic impact and control of *paratuberculosis* in cattle. *J Dairy Sci.* 98:5019–39.
- García Marín JF, Benazzi S, Pérez V, Badiola JJ (1992). Study of entrance of *M. paratuberculosis* in the lambs intestinal mucosa using immunohistochemical methods for antigens detection. En: Chiodini, R.J.; Kreeger, J.M. (Eds.). *Proc 3rd Int. Coll. PTBC. IAP.* Providence. EE.UU. pp 371-377.

- García Marín JF, Pérez V, González J (2000). La interacción bovino-bacteria y los mecanismos de enfermedad. En: Juste Editor. Paratuberculosis. BOVIS, Aula Veterinaria. 93: 29-38.
- García Marín JF, Peris B, Juste R, Pérez V, Chávez, G, Bolea R, Gutiérrez M, Tellechea JM, Badiola JJ (1995). Studies on pathogenesis of ovine paratuberculosis. Proc. XIII Congr. Eur Soc.Vet Pathol. Edimburgo. Reino Unido.67.
- García-Marín JF, Pérez V (1994). Diagnóstico de casos clínicos de paratuberculosis ovina y caprina. Med Vet. 11:491-502.
- Garrido J, Adúriz G, Geijo M, Sevilla, I, Juste, R. (2002). Comparison of different indirect ELISA methods on reference cattle. Proceedings of the 7th International Colloquium on *Paratuberculosis*. Bilbao, España.
- Garrido JM (2001). Puesta a punto de las técnicas de PCR en heces y de ELISA para el diagnóstico de la paratuberculosis. Estudio de prevalencia en ganado bovino. Tesis Doctoral. Universidad de Zaragoza.
- Geijo MV (2007). Estudio de variables inmunológicas y bacteriológicas en relación con la inmunización frente a paratuberculosis en los rumiantes. Universidad de León.
- Geissmann F, Manz MG, Jung S, Sieweke MH, Merad M, Ley K (2010). Development of monocytes, macrophages, and dendritic cells. Science. 327:656–61.
- Geraghty T, Graham DA, Mullowney P, More SJ (2014). A review of bovine Johne's disease control activities in 6 endemically infected countries. Prev Vet Med. 116:1–11.
- Gerhardt T, Ley K (2015). Monocyte trafficking across the vessel wall. Cardiovasc Res. 107:321–30.
- Gessani S, Belardelli F (1998). IFN-gamma expression in macrophages and its possible biological significance. Cytokine Growth Factor Rev. 9:117–23.
- Ghosh P, Hsu C, Alyamani EJ, Shehata MM, Al-Dubaib MA, Al-Naeem A, Hashad M, Mahmoud OM, Alharbi KBJ, Al-Busadah K, Al-Swailem AM, Talaat AM (2012). Genome-wide analysis of the emerging infection with *Mycobacterium avium* subspecies *paratuberculosis* in the Arabian camels (*Camelus dromedarius*). PLoS One. 7:e31947.
- Gil O, Díaz I, Vilaplana C, Tapia G, Díaz J, Fort M, Cáceres N, Pinto S, Caylà J, Corner L, Domingo M, Cardona P-J (2010). Granuloma encapsulation is a key factor for containing tuberculosis infection in minipigs. PLoS One. 5:e10030.
- Gilardoni LR, Paolicchi FA, Mundo SL (2012). Bovine *paratuberculosis*: a review of the advantages and disadvantages of different diagnostic tests. Rev Argent Microbiol. 44:201–15.
- Gill CO, Saucier L, Meadus WJ (2011). *Mycobacterium avium* subsp. *paratuberculosis* in dairy products, meat, and drinking water. J Food Prot. 74:480–99.
- Gillan S, O'Brien R, Hughes AD, Griffin JFT (2010). Identification of immune parameters to differentiate disease states among sheep infected with *Mycobacterium avium* subsp. *paratuberculosis*. Clin Vaccine Immunol. 17:108–17.
- Glawischnig W, Steineck T, Spersger J (2006). Infections caused by *Mycobacterium avium* subspecies *avium*, *hominissuis*, and *paratuberculosis* in free-ranging red deer (*Cervus elaphus hippelaphus*) in Austria, 2001-2004. J Wildl Dis.
- González J, Geijo MV, García-Pariente C, Verna A, Corpa JM, Reyes LE, Ferreras MC, Juste RA, García Marín JF, Pérez V (2005). Histopathological classification of lesions associated with natural paratuberculosis infection in cattle. J Comp Pathol. 133:184–96.
- Gordon S, Martinez FO (2010). Alternative activation of macrophages: mechanism and functions. Immunity. 32:593–604.
- Gordon S, Taylor PR (2005) Monocyte and macrophage heterogeneity. Nat Rev Immunol. 5:953–64.

- Green EP, Moss MT, Hermon-Taylor J, McFadden JJ (1989). Insertion elements in mycobacteria. *Acta Leprol* 7 Suppl. 1:239–42.
- Greenstein RJ (2003). Is Crohn's disease caused by a *Mycobacterium*? Comparisons with leprosy, tuberculosis, and Johne's disease. *Lancet Infect Dis*. 3:507–14.
- Groenendaal H, Nielen M, Jalvingh AW, Horst SH, Galligan DT, Hesselink JW (2002). A simulation of Johne's disease control. *Prev Vet Med*. 54:225–45.
- Guirado E, Schlesinger LS (2013). Modeling the *Mycobacterium tuberculosis* Granuloma - the Critical Battlefield in Host Immunity and Disease. *Front Immunol*. 4:98.
- Gwozdz JM, Thompson KG, Manktelow BW (2001). Lymphocytic neuritis of the ileum in sheep with naturally acquired and experimental paratuberculosis. *J Comp Pathol*. 124:317–20.
- Gwozdz JM, Thompson KG, Manktelow BW, Murray A, West DM (2000) Vaccination against paratuberculosis of lambs already infected experimentally with *Mycobacterium avium* subspecies *paratuberculosis*. *Aust Vet J*. 78:560–6.
- Hackam DJ, Rotstein OD, Zhang W, Gruenheid S, Gros P, Grinstein S (1998) Host resistance to intracellular infection: mutation of natural resistance-associated macrophage protein 1 (Nramp1) impairs phagosomal acidification. *J Exp Med*. 188:351–64.
- Hao N-B, Lü M-H, Fan Y-H, Cao Y-L, Zhang Z-R, Yang S-M (2012). Macrophages in tumor microenvironments and the progression of tumors. *Clin Dev Immunol*. 2012:948098.
- Harris NB, Barletta RG (2001). *Mycobacterium avium* subsp. *paratuberculosis* in Veterinary Medicine. *Clin Microbiol Rev*. 14:489–512.
- Hayday AC (2000). Gamma delta cells: a right time and a right place for a conserved third way of protection. *Annu Rev Immunol*. 18:975–1026.
- Hedges JF, Lubick KJ, Jutila MA (2005). Gamma delta T cells respond directly to pathogen-associated molecular patterns. *J Immunol*. 174:6045–53.
- Hein WR, Griebel PJ (2003). A road less travelled: large animal models in immunological research. *Nat Rev Immunol*. 3:79–84.
- Hermon-Taylor J, Bull TJ, Sheridan JM, Cheng J, Stellakis ML, Sumar N (2000). Causation of Crohn's disease by *Mycobacterium avium* subspecies *paratuberculosis*. *Can J Gastroenterol*. 14:521–39.
- Hilbink F, West DM, de Lisle GW, Kittelberger R, Hosie BD, Hutton J, Cooke MM, Penrose M (1994). Comparison of a complement fixation test, a gel diffusion test and two absorbed and unabsorbed ELISAs for the diagnosis of paratuberculosis in sheep. *Vet Microbiol*. 41:107–16.
- Hines II ME, Stabel JR, Sweeney RW, Griffin F, Talaat AM, Bakker D, Benedictus G, Davis WC, de Lisle GW, Gardner IA, Juste RA, Kapur V, Koets A, McNair J, Pruitt G, Whitlock RH (2007). Experimental challenge models for Johne's disease: a review and proposed international guidelines. *Vet Microbiol*. 122:197–222.
- Hines II ME, Styer EL (2003). Preliminary characterization of chemically generated *Mycobacterium avium* subsp. *paratuberculosis* cell wall deficient forms (spheroplasts). *Vet Microbiol*. 95:247–58.
- Hines ME, Turnquist SE, Ilha MRS, Rajeev S, Jones AL, Whittington L, Bannantine JP, Barletta RG, Gröhn YT, Katani R, Talaat AM, Li L, Kapur V (2014). Evaluation of novel oral vaccine candidates and validation of a caprine model of Johne's disease. *Front Cell Infect Microbiol*. 4:26.
- Hori S, Nomura T, Sakaguchi S (2003). Control of regulatory T cell development by the transcription factor Foxp3. *Science*. 299:1057–61.

- Hostetter J, Huffman E, Byl K, Steadham E (2005). Inducible nitric oxide synthase immunoreactivity in the granulomatous intestinal lesions of naturally occurring bovine Johne's disease. *Vet Pathol.* 42:241–9.
- Hostetter J, Steadham E, Haynes J, Bailey T, Cheville N (2003). Phagosomal maturation and intracellular survival of *Mycobacterium avium* subspecies *paratuberculosis* in J774 cells. *Comp Immunol Microbiol Infect Dis.* 26:269–83.
- Hostetter JM, Steadham EM, Haynes JS, Bailey TB, Cheville NF (2002). Cytokine effects on maturation of the phagosomes containing *Mycobacteria avium* subspecies *paratuberculosis* in J774 cells. *FEMS Immunol Med Microbiol.* 34:127–34.
- Huang Z, Luo Q, Guo Y, Chen J, Xiong G, Peng Y, Ye J, Li J (2015). *Mycobacterium tuberculosis*-Induced Polarization of Human Macrophage Orchestrates the Formation and Development of Tuberculous Granulomas In Vitro. *PLoS One.* 10:e0129744.
- Hugot JP, Chamaillard M, Zouali H, Lesage S, Cézard JP, Belaiche J, Almer S, Tysk C, O'Morain CA, Gassull M, Binder V, Finkel Y, Cortot A, Modigliani R, Laurent-Puig P, Gower-Rousseau C, Macry J, Thomas G (2001). Association of NOD2 leucine-rich repeat variants with susceptibility to Crohn's disease. *Nature.* 411:599–603.
- Hutchings MR, Stevenson K, Greig A, Davidson R, Marion G, Judge J (2010). Infection of non-ruminant wildlife by *Mycobacterium avium* subsp. *paratuberculosis*. In: Behr MA, Collins DM, editors. *Paratuberculosis: Organism, Disease, Control.* Cambridge: MA: CAB International. 188–200.
- Irenge LM, Walravens K, Govaerts M, Godfroid J, Rosseels V, Huygen K, Gala J-L (2009) Development and validation of a triplex real-time PCR for rapid detection and specific identification of *M. avium* sub sp. *paratuberculosis* in faecal samples. *Vet Microbiol.* 136:166–72.
- Ito S, Ansari P, Sakatsume M, Dickensheets H, Vazquez N, Donnelly RP, Larner AC, Finbloom DS (1999). Interleukin-10 inhibits expression of both interferon alpha- and interferon gamma- induced genes by suppressing tyrosine phosphorylation of STAT1. *Blood.* 93:1456–63.
- Iwasaki A, Medzhitov R (2004). Toll-like receptor control of the adaptive immune responses. *Nat Immunol.* 5:987–95.
- Jaguin M, Houlbert N, Fardel O, Lecreur V (2013). Polarization profiles of human M-CSF-generated macrophages and comparison of M1-markers in classically activated macrophages from GM-CSF and M-CSF origin. *Cell Immunol.* 281:51–61.
- Janagama HK, Jeong K il, Kapur V, Coussens P, Sreevatsan S (2006). Cytokine responses of bovine macrophages to diverse clinical *Mycobacterium avium* subspecies *paratuberculosis* strains. *BMC Microbiol.* 6:10.
- Jo E-K, Yang C-S, Choi CH, Harding C V (2007). Intracellular signalling cascades regulating innate immune responses to *Mycobacteria*: branching out from Toll-like receptors. *Cell Microbiol.* 9:1087–98.
- Johne HA, Frothingham L (1895). Ein eigenthümlicher Fall von Tuberkulose beim Rind. *Dtsch. Ztschr. Tiermed.Path.* 21: 438-454.
- Johnson C, Wannemuehler M, Hostetter J (2014). *Mycobacterium avium paratuberculosis* infection augments innate immune responses following intestinal epithelial injury. *Exp Biol Med (Maywood).* 239:436–41.
- Johnson DW, Muscoplat CC, Larsen AB, Thoen CO (1977). Skin testing, fecal culture, and lymphocyte immunostimulation in cattle inoculated with *Mycobacterium paratuberculosis*. *Am J Vet Res.* 38:2023–5.
- Johnson-Ifearulundu YJ, Kaneene JB, Sprecher DJ, Gardiner JC, Lloyd JW (2000). The effect of subclinical *Mycobacterium paratuberculosis* infection on days open in Michigan, USA, dairy cows. *Prev Vet Med.* 46:171–81.

- Jouanguy E, Döffinger R, Dupuis S, Pallier A, Altare F, Casanova JL (1999). IL-12 and IFN-gamma in host defense against mycobacteria and salmonella in mice and men. *Curr Opin Immunol.* 11:346–51.
- Juste RA (2010). Crohn's disease and ruminant farming. Got lactase? *Med Hypotheses.* 75:7–13.
- Juste RA, Adúriz JJ (1990). Diagnóstico de la paratuberculosis. *Ovis.* Ed: R. A. Juste. 7:49-62.
- Juste RA, García Marín JF, Peris B, Sáez de Ocáriz CS, Badiola JJ (1994). Experimental infection of vaccinated and non-vaccinated lambs with *Mycobacterium paratuberculosis*. *J Comp Pathol.* 110:185–94.
- Juste RA, Garrido JM, Adúriz G, Moreno B, Geijo MV, García-Goti M, Oguiza JA (2000b). Prevalencia de la paratuberculosis bovina en España. *Cong. Int. Med. Bov. (ANEMBE).* 6:282-285.
- Juste RA, Garrido JM, Adúriz G. (2000a). El agente causal de la *paratuberculosis* y su situación taxonómica. En: Juste RA (Ed). *Paratuberculosis. Bovis, Aula Veterinaria.* 93: 13-28.
- Juste RA, Marco JC, Sáez de Ocáriz C, Adúriz JJ (1991). Comparison of different media for the isolation of small ruminant strains of *Mycobacterium paratuberculosis*. *Vet Microbiol.* 28:385–90.
- Juste RA, Pérez V (2011). Control of paratuberculosis in sheep and goats. *Vet Clin North Am Food Anim Pract.* 27:127–38.
- Juste RA, Vázquez P, Ruiz-Larrañaga O, Iriondo M, Manzano C, Agirre M, Estonba A, Geijo MV, Molina E, Sevilla I, Alonso-Hearn M, Gomez N, Perez V, Cortes A, Garrido JM (2016). Association between genetic polymorphisms and epidemio-pathogenic forms of paratuberculosis. *Proceedings of the 13th International Colloquium on Paratuberculosis.* 51.
- Ka MB, Dumas A, Textoris J, Mege J-L (2014). Phenotypic diversity and emerging new tools to study macrophage activation in bacterial infectious diseases. *Front Immunol.* 5:500.
- Kabara E, Coussens PM (2012). Infection of Primary Bovine Macrophages with *Mycobacterium avium* subspecies *paratuberculosis* Suppresses Host Cell Apoptosis. *Front Microbiol.* 3:215.
- Kaneko H, Yamada H, Mizuno S, Udagawa T, Kazumi Y, Sekikawa K, Sugawara I (1999). Role of tumor necrosis factor-alpha in *Mycobacterium*-induced granuloma formation in tumor necrosis factor-alpha-deficient mice. *Lab Invest.* 79:379–86.
- Kang PB, Azad AK, Torrelles JB, Kaufman TM, Beharka A, Tibesar E, DesJardin LE, Schlesinger LS (2005). The human macrophage mannose receptor directs *Mycobacterium tuberculosis* lipoarabinomannan-mediated phagosome biogenesis. *J Exp Med.* 202:987–99.
- Kasnitz N, Köhler H, Weigoldt M, Gerlach GF, Möbius P (2013). Stability of genotyping target sequences of *Mycobacterium avium* subsp. *paratuberculosis* upon cultivation on different media, in vitro and in vivo passage, and natural infection. *Vet Microbiol.* 167:573–83.
- Kaufmann SH (1991) Role of T-cell subsets in bacterial infections. *Curr Opin Immunol.* 3:465–70.
- Kaur P, Folia G, Singh S V, Patil PK, Sandhu KS (2010). Molecular detection and typing of *Mycobacterium avium* subspecies *paratuberculosis* from milk samples of dairy animals. *Trop Anim Health Prod.* 42:1031–5.
- Kawai T, Akira S (2007). TLR signaling. *Semin Immunol.* 19:24–32.
- Keller SM, Stephan R, Kuenzler R, Meylan M, Wittenbrink MM (2014). Comparison of fecal culture and F57 real-time polymerase chain reaction for the detection of *Mycobacterium avium* subspecies *paratuberculosis* in Swiss cattle herds with a history of *paratuberculosis*. *Acta Vet Scand.* 56:68.
- Kennedy DJ, Benedictus G (2001). Control of *Mycobacterium avium* subsp. *paratuberculosis* infection in agricultural species. *Rev Sci Tech.* 20:151–79.

- Keshav S, Chung P, Milon G, Gordon S (1991). Lysozyme is an inducible marker of macrophage activation in murine tissues as demonstrated by in situ hybridization. *J Exp Med.* 174:1049–58.
- Khalifeh MS, Al-Majali AM, Stabel JR (2009). Role of nitric oxide production in dairy cows naturally infected with *Mycobacterium avium* subsp. *paratuberculosis*. *Vet Immunol Immunopathol.* 131:97–104.
- Khalifeh MS, Stabel JR (2004). Upregulation of transforming growth factor-beta and interleukin-10 in cows with clinical Johne's disease. *Vet Immunol Immunopathol.* 99:39–46.
- Khare S, Lawhon SD, Drake KL, Nunes JES, Figueiredo JF, Rossetti CA, Gull T, Everts RE, Lewin HA, Galindo CL, Garner HR, Adams LG (2012). Systems biology analysis of gene expression during in vivo *Mycobacterium avium paratuberculosis* enteric colonization reveals role for immune tolerance. *PLoS One.* 7:e42127.
- Khol JL, Baumgartner W (2012). Examples and suggestions for the control of paratuberculosis in European cattle. *Jpn J Vet Res.* 60 Suppl:S1-7.
- Kidd P (2003). Th1/Th2 balance: the hypothesis, its limitations, and implications for health and disease. *Altern Med Rev.* 8:223–46.
- Kleinnijenhuis J, Oosting M, Joosten LAB, Netea MG, Van Crevel R (2011). Innate immune recognition of *Mycobacterium tuberculosis*. *Clin Dev Immunol.* 405310.
- Koc A, Bargaen I, Suwandi A, Roderfeld M, Tschuschner A, Rath T, Gerlach GF, Hornef M, Goethe R, Weiss S, Roeb E (2014). Systemic and mucosal immune reactivity upon *Mycobacterium avium* ssp. *paratuberculosis* infection in mice. *PLoS One.* 9:e94624.
- Koets A, Rutten V, Hoek A, van Mil F, Müller K, Bakker D, Gruys E, van Eden W (2002). Progressive bovine *paratuberculosis* is associated with local loss of CD4(+) T cells, increased frequency of gamma delta T cells, and related changes in T-cell function. *Infect Immun.* 70:3856–64.
- Koets AP, Eda S, Sreevatsan S (2015). The within host dynamics of *Mycobacterium avium* ssp. *paratuberculosis* infection in cattle: where time and place matter. *Vet Res.* 46:61.
- Koets AP, Rutten VP, Bakker D, van der Hage MH, van Eden W (2000). Lewis rats are not susceptible to oral infection with *Mycobacterium avium* subsp. *paratuberculosis*. *Vet Microbiol.* 77:487–95.
- Koets AP, Rutten VP, de Boer M, Bakker D, Valentin-Weigand P, van Eden W (2001). Differential changes in heat shock protein-, lipoarabinomannan-, and purified protein derivative-specific immunoglobulin G1 and G2 isotype responses during bovine *Mycobacterium avium* subsp. *paratuberculosis* infection. *Infect Immun.* 69:1492-8.
- Köhler H, Soschinka A, Meyer M, Kather A, Reinhold P, Liebler-Tenorio E (2015) Characterization of a caprine model for the subclinical initial phase of *Mycobacterium avium* subsp. *paratuberculosis* infection. *BMC Vet Res.* 11:74.
- Koo HC, Park YH, Hamilton MJ, Barrington GM, Davies CJ, Kim JB, Dahl JL, Waters WR, Davis WC (2004). Analysis of the immune response to *Mycobacterium avium* subsp. *paratuberculosis* in experimentally infected calves. *Infect Immun.* 72:6870–83.
- Krüger C, Köhler H, Liebler-Tenorio EM (2015). Cellular composition of granulomatous lesions in gut-associated lymphoid tissues of goats during the first year after experimental infection with *Mycobacterium avium* subsp. *paratuberculosis*. *Vet Immunol Immunopathol.* 163:33–45.
- Kudahl AB, Nielsen SS (2009) Effect of *paratuberculosis* on slaughter weight and slaughter value of dairy cows. *J Dairy Sci* 92:4340–6.
- Kudahl AB, Nielsen SS, Østergaard S (2008). Economy, efficacy, and feasibility of a risk-based control program against paratuberculosis. *J Dairy Sci.* 91: 4599-609.

- Kuehnel MP, Goethe R, Habermann A, Mueller E, Rohde M, Griffiths G, Valentin-Weigand P (2001). Characterization of the intracellular survival of *Mycobacterium avium* ssp. *paratuberculosis*: phagosomal pH and fusogenicity in J774 macrophages compared with other mycobacteria. *Cell Microbiol.* 3:551–66.
- Kurade NP, Tripathi BN, Rajukumar K, Parihar NS (2004). Sequential development of histologic lesions and their relationship with bacterial isolation, fecal shedding, and immune responses during progressive stages of experimental infection of lambs with *Mycobacterium avium* subsp. *paratuberculosis*. *Vet Pathol.* 41:378–87.
- Labonte AC, Tosello-Tramont A-C, Hahn YS (2014). The role of macrophage polarization in infectious and inflammatory diseases. *Mol Cells.* 37:275–85.
- Lambeth C, Reddacliff LA, Windsor P, Abbott KA, McGregor H, Whittington RJ (2004). Intrauterine and transmammary transmission of *Mycobacterium avium* subsp. *paratuberculosis* in sheep. *Aust Vet J.* 82:504–8.
- Larsen AB, Merkall RS, Cutlip RC (1975). Age of cattle as related to resistance to infection with *Mycobacterium paratuberculosis*. *Am J Vet Res.* 36:255–7.
- Laurin E, McKenna S, Chaffer M, Keefe G (2015). Sensitivity of solid culture, broth culture, and real-time PCR assays for milk and colostrum samples from *Mycobacterium avium* ssp. *paratuberculosis*-infectious dairy cows. *J Dairy Sci.* 98:8597–609.
- Lee A, Griffiths TA, Parab RS, King RK, Dubinsky MC, Urbanski SJ, Wrobel I, Rioux KP (2011). Association of *Mycobacterium avium* subspecies *paratuberculosis* with Crohn Disease in pediatric patients. *J Pediatr Gastroenterol Nutr.* 52:170–4.
- Lee H, Stabel JR, Kehrl ME (2001). Cytokine gene expression in ileal tissues of cattle infected with *Mycobacterium paratuberculosis*. *Vet Immunol Immunopathol.* 82:73–85.
- Lee J, Moon C, Kim J, Jung C, Lee K-H, Joo H-G, Ahn M, Shin T (2009b). Immunohistochemical localization of galectin-3 in the granulomatous lesions of paratuberculosis-infected bovine intestine. *J Vet Sci.* 10:177–80.
- Lee JS, Shin SJ, Collins MT, Jung ID, Jeong Y-I, Lee C-M, Shin YK, Kim D, Park Y-M (2009a). *Mycobacterium avium* subsp. *paratuberculosis* fibronectin attachment protein activates dendritic cells and induces a Th1 polarization. *Infect Immun.* 77:2979–88.
- Lehmann KB, Neumann RO (1896). *Atlas und Grundriss der Bakteriologie und Lehrbuch der speziellen bakteriologischen Diagnostik, Teil II*, p. 363-448. (cited from "Index Bergeyana," 1966. Buchanan RE, Holt JG, Lessei, EF. (eds). The Williams and Wilkins Co., Baltimore.1-1472,
- Liu Y-C, Zou X-B, Chai Y-F, Yao Y-M (2014). Macrophage polarization in inflammatory diseases. *Int J Biol Sci.* 10:520–9.
- Lombard JE (2011). Epidemiology and economics of paratuberculosis. *Vet Clin North Am Food Anim Pract.* 27:525–35, v.
- Lombard JE, Garry FB, McCluskey BJ, Wagner BA (2005) Risk of removal and effects on milk production associated with paratuberculosis status in dairy cows. *J Am Vet Med Assoc.* 227:1975–81.
- Lugo-Villarino G, Vérollet C, Maridonneau-Parini I, Neyrolles O (2011). Macrophage polarization: convergence point targeted by *Mycobacterium tuberculosis* and HIV. *Front Immunol.* 2:43.
- Lugton I (1999). Mucosa-associated lymphoid tissues as sites for uptake, carriage and excretion of tubercle bacilli and other pathogenic mycobacteria. *Immunol Cell Biol.* 77:364–72.
- Lybeck KR, Løvoll M, Johansen TB, Olsen I, Storset AK, Valheim M (2013). Intestinal strictures, fibrous adhesions and high local interleukin-10 levels in goats infected naturally with *Mycobacterium avium* subsp. *paratuberculosis*. *J Comp Pathol.* 148:157–72.

- Maarifi G, Maroui MA, Dutrieux J, Dianoux L, Nisole S, Chelbi-Alix MK (2015). Small Ubiquitin-like Modifier Alters IFN Response. *J Immunol.* 195:2312–24.
- Määttänen P, Trost B, Scruten E, Potter A, Kusalik A, Griebel P, Napper S (2013). Divergent immune responses to *Mycobacterium avium* subsp. *paratuberculosis* infection correlate with kinome responses at the site of intestinal infection. *Infect Immun.* 81:2861–72.
- Mackanness GB (2014). Pillars article: cellular resistance to infection. *J. Exp. Med.* 196: 381-406. *J Immunol.* 193:3185–221.
- Mackintosh CG, Clark RG, Thompson B, Tolentino B, Griffin JFT, de Lisle GW (2010). Age susceptibility of red deer (*Cervus elaphus*) to *paratuberculosis*. *Vet Microbiol.* 143:255–61.
- Mackintosh CG, Labes RE, Clark RG, de Lisle GW, Griffin JFT (2007). Experimental infections in young red deer (*Cervus elaphus*) with a bovine and an ovine strain of *Mycobacterium avium* subsp. *paratuberculosis*. *N Z Vet J.* 55:23–9.
- MacMicking J, Xie QW, Nathan C (1997). Nitric oxide and macrophage function. *Annu Rev Immunol.* 15:323–50.
- Madge DS (1971). Malabsorption in C57 mice experimentally infected with Johne's. *40: 649-58.*
- Magombedze G, Eda S, Stabel J (2015). Predicting the Role of IL-10 in the Regulation of the Adaptive Immune Responses in *Mycobacterium avium* Subsp. *paratuberculosis* Infections Using Mathematical Models. *PLoS One.* 10:e0141539.
- Maio E, Carta T, Balseiro A, Sevilla IA, Romano A, Ortiz JA, Vieira-Pinto M, Garrido JM, de la Lastra JMP, Gortázar C (2011). Paratuberculosis in European wild rabbits from the Iberian Peninsula. *Res Vet Sci.* 91:212–8.
- Manning EJ, Collins MT (2001). *Mycobacterium avium* subsp. *paratuberculosis*: pathogen, pathogenesis and diagnosis. *Rev Sci Tech.* 20:133–50.
- Mantovani A, Sica A, Sozzani S, Allavena P, Vecchi A, Locati M (2004). The chemokine system in diverse forms of macrophage activation and polarization. *Trends Immunol.* 25:677–86.
- Mapara M, Thomas BS, Bhat KM (2012). Rabbit as an animal model for experimental research. *Dent Res J (Isfahan).* 9:111–8.
- Marino S, Cilfone NA, Mattila JT, Linderman JJ, Flynn JL, Kirschner DE (2015). Macrophage polarization drives granuloma outcome during *Mycobacterium* infection. *Infect Immun.* 83:324–38.
- Marino S, Sud D, Plessner H, Lin PL, Chan J, Flynn JL, Kirschner DE (2007). Differences in reactivation of tuberculosis induced from anti-TNF treatments are based on bioavailability in granulomatous tissue. *PLoS Comput Biol.* 3:1909–24.
- Marsh I, Whittington R, Cousins D (1999). PCR-restriction endonuclease analysis for identification and strain typing of *Mycobacterium avium* subsp. *paratuberculosis* and *Mycobacterium avium* subsp. *avium* based on polymorphisms in IS1311. *Mol Cell Probes.* 13:115–26.
- Martinez FO, Gordon S (2014). The M1 and M2 paradigm of macrophage activation: time for reassessment. *F1000Prime Rep.* 6:13.
- McAloon CG, Doherty ML, Donlon J, Lorenz I, Meade J, O'Grady L, Whyte P (2016). Microbiological contamination of colostrum on Irish dairy farms. *Vet Rec.* 178:474.
- McGregor H, Dhand NK, Dhungyel OP, Whittington RJ (2012). Transmission of *Mycobacterium avium* subsp. *paratuberculosis*: dose-response and age-based susceptibility in a sheep model. *Prev Vet Med.* 107:76–84.
- Medzhitov R, Janeway CA (1997). Innate immunity: impact on the adaptive immune response. *Curr Opin Immunol.* 9:4–9.

- Merkal RS, Lyle PS, Whipple DL (1981). Heat inactivation of in vivo- and in vitro-grown mycobacteria in meat products. *Appl Environ Microbiol.* 41:1484–5.
- Merkal RS, Miller JM, Hintz AM, Bryner JH (1982). Intrauterine inoculation of *Mycobacterium paratuberculosis* into guinea pigs and cattle. *Am J Vet Res.* 43:676–8.
- Mijs W, de Haas P, Rossau R, Van der Laan T, Rigouts L, Portaels F, van Soolingen D (2002). Molecular evidence to support a proposal to reserve the designation *Mycobacterium avium* subsp. *avium* for bird-type isolates and “*M. avium* subsp. *hominissuis*” for the human/porcine type of *M. avium*. *Int J Syst Evol Microbiol.* 52:1505–18.
- Miller BH, Fratti RA, Poschet JF, Timmins GS, Master SS, Burgos M, Marletta MA, Deretic V (2004). Mycobacteria inhibit nitric oxide synthase recruitment to phagosomes during macrophage infection. *Infect Immun.* 72:2872–8.
- Miller H, Zhang J, Kuolee R, Patel GB, Chen W (2007). Intestinal M cells: the fallible sentinels? *World J Gastroenterol.* 13:1477–86.
- Mills CD, Kincaid K, Alt JM, Heilman MJ, Hill AM (2000). M-1/M-2 macrophages and the Th1/Th2 paradigm. *J Immunol.* 164:6166–73.
- Mills KHG (2004). Regulatory T cells: friend or foe in immunity to infection? *Nat Rev Immunol.* 4:841–55.
- Mishina D, Katsel P, Brown ST, Gilberts EC, Greenstein RJ (1996) On the etiology of Crohn disease. *Proc Natl Acad Sci USA.* 93:9816–20.
- Mitchell RM, Schukken Y, Koets A, Weber M, Bakker D, Stabel J, Whitlock RH, Louzoun Y (2015). Differences in intermittent and continuous fecal shedding patterns between natural and experimental *Mycobacterium avium* subspecies *paratuberculosis* infections in cattle. *Vet Res.* 46:66.
- Miyake K, Yamashita Y, Ogata M, Sudo T, Kimoto M (1995). RP105, a novel B cell surface molecule implicated in B cell activation, is a member of the leucine-rich repeat protein family. *J Immunol.* 154:3333–40.
- Mohamed YC, Fernández M, Pérez V (2013). Estudio de la prevalencia de la paratuberculosis bovina en dos rebaños lecheros mediante métodos inmunológicos. *Proceedings del XVIII Congreso Internacional ANEMBE de Medicina Bovina.* 18: 179-181.
- Mokresh AH, Butler DG (1990). Granulomatous enteritis following oral inoculation of newborn rabbits with *Mycobacterium paratuberculosis* of bovine origin. *Can J Vet. Res* 54:313–9.
- Moloney BJ, Whittington RJ (2008). Cross species transmission of ovine Johne’s disease from sheep to cattle: an estimate of prevalence in exposed susceptible cattle. *Aust Vet J.* 86:117–23.
- Momotani E, Whipple DL, Thiermann AB, Chevillie NF (1988). Role of M cells and macrophages in the entrance of *Mycobacterium paratuberculosis* into domes of ileal Peyer’s patches in calves. *Vet Pathol.* 25:131–7.
- More SJ, Cameron AR, Strain S, Cashman W, Ezanno P, Kenny K, Fourichon C, Graham D (2015). Evaluation of testing strategies to identify infected animals at a single round of testing within dairy herds known to be infected with *Mycobacterium avium* ssp. *paratuberculosis*. *J Dairy Sci.* 98:5194–210.
- Mortier RAR, Barkema HW, Bystrom JM, Illanes O, Orsel K, Wolf R, Atkins G, De Buck J (2013). Evaluation of age-dependent susceptibility in calves infected with two doses of *Mycobacterium avium* subspecies *paratuberculosis* using pathology and tissue culture. *Vet Res.* 44:94.
- Mortier RAR, Barkema HW, De Buck J (2015). Susceptibility to and diagnosis of *Mycobacterium avium* subspecies *paratuberculosis* infection in dairy calves: A review. *Prev Vet Med.* 121:189–98.

- Mortier RAR, Barkema HW, Negron ME, Orsel K, Wolf R, De Buck J (2014) Antibody response early after experimental infection with *Mycobacterium avium* subspecies *paratuberculosis* in dairy calves. *J Dairy Sci.* 97:5558–65.
- Mosser DM, Edwards JP (2008). Exploring the full spectrum of macrophage activation. *Nat Rev Immunol.* 8:958–69.
- Motiwala AS, Amonsin A, Strother M, Manning EJB, Kapur V, Sreevatsan S (2004). Molecular epidemiology of *Mycobacterium avium* subsp. *paratuberculosis* isolates recovered from wild animal species. *J Clin Microbiol.* 42:1703–12.
- Mucha R, Bhide MR, Chakurkar EB, Novak M, Mikula I (2009). Toll-like receptors TLR1, TLR2 and TLR4 gene mutations and natural resistance to *Mycobacterium avium* subsp. *paratuberculosis* infection in cattle. *Vet Immunol Immunopathol.* 128:381–8.
- Munjal SK, Tripathi BN, Paliwal OP (2005) Progressive immunopathological changes during early stages of experimental infection of goats with *Mycobacterium avium* subspecies *paratuberculosis*. *Vet Pathol* 42:427–36.
- Muñoz M, Delgado L, Verna A, Benavides J, García-Pariente C, Fuertes M, Ferreras MC, García-Marín JF, Pérez V (2009). Expression of transforming growth factor-beta 1 (TGF-beta1) in different types of granulomatous lesions in bovine and ovine *paratuberculosis*. *Comp Immunol Microbiol Infect Dis.* 32:239–52.
- Muñoz M (2014). Eficacia de una vacuna inactivada frente a la paratuberculosis bovina en un modelo experimental en terneros y su influencia en la patogenia de la enfermedad. Tesis doctoral. Universidad de León.
- Münster P, Völkel I, Wemheuer W, Schwarz D, Döring S, Czerny C-P (2013). A longitudinal study to characterize the distribution patterns of *Mycobacterium avium* ssp. *paratuberculosis* in semen, blood and faeces of a naturally infected bull by IS 900 semi-nested and quantitative real-time PCR. *Transbound Emerg Dis.* 60:175–87.
- Murphy JT, Sommer S, Kabara EA, Verman N, Kuelbs MA, Saama P, Halgren R, Coussens PM (2006). Gene expression profiling of monocyte-derived macrophages following infection with *Mycobacterium avium* subspecies *avium* and *Mycobacterium avium* subspecies *paratuberculosis*. *Physiol Genomics.* 28:67–75.
- Mutwiri GK, Butler DG, Rosendal S, Yager J (1992). Experimental infection of severe combined immunodeficient beige mice with *Mycobacterium paratuberculosis* of bovine origin. *Infect Immun.* 60:4074–9.
- Nalubamba K, Smeed J, Gossner A, Watkins C, Dalziel R, Hopkins J (2008). Differential expression of pattern recognition receptors in the three pathological forms of sheep paratuberculosis. *Microbes Infect.* 10:598–604.
- Naser SA, Ghobrial G, Romero C, Valentine JF (2004). Culture of *Mycobacterium avium* subspecies *paratuberculosis* from the blood of patients with Crohn's disease. *Lancet (London, England).* 364:1039–44.
- Nathan C (2008). Metchnikoff's Legacy in 2008. *Nat Immunol.* 9:695–8.
- National Advisory Committee on Microbiological Criteria for Foods (NACMCF) (2010). Assessment of food as a source of exposure to *Mycobacterium avium* subspecies *paratuberculosis* (MAP). *J Food Prot.* 73:1357–97.
- Navarro JA, Ramis G, Seva J, Pallarés FJ, Sánchez J (1998). Changes in lymphocyte subsets in the intestine and mesenteric lymph nodes in caprine paratuberculosis. *J Comp Pathol.* 118:109–21.
- Nielsen SS, Toft N (2008). Ante mortem diagnosis of *paratuberculosis*: a review of accuracies of ELISA, interferon-gamma assay and faecal culture techniques. *Vet Microbiol.* 129:217–35.

- Nielsen SS, Toft N (2009). A review of prevalences of *paratuberculosis* in farmed animals in Europe. *Prev Vet Med.* 88:1–14.
- Nisbet DI, Gilmour NJ, Brotherston JG (1962). Quantitative studies of *Mycobacterium johnei* in tissues of sheep. III. Intestinal histopathology. *J Comp Pathol.* 72:80–91.
- Noss EH, Pai RK, Sellati TJ, Radolf JD, Belisle J, Golenbock DT, Boom WH, Harding C V (2001). Toll-like receptor 2-dependent inhibition of macrophage class II MHC expression and antigen processing by 19-kDa lipoprotein of *Mycobacterium tuberculosis*. *J Immunol.* 167:910–8.
- O'Brien R, Mackintosh CG, Bakker D, Kopecna M, Pavlik I, Griffin JFT (2006). Immunological and molecular characterization of susceptibility in relationship to bacterial strain differences in *Mycobacterium avium* subsp. *paratuberculosis* infection in the red deer (*Cervus elaphus*). *Infect Immun.* 74:3530–7.
- Ogata H, Su I, Miyake K, Nagai Y, Akashi S, Mecklenbräuker I, Rajewsky K, Kimoto M, Tarakhovsky A (2000). The toll-like receptor protein RP105 regulates lipopolysaccharide signaling in B cells. *J Exp Med.* 192:23–9.
- Ohsawa K, Imai Y, Sasaki Y, Kohsaka S (2004). Microglia/macrophage-specific protein Iba1 binds to fimbrin and enhances its actin-bundling activity. *J Neurochem.* 88:844–56.
- Okagawa T, Konnai S, Nishimori A, Ikebuchi R, Mizorogi S, Nagata R, Kawaji S, Tanaka S, Kagawa Y, Murata S, Mori Y, Ohashi K (2015). Bovine Immunoinhibitory Receptors Contribute to Suppression of *Mycobacterium avium* subsp. *paratuberculosis*-Specific T-Cell Responses. *Infect Immun.* 84:77–89.
- Olsen I, Sigurðardóttir G, Djønne B (2002). Paratuberculosis with special reference to cattle. A review. *Vet Q.* 24:12–28.
- Orme I (2004). Adaptive immunity to mycobacteria. *Curr Opin Microbiol.* 7:58–61.
- Orme IM (1993). Immunity to mycobacteria. *Curr Opin Immunol.* 5:497–502.
- Orme IM, Basaraba RJ (2014). The formation of the granuloma in tuberculosis infection. *Semin Immunol.* 26:601–9.
- Orme IM, Cooper AM (1999). Cytokine/chemokine cascades in immunity to tuberculosis. *Immunol Today.* 20:307–12.
- Oshiumi H, Matsuo A, Matsumoto M, Seya T (2008). Pan-vertebrate toll-like receptors during evolution. *Curr Genomics.* 9:488–93.
- Ostrowski M, Mundo SL, Harris NB, Barletta RG, Lopez OJ (2003). B-cell epitopes in the immunodominant p34 antigen of *Mycobacterium avium* ssp. *paratuberculosis* recognized by antibodies from infected cattle. *Scand J Immunol.* 58:511–21.
- Ott SL, Wells SJ, Wagner BA (1999). Herd-level economic losses associated with Johne's disease on US dairy operations. *Prev Vet Med.* 40:179–92.
- Pai RK, Convery M, Hamilton TA, Boom WH, Harding C V (2003). Inhibition of IFN-gamma-induced class II transactivator expression by a 19-kDa lipoprotein from *Mycobacterium tuberculosis*: a potential mechanism for immune evasion. *J Immunol.* 171:175–84.
- Pakhomova S, Gao B, Boeglin WE, Brash AR, Newcomer ME (2009). The structure and peroxidase activity of a 33-kDa catalase-related protein from *Mycobacterium avium* ssp. *paratuberculosis*. *Protein Sci.* 18:2559–68.
- Palmer M V, Thacker TC, Waters WR (2015). Analysis of Cytokine Gene Expression using a Novel Chromogenic In-situ Hybridization Method in Pulmonary Granulomas of Cattle Infected Experimentally by Aerosolized *Mycobacterium bovis*. *J Comp Pathol.* 153:150–9.

- Palmer M V, Waters WR, Thacker TC (2007). Lesion development and immunohistochemical changes in granulomas from cattle experimentally infected with *Mycobacterium bovis*. *Vet Pathol.* 44:863–74.
- Park KT, Allen AJ, Barrington GM, Davis WC (2014). Deletion of *relA* abrogates the capacity of *Mycobacterium avium paratuberculosis* to establish an infection in calves. *Front Cell Infect Microbiol.* 4:64.
- Pereira-Suárez AL, Estrada-Chávez C, Arriaga-Díaz C, Espinosa-Cueto P, Mancilla R (2006). Coexpression of NRAMP1, iNOS, and nitrotyrosine in bovine tuberculosis. *Vet Pathol.* 43:709–17.
- Pérez V, Corpa JM, García Marín JF (2000). El cuadro clínico y lesional de la *paratuberculosis* bovina En: Juste Editor. *Paratuberculosis. Bov*, Aula Veterinaria. 93: 39-47.
- Pérez V, García Marín JF, Badiola JJ (1996). Description and classification of different types of lesion associated with natural paratuberculosis infection in sheep. *J Comp Pathol.* 114:107–122.
- Pérez V, Tellechea J, Badiola JJ, Gutiérrez M, García Marín JF (1997). Relation between serologic response and pathologic findings in sheep with naturally acquired paratuberculosis. *Am J Vet Res.* 58:799–803.
- Pérez V, Tellechea J, Corpa JM, Gutiérrez M, García Marín JF (1999). Relation between pathologic findings and cellular immune responses in sheep with naturally acquired paratuberculosis. *Am J Vet Res.* 60:123–7.
- Pérez V, Vázquez P, Fernández M, Ferreras MC (2012). Control de la paratuberculosis. *Pequeños Rumiantes.* 13: 52- 59.
- Pérez V. (1992). Estudio de la *paratuberculosis* en la especie ovina. Tesis doctoral. Universidad de Zaragoza
- Pinedo PJ, Buergelt CD, Donovan GA, Melendez P, Morel L, Wu R, Langae TY, Rae DO (2009). Candidate gene polymorphisms (BoIFNG, TLR4, SLC11A1) as risk factors for paratuberculosis infection in cattle. *Prev Vet Med.* 91:189–96.
- PPompei L, Jang S, Zamlynnny B, Ravikumar S, McBride A, Hickman SP, Salgame P (2007). Disparity in IL-12 release in dendritic cells and macrophages in response to *Mycobacterium tuberculosis* is due to use of distinct TLRs. *J Immunol.* 178:5192–9.
- Ponnusamy D, Periasamy S, Tripathi BN, Pal A (2013). *Mycobacterium avium* subsp. *paratuberculosis* invades through M cells and enterocytes across ileal and jejunal mucosa of lambs. *Res Vet Sci.* 94:306–12.
- Pott J, Basler T, Duerr CU, Rohde M, Goethe R, Hornef MW (2009). Internalization-dependent recognition of *Mycobacterium avium* ssp. *paratuberculosis* by intestinal epithelial cells. *Cell Microbiol.* 11:1802–15.
- Pozzato N, Gwozdz J, Gastaldelli M, Capello K, Dal Ben C, Stefani E (2011). Evaluation of a rapid and inexpensive liquid culture system for the detection of *Mycobacterium avium* subsp. *paratuberculosis* in bovine faeces. *J Microbiol Methods.* 84:413–7.
- Radosevich TJ, Reinhardt TA, Lippolis JD, Bannantine JP, Stabel JR (2007). Proteome and differential expression analysis of membrane and cytosolic proteins from *Mycobacterium avium* subsp. *paratuberculosis* strains K-10 and 187. *J Bacteriol.* 189:1109–17.
- Radostits GM, Gay CC, Hinchcliff KW (2007). *Paratuberculosis* (Johne's disease). En: *Veterinary Medicine.* 10th ed. Elsevier Saunders. Londres. Reino Unido. 1017-1044.
- Raizman EA, Fetrow JP, Wells SJ (2009). Loss of income from cows shedding *Mycobacterium avium* subspecies *paratuberculosis* prior to calving compared with cows not shedding the organism on two Minnesota dairy farms. *J Dairy Sci.* 92:4929–36.

- Ramakrishnan L (2012). Revisiting the role of the granuloma in tuberculosis. *Nat Rev Immunol.* 12:352–66.
- Rawther SS, Saseendranath MR, Nair GPK, Tresamol PV, Pillai UN, Abraham J, Senthilkumar TMA, Nagalakshmy S, Nimisha KKN (2012). Diagnosis of paratuberculosis in goats by cell mediated immune response, conventional and molecular diagnostic techniques. *Trop Anim Health Prod.* 44:911–4.
- Rebhun WC (1995). Infectious diseases of the gastrointestinal tract. En: *Diseases of dairy cattle.* Williams and Wilkins, 1st ed Baltimore, EEUU. 208-213.
- Reddacliff LA, McClure SJ, Whittington RJ (2004). Immunoperoxidase studies of cell mediated immune effector cell populations in early *Mycobacterium avium* subsp. *paratuberculosis* infection in sheep. *Vet Immunol Immunopathol.* 97:149–62.
- Reddacliff LA, Whittington RJ (2003). Experimental infection of weaner sheep with S strain *Mycobacterium avium* subsp. *paratuberculosis*. *Vet Microbiol.* 96:247–58.
- Reyes LE (2007). Evaluación de nuevos adyuvantes en la vacunación frente a la paratuberculosis ovina. Tesis doctoral. Universidad de León.
- Richardson E, More S (2009). Direct and indirect effects of Johne's disease on farm and animal productivity in an Irish dairy herd. *Ir Vet J.* 62:526–32.
- Ridge SE, Morgan IR, Sockett DC, Collins MT, Condrón RJ, Skilbeck NW, Webber JJ (1991). Comparison of the Johne's absorbed EIA and the complement-fixation test for the diagnosis of Johne's disease in cattle. *Aust Vet J.* 68:253–7.
- Rindi L, Garzelli C (2014). Genetic diversity and phylogeny of *Mycobacterium avium*. *Infect Genet Evol.* 21:375–83.
- Ritter C, Jansen J, Roth K, Kastelic JP, Adams CL, Barkema HW (2016). Dairy farmers' perceptions toward the implementation of on-farm Johne's disease prevention and control strategies. *J Dairy Sci.* 99:9114–9125.
- Roach DR, Bean AGD, Demangel C, France MP, Briscoe H, Britton WJ (2002). TNF regulates chemokine induction essential for cell recruitment, granuloma formation, and clearance of mycobacterial infection. *J Immunol.* 168:4620–7.
- Rosseels V, Huygen K (2008). Vaccination against paratuberculosis. *Expert Rev Vaccines* 7:817–32.
- Rószler T (2015). Understanding the Mysterious M2 Macrophage through Activation Markers and Effector Mechanisms. *Mediators Inflamm.* 2015:816460.
- Roussey JA, Steibel JP, Coussens PM (2014). Regulatory T Cell Activity and Signs of T Cell Unresponsiveness in Bovine Paratuberculosis. *Front Vet Sci.* 1:20.
- Ruiz-Larrañaga O, Manzano C, Iriondo M, Garrido JM, Molina E, Vazquez P, Juste RA, Estonba A (2011). Genetic variation of toll-like receptor genes and infection by *Mycobacterium avium* ssp. *paratuberculosis* in Holstein-Friesian cattle. *J Dairy Sci.* 94:3635–41.
- Sandor M, Weinstock J V, Wynn TA (2003). Granulomas in schistosome and mycobacterial infections: a model of local immune responses. *Trends Immunol.* 24:44–52.
- Santema W, Rutten V, Segers R, Poot J, Hensen S, Heesterbeek H, Koets A (2013). Postexposure subunit vaccination against chronic enteric mycobacterial infection in a natural host. *Infect Immun.* 81:1990–5.
- Santema WJ, Poot J, Segers RPAM, Van den Hoff DJP, Rutten VPMG, Koets AP (2012). Early infection dynamics after experimental challenge with *Mycobacterium avium* subspecies *paratuberculosis* in calves reveal limited calf-to-calf transmission and no impact of Hsp70 vaccination. *Vaccine.* 30:7032–9.

- Saraiva M, O'Garra A (2010). The regulation of IL-10 production by immune cells. *Nat Rev Immunol.* 10:170–81.
- Saunders BM, Cooper AM (2000). Restraining mycobacteria: role of granulomas in mycobacterial infections. *Immunol Cell Biol.* 78:334–41.
- Saunders VF, Eamens GJ, Turner MJ, Jessep TM (2003). Identification of a new RFLP type of *Mycobacterium avium* subsp. *paratuberculosis* in epidemiological tracing of bovine Johne's disease. *Aust Vet J.* 81:564–6.
- Scholzen T, Gerdes J (2000). The Ki-67 protein: from the known and the unknown. *J Cell Physiol* 182:311–22.
- Schönenbrücher H, Abdulmawjood A, Failing K, Bülte M (2008). New triplex real-time PCR assay for detection of *Mycobacterium avium* subsp. *paratuberculosis* in bovine feces. *Appl Environ Microbiol.* 74:2751–8.
- Schwandner R, Dziarski R, Wesche H, Rothe M, Kirschning CJ (1999). Peptidoglycan- and lipoteichoic acid-induced cell activation is mediated by toll-like receptor 2. *J Biol Chem.* 274:17406–9.
- Scott PR, Clarke CJ, King TJ (1995). Serum protein concentrations in clinical cases of ovine paratuberculosis (Johne's disease). *Vet Rec.* 137:173.
- Sechi LA, Scanu AM, Molicotti P, Cannas S, Mura M, Dettori G, Fadda G, Zanetti S (2005). Detection and Isolation of *Mycobacterium avium* subspecies *paratuberculosis* from intestinal mucosal biopsies of patients with and without Crohn's disease in Sardinia. *Am J Gastroenterol.* 100:1529–36.
- Secott TE, Lin TL, Wu CC (2001). Fibronectin attachment protein homologue mediates fibronectin binding by *Mycobacterium avium* subsp. *paratuberculosis*. *Infect Immun.* 69:2075–82.
- Secott TE, Lin TL, Wu CC (2002). Fibronectin attachment protein is necessary for efficient attachment and invasion of epithelial cells by *Mycobacterium avium* subsp. *paratuberculosis*. *Infect Immun.* 70:2670–5.
- Secott TE, Lin TL, Wu CC (2004). *Mycobacterium avium* subsp. *paratuberculosis* fibronectin attachment protein facilitates M-cell targeting and invasion through a fibronectin bridge with host integrins. *Infect Immun.* 72:3724–32.
- Sevilla I x, Singh S V, Garrido JM, Aduriz G, Rodríguez S, Geijo M V, Whittington RJ, Saunders V, Whitlock RH, Juste RA (2005). Molecular typing of *Mycobacterium avium* subspecies *paratuberculosis* strains from different hosts and regions. *Rev Sci Tech.* 24:1061–6.
- Sevilla I, Garrido JM, Geijo M, Juste RA (2007). Pulsed-field gel electrophoresis profile homogeneity of *Mycobacterium avium* subsp. *paratuberculosis* isolates from cattle and heterogeneity of those from sheep and goats. *BMC Microbiol.* 7:18.
- Sevilla IA, Garrido JM, Molina E, Geijo M V, Elguezabal N, Vázquez P, Juste RA (2014). Development and evaluation of a novel multicopy-element-targeting triplex PCR for detection of *Mycobacterium avium* subsp. *paratuberculosis* in feces. *Appl Environ Microbiol.* 80:3757–68.
- Sharma BS, Abo-Ismael MK, Schenkel FS, You Q, Verschoor CP, Pant SD, Karrow NA (2015). Association of TLR4 polymorphisms with *Mycobacterium avium* subspecies *paratuberculosis* infection status in Canadian Holsteins. *Anim Genet.* 46:560–5.
- Shaughnessy LM, Swanson JA (2007). The role of the activated macrophage in clearing *Listeria monocytogenes* infection. *Front Biosci.* 12:2683–92.
- Shu D, Subharat S, Wedlock DN, Luo D, de Lisle GW, Buddle BM (2011). Diverse cytokine profile from mesenteric lymph node cells of cull cows severely affected with Johne's disease. *Clin Vaccine Immunol.* 18:1467–76.

- Sica A, Mantovani A (2012). Macrophage plasticity and polarization: in vivo veritas. *J Clin Invest.* 122:787–95.
- Sigurdardóttir OG, Press CM, Evensen O (2001). Uptake of *Mycobacterium avium* subsp. *paratuberculosis* through the distal small intestinal mucosa in goats: an ultrastructural study. *Vet Pathol.* 38:184–9.
- Sigurdardóttir OG, Press CM, Saxegaard F, Evensen O (1999). Bacterial isolation, immunological response, and histopathological lesions during the early subclinical phase of experimental infection of goat kids with *Mycobacterium avium* subsp. *paratuberculosis*. *Vet Pathol.* 36:542–50.
- Sigurdardóttir OG, Valheim M, Press CM (2004). Establishment of *Mycobacterium avium* subsp. *paratuberculosis* infection in the intestine of ruminants. *Adv Drug Deliv Rev.* 56:819–34.
- Simeone R, Sayes F, Song O, Gröschel MI, Brodin P, Brosch R, Majlessi L (2015). Cytosolic access of *Mycobacterium tuberculosis*: critical impact of phagosomal acidification control and demonstration of occurrence in vivo. *PLoS Pathog.* 11:e1004650.
- Simutis FJ, Cheville NF, Jones DE (2005). Investigation of antigen-specific T-cell responses and subcutaneous granuloma development during experimental sensitization of calves with *Mycobacterium avium* subsp. *paratuberculosis*. *Am J Vet Res.* 66:474–82.
- Singh K, Chandel BS, Chauhan HC, Dadawala A, Singh SV, Singh PK (2013). Efficacy of “indigenous vaccine” using native “Indian bison type” genotype of *Mycobacterium avium* subspecies *paratuberculosis* for the control of clinical Johne’s disease in an organized goat herd. *Vet Res Commun.* 37:109–14.
- Singh PK, Singh SV, Kumar H, Sohal JS, Singh AV (2010). Diagnostic Application of IS900 PCR Using Blood as a Source Sample for the Detection of *Mycobacterium avium* Subspecies *Paratuberculosis* in Early and Subclinical Cases of Caprine *Paratuberculosis*. *Vet Med Int.* 2010:748621.
- Singh S V, Sohal JS, Singh PK, Singh AV (2009). Genotype profiles of *Mycobacterium avium* subspecies *paratuberculosis* isolates recovered from animals, commercial milk, and human beings in North India. *Int J Infect Dis.* 13:e221-7.
- Smeed JA, Watkins CA, Rhind SM, Hopkins J (2007). Differential cytokine gene expression profiles in the three pathological forms of sheep paratuberculosis. *BMC Vet Res.* 3:18.
- Sohal JS, Singh S V, Singh PK, Singh A V (2010). On the evolution of “Indian Bison type” strains of *Mycobacterium avium* subspecies *paratuberculosis*. *Microbiol Res.* 165:163–71.
- Sohal JS, Singh S V, Tyagi P, Subhodh S, Singh PK, Singh A V, Narayanasamy K, Sheoran N, Singh Sandhu K (2008). Immunology of mycobacterial infections: with special reference to *Mycobacterium avium* subspecies *paratuberculosis*. *Immunobiology.* 213:585–98.
- Sonawane GG, Tripathi BN (2016a). Comparative evaluation of diagnostic tests for the detection of *Mycobacterium avium* subsp. *paratuberculosis* in the tissues of sheep affected with distinct pathology of paratuberculosis. *Int J mycobacteriology.* 5 Suppl 1:S88–S89.
- Sonawane GG, Tripathi BN (2016b). Expression of inflammatory cytokine and inducible nitric oxide synthase genes in the small intestine and mesenteric lymph node tissues of pauci- and multibacillary sheep naturally infected with *Mycobacterium avium* ssp. *paratuberculosis*. *Int J mycobacteriology.* 5 Suppl 1:S77–S78.
- Soulas C, Conerly C, Kim W-K, Burdo TH, Alvarez X, Lackner AA, Williams KC (2011). Recently infiltrating MAC387(+) monocytes/macrophages a third macrophage population involved in SIV and HIV encephalitic lesion formation. *Am J Pathol.* 178:2121–35.
- Souza CD (2015) Blocking the mitogen activated protein kinase-p38 pathway is associated with increase expression of nitric oxide synthase and higher production of nitric oxide by bovine

- macrophages infected with *Mycobacterium avium* subsp. *paratuberculosis*. *Vet Immunol Immunopathol.* 164:1–9.
- Stabel JR (2000a). Transitions in immune responses to *Mycobacterium paratuberculosis*. *Vet Microbiol.* 77:465–473.
- Stabel JR (2000b). Cytokine secretion by peripheral blood mononuclear cells from cows infected with *Mycobacterium paratuberculosis*. *Am J Vet Res.* 61:754–60.
- Stabel JR (2006). Host responses to *Mycobacterium avium* subsp. *paratuberculosis*: a complex arsenal. *Anim Heal Res Rev.* 7:61–70.
- Stabel JR, Bannantine JP (2005). Development of a nested PCR method targeting a unique multicopy element, ISMap02, for detection of *Mycobacterium avium* subsp. *paratuberculosis* in fecal samples. *J Clin Microbiol.* 43:4744–50.
- Stabel JR, Bradner L, Robbe-Austerman S, Beitz DC (2014). Clinical disease and stage of lactation influence shedding of *Mycobacterium avium* subspecies *paratuberculosis* into milk and colostrum of naturally infected dairy cows. *J Dairy Sci.* 97:6296–304.
- Stabel JR, Khalifeh MS (2008). Differential expression of CD5 on B lymphocytes in cattle infected with *Mycobacterium avium* subsp. *paratuberculosis*. *Vet Immunol Immunopathol.* 126:211–219.
- Stabel JR, Palmer MV, Harris B, Plattner B, Hostetter J, Robbe-Austerman S (2009). Pathogenesis of *Mycobacterium avium* subsp. *paratuberculosis* in neonatal calves after oral or intraperitoneal experimental infection. *Vet Microbiol.* 136:306–13.
- Stabel JR, Palmer M V, Whitlock RH (2003). Immune responses after oral inoculation of weanling bison or beef calves with a bison or cattle isolate of *Mycobacterium avium* subsp. *paratuberculosis*. *J Wildl Dis.* 39:545–55.
- Stabel JR, Robbe-Austerman S (2011). Early immune markers associated with *Mycobacterium avium* subsp. *paratuberculosis* infection in a neonatal calf model. *Clin Vaccine Immunol.* 18:393–405.
- Stamp JT, Watt JA (1954). Johne's disease in sheep. *J Comp Pathol.* 64:26–40.
- Stefater JA, Ren S, Lang RA, Duffield JS (2011). Metchnikoff's policemen: macrophages in development, homeostasis and regeneration. *Trends Mol Med.* 17:743–52.
- Stehman SM (1996). Paratuberculosis in small ruminants, deer, and South American camelids. *Vet Clin North Am Food Anim Pract.* 12:441–55.
- Stein M, Keshav S, Harris N, Gordon S (1992) Interleukin 4 potently enhances murine macrophage mannose receptor activity: a marker of alternative immunologic macrophage activation. *J Exp Med* 176:287–92.
- Steinman RM, Idoyaga J (2010). Features of the dendritic cell lineage. *Immunol Rev.* 234:5–17.
- Stenger S, Modlin RL (2002). Control of *Mycobacterium tuberculosis* through mammalian Toll-like receptors. *Curr Opin Immunol.* 14:452–7.
- Stevenson K (2015). Genetic diversity of *Mycobacterium avium* subspecies *paratuberculosis* and the influence of strain type on infection and pathogenesis: a review. *Vet Res.* 46:64.
- Stevenson K, Alvarez J, Bakker D, Biet F, de Juan L, Denham S, Dimareli Z, Dohmann K, Gerlach GF, Heron I, Kopecna M, May L, Pavlik I, Sharp JM, Thibault VC, Willemsen P, Zadoks RN, Greig A (2009). Occurrence of *Mycobacterium avium* subspecies *paratuberculosis* across host species and European countries with evidence for transmission between wildlife and domestic ruminants. *BMC Microbiol.* 9:212.
- Stevenson K, Hughes VM, de Juan L, Inglis NF, Wright F, Sharp JM (2002). Molecular characterization of pigmented and nonpigmented isolates of *Mycobacterium avium* subsp. *paratuberculosis*. *J Clin Microbiol.* 40:1798–804.

- Stewart DJ, Vaughan JA, Stiles PL, Noske PJ, Tizard ML V, Prowse SJ, Michalski WP, Butler KL, Jones SL (2007). A long-term bacteriological and immunological study in Holstein-Friesian cattle experimentally infected with *Mycobacterium avium* subsp. *paratuberculosis* and necropsy culture results for Holstein-Friesian cattle, Merino sheep and Angora goats. *Vet Microbiol.* 122:83–96.
- Stewart DJ, Vaughan JA, Stiles PL, Noske PJ, Tizard ML V, Prowse SJ, Michalski WP, Butler KL, Jones SL (2006). A long-term study in Angora goats experimentally infected with *Mycobacterium avium* subsp. *paratuberculosis*: clinical disease, faecal culture and immunological studies. *Vet Microbiol.* 113:13–24.
- Stewart DJ, Vaughan JA, Stiles PL, Noske PJ, Tizard ML V, Prowse SJ, Michalski WP, Butler KL, Jones SL (2004). A long-term study in Merino sheep experimentally infected with *Mycobacterium avium* subsp. *paratuberculosis*: clinical disease, faecal culture and immunological studies. *Vet Microbiol.* 104:165–78.
- Storset AK, Hasvold HJ, Valheim M, Brun-Hansen H, Berntsen G, Whist SK, Djønne B, Press CM, Holstad G, Larsen HJ (2001). Subclinical *paratuberculosis* in goats following experimental infection. An immunological and microbiological study. *Vet Immunol Immunopathol.* 80:271–87.
- Strommenger B, Stevenson K, Gerlach GF (2001). Isolation and diagnostic potential of ISMav2, a novel insertion sequence-like element from *Mycobacterium avium* subspecies *paratuberculosis*. *FEMS Microbiol Lett.* 196:31–7.
- Subharat S, Shu D, de Lisle GW, Buddle BM, Wedlock DN (2012). Altered patterns of toll-like receptor gene expression in cull cows infected with *Mycobacterium avium* subsp. *paratuberculosis*. *Vet Immunol Immunopathol.* 145:471–8.
- Sweeney RW (1996). Transmission of paratuberculosis. *Vet Clin North Am Food Anim Pract.* 12:305–12.
- Sweeney RW (2011). Pathogenesis of paratuberculosis. *Vet Clin North Am Food Anim Pract.* 27:537–46.
- Sweeney RW, Jones DE, Habecker P, Scott P (1998). Interferon-gamma and interleukin 4 gene expression in cows infected with *Mycobacterium paratuberculosis*. *Am J Vet Res.* 59:842–7.
- Sweeney RW, Uzonna J, Whitlock RH, Habecker PL, Chilton P, Scott P (2006). Tissue predilection sites and effect of dose on *Mycobacterium avium* subs. *paratuberculosis* organism recovery in a short-term bovine experimental oral infection model. *Res Vet Sci.* 80:253–9.
- Tabeta K, Georgel P, Janssen E, Du X, Hoebe K, Crozat K, Mudd S, Shamel L, Sovath S, Goode J, Alexopoulou L, Flavell RA, Beutler B (2004). Toll-like receptors 9 and 3 as essential components of innate immune defense against mouse cytomegalovirus infection. *Proc Natl Acad Sci USA.* 101:3516–21.
- Tacke F, Randolph GJ (2006) Migratory fate and differentiation of blood monocyte subsets. *Immunobiology* 211:609–18.
- Tanaka S, Itohara S, Sato M, Taniguchi T, Yokomizo Y (2000). Reduced formation of granulomata in gamma(delta) T cell knockout BALB/c mice inoculated with *Mycobacterium avium* subsp. *paratuberculosis*. *Vet Pathol.* 37:415–21.
- Tanaka S, Sato M, Onitsuka T, Kamata H, Yokomizo Y (2005). Inflammatory cytokine gene expression in different types of granulomatous lesions during asymptomatic stages of bovine paratuberculosis. *Vet Pathol.* 42:579–88.
- Taylor AW (1945). Ovine paratuberculosis (Johne's disease of sheep). *J Comp Pathol.* 55: 41-44.
- Taylor AW (1951). Varieties of *Mycobacterium johnei* isolated from sheep. *J Pathol Bacteriol.* 63:333–6.
- Taylor AW (1953). The experimental infection of cattle with varieties of *Mycobacterium johnei* isolated from sheep. *J Comp Pathol.* 63:368–73.

- Tessema MZ, Koets AP, Rutten VP, Gruys E (2001). How does *Mycobacterium avium* subsp. *paratuberculosis* resist intracellular degradation? *Vet Q.* 23:153–62.
- Thakur A, Aagaard C, Stockmarr A, Andersen P, Jungersen G (2013). Cell-mediated and humoral immune responses after immunization of calves with a recombinant multiantigenic *Mycobacterium avium* subsp. *paratuberculosis* subunit vaccine at different ages. *Clin Vaccine Immunol* 20:551–8.
- Thibault VC, Bryant J, Harris S, Bentley S, Smith DGE, McLuckie J, Parkhill J, Stevenson K. (2012). Genome sequencing to identify phylogenetic diversity and single nucleotide polymorphisms in *Mycobacterium avium* subspecies *paratuberculosis*. In: Nielsen SS, editor. *Proceedings of the Eleventh International Colloquium on Paratuberculosis*. Sydney: International Association for *Paratuberculosis*. 267.
- Thirunavukkarasu S, de Silva K, Begg DJ, Whittington RJ, Plain KM (2015). Macrophage polarization in cattle experimentally exposed to *Mycobacterium avium* subsp. *paratuberculosis*. *Pathog Dis.* 73:ftv085.
- Thorel MF, Krichevsky M L-FV (1990). Numerical taxonomy of mycobactin-dependent mycobacteria, emended description of *Mycobacterium avium*, and description of *Mycobacterium avium* subsp. *avium* subsp. nov., *Mycobacterium avium* subsp. *paratuberculosis* subsp. nov., and *Mycobacterium avium* subsp. s. *Int J Syst Bacteriol.* 40:254–260.
- Thorel MF, Vialard J, Manfroni F, Bernardot J, Ostyn A, Vandevelde J (1992). Experimental paratuberculosis in sheep after intravenous or oral inoculation: pathogenicity and biologic diagnosis. *Ann Rech Vet.* 23:105–15.
- Tomasello G, Bellavia M, Palumbo VD, Gioviale MC, Damiani P, Lo Monte AI (2011). From gut microflora imbalance to mycobacteria infection: is there a relationship with chronic intestinal inflammatory diseases? *Ann Ital Chir.* 82:361–8.
- Tooker BC, Burton JL, Coussens PM (2002) Survival tactics of *M. paratuberculosis* in bovine macrophage cells. *Vet Immunol Immunopathol.* 87:429–37.
- Turenne CY, Alexander DC (2010). *Mycobacterium avium* Complex. *Paratuberculosis: Organism, Disease, Control.*, Ed.: Behr MA, Collins DM, CAB International, Reino Unido. 60-73.
- Turenne CY, Wallace R, Behr MA (2007). *Mycobacterium avium* in the postgenomic era. *Clin Microbiol Rev.* 20:205–29.
- Uematsu S, Akira S (2006). Toll-like receptors and innate immunity. *J Mol Med (Berl).* 84:712–25.
- Uzonna JE, Chilton P, Whitlock RH, Habecker PL, Scott P, Sweeney RW (2003). Efficacy of commercial and field-strain *Mycobacterium paratuberculosis* vaccinations with recombinant IL-12 in a bovine experimental infection model. *Vaccine.* 21:3101–9.
- Valentin-Weigand P, Goethe R (1999). Pathogenesis of *Mycobacterium avium* subspecies *paratuberculosis* infections in ruminants: still more questions than answers. *Microbes Infect.* 1:1121–7.
- Valheim M, Sigurdardóttir OG, Storset AK, Aune LG, Press CM (2004). Characterization of macrophages and occurrence of T cells in intestinal lesions of subclinical paratuberculosis in goats. *J Comp Pathol.* 131:221–32.
- Valheim M, Storset AK, Aleksersen M, Brun-Hansen H, C McL Press (2002). Lesions in subclinical paratuberculosis of goats are associated with persistent gut-associated lymphoid tissue. *J Comp Pathol.* 127:194–202.
- van Kooten HCJ, Mackintosh CG, Koets AP (2006). Intra-uterine transmission of paratuberculosis (Johne's disease) in farmed red deer. *N Z Vet J.* 54:16–20.

- Vasselon T, Detmers PA (2002). Toll receptors: a central element in innate immune responses. *Infect Immun.* 70:1033–41.
- Vaughan JA, Lenghaus C, Stewart DJ, Tizard ML, Michalski WP (2005). Development of a Johne's disease infection model in laboratory rabbits following oral administration of *Mycobacterium avium* subspecies *paratuberculosis*. *Vet Microbiol.* 105:207–13.
- Vázquez P, Garrido JM, Juste RA (2013). Specific antibody and interferon-gamma responses associated with immunopathological forms of bovine paratuberculosis in slaughtered Friesian cattle. *PLoS One.* 8:e64568.
- Vázquez P (2014). Latencia y patencia en la paratuberculosis bovina, relación con marcadores genéticos y aspectos de salud pública y control. Tesis Doctoral. Universidad de Zaragoza.
- Verdugo C, Pleydell E, Price-Carter M, Prattley D, Collins D, de Lisle G, Vogue H, Wilson P, Heuer C (2014). Molecular epidemiology of *Mycobacterium avium* subsp. *paratuberculosis* isolated from sheep, cattle and deer on New Zealand pastoral farms. *Prev Vet Med.* 117:436–46.
- Verin R, Perroni M, Rossi G, De Grossi L, Botta R, De Sanctis B, Rocca S, Cubeddu T, Crosby-Durrani H, Taccini E (2016). Paratuberculosis in sheep: Histochemical, immunohistochemical and in situ hybridization evidence of in utero and milk transmission. *Res Vet Sci.* 106:173–9.
- Verna AE, Garcia-Pariente C, Muñoz M, Moreno O, García-Marin JF, Romano MI, Paolicchi F, Pérez V (2007). Variation in the immuno-pathological responses of lambs after experimental infection with different strains of *Mycobacterium avium* subsp. *paratuberculosis*. *Zoonoses Public Health.* 54:243–52.
- Viale MN, Echeverria-Valencia G, Romasanta P, Mon ML, Fernandez M, Malchiodi E, Romano MI, Gioffré AK, Santangelo M de la P (2014). Description of a novel adhesin of *Mycobacterium avium* subsp. *paratuberculosis*. *Biomed Res Int.* 729618.
- Vir Singh S, Dhama K, Chaubey KK, Kumar N, Singh PK, Sohal JS, Gupta S, Vir Singh A, Verma AK, Tiwari R, Mahima, Chakraborty S, Deb R (2013). Impact of host genetics on susceptibility and resistance to *Mycobacterium avium* subspecies *Paratuberculosis* infection in domestic ruminants. *Pakistan J Biol Sci PJSB.* 16:251–66.
- Vremec D, O'Keefe M, Hochrein H, Fuchsberger M, Caminschi I, Lahoud M, Shortman K (2007). Production of interferons by dendritic cells, plasmacytoid cells, natural killer cells, and interferon-producing killer dendritic cells. *Blood.* 109:1165–73.
- Waters WR, Miller JM, Palmer M V, Stabel JR, Jones DE, Koistinen KA, Steadham EM, Hamilton MJ, Davis WC, Bannantine JP (2003). Early induction of humoral and cellular immune responses during experimental *Mycobacterium avium* subsp. *paratuberculosis* infection of calves. *Infect Immun.* 71:5130–8.
- Waters WR, Stabel JR, Sacco RE, Harp JA, Pesch BA, Wannemuehler MJ (1999). Antigen-specific B-cell unresponsiveness induced by chronic *Mycobacterium avium* subsp. *paratuberculosis* infection of cattle. *Infect Immun.* 67:1593–8.
- Weber MF, Verhoeff J, van Schaik G, van Maanen C (2009). Evaluation of Ziehl-Neelsen stained faecal smear and ELISA as tools for surveillance of clinical *paratuberculosis* in cattle in the Netherlands. *Prev Vet Med.* 92:256–66.
- Weiss DJ, Evanson OA, Deng M, Abrahamsen MS (2004). Gene expression and antimicrobial activity of bovine macrophages in response to *Mycobacterium avium* subsp. *paratuberculosis*. *Vet Pathol.* 41:326–37.
- Weiss DJ, Evanson OA, McClenahan DJ, Abrahamsen MS, Walcheck BK (2001). Regulation of expression of major histocompatibility antigens by bovine macrophages infected with *M. avium* subsp. *paratuberculosis* or *Mycobacterium avium* subsp. *avium*. *Infect Immun.* 69:1002–8.

- Weiss DJ, Evanson OA, Souza CD (2006). Mucosal immune response in cattle with subclinical Johne's disease. *Vet Pathol.* 43:127–35.
- Weiss DJ, Souza CD (2008). Review paper: modulation of mononuclear phagocyte function by *Mycobacterium avium* subsp. *paratuberculosis*. *Vet Pathol* 45:829–34.
- Wherry EJ (2011). T cell exhaustion. *Nat Immunol.* 12:492–9.
- Whitlock RH, Buergelt C (1996). Preclinical and clinical manifestations of paratuberculosis (including pathology). *Vet Clin North Am Food Anim Pract.* 12:345–56.
- Whittington RJ, Begg DJ, de Silva K, Plain KM, Purdie AC (2012). Comparative immunological and microbiological aspects of paratuberculosis as a model mycobacterial infection. *Vet Immunol Immunopathol.* 148:29–47.
- Whittington RJ, Fell S, Walker D, McAllister S, Marsh I, Sergeant E, Taragel CA, Marshall DJ, Links IJ (2000). Use of pooled fecal culture for sensitive and economic detection of *Mycobacterium avium* subsp. *paratuberculosis* infection in flocks of sheep. *J Clin Microbiol.* 38:2550–6.
- Whittington RJ, Marsh I, McAllister S, Turner MJ, Marshall DJ, Fraser CA (1999). Evaluation of modified BACTEC 12B radiometric medium and solid media for culture of *Mycobacterium avium* subsp. *paratuberculosis* from sheep. *J Clin Microbiol.* 37:1077–83.
- Whittington RJ, Marsh IB, Saunders V, Grant IR, Juste R, Sevilla IA, Manning EJB, Whitlock RH (2011). Culture phenotypes of genomically and geographically diverse *Mycobacterium avium* subsp. *paratuberculosis* isolates from different hosts. *J Clin Microbiol.* 49:1822–30.
- Whittington RJ, Marsh IB, Whitlock RH (2001a). Typing of IS 1311 polymorphisms confirms that bison (*Bison bison*) with *paratuberculosis* in Montana are infected with a strain of *Mycobacterium avium* subsp. *paratuberculosis* distinct from that occurring in cattle and other domesticated livestock. *Mol Cell Probes.* 15:139–45.
- Whittington RJ, Sergeant ES (2001). Progress towards understanding the spread, detection and control of *Mycobacterium avium* subsp *paratuberculosis* in animal populations. *Aust Vet J.* 79:267–78.
- Whittington RJ, Taragel CA, Ottaway S, Marsh I, Seaman J, Fridriksdottir V (2001b). Molecular epidemiological confirmation and circumstances of occurrence of sheep (S) strains of *Mycobacterium avium* subsp. *paratuberculosis* in cases of *paratuberculosis* in cattle in Australia and sheep and cattle in Iceland. *Vet Microbiol.* 79:311–22.
- Whittington RJ, Whittington A-M, Waldron A, Begg DJ, de Silva K, Purdie AC, Plain KM (2013). Development and validation of a liquid medium (M7H9C) for routine culture of *Mycobacterium avium* subsp. *paratuberculosis* to replace modified Bactec 12B medium. *J Clin Microbiol.* 51:3993–4000.
- Windsor PA (2015). Paratuberculosis in sheep and goats. *Vet Microbiol.* 181:161–9.
- Windsor PA, Eppleston J, Dhand NK, Whittington RJ (2014). Effectiveness of Gudair™ vaccine for the control of ovine Johne's disease in flocks vaccinating for at least 5 years. *Aust Vet J.* 92:263–8.
- Woo SR, Czuprynski CJ (2008). Tactics of *Mycobacterium avium* subsp. *paratuberculosis* for intracellular survival in mononuclear phagocytes. *J Vet Sci.* 9:1–8.
- Wu C, Schmoller SK, Shin SJ, Talaat AM (2007). Defining the stressome of *Mycobacterium avium* subsp. *paratuberculosis* in vitro and in naturally infected cows. *J Bacteriol.* 189:7877–86.
- Yadav D, Singh S V, Singh A V, Sevilla I, Juste RA, Singh PK, Sohal JS (2008). Pathogenic "Bison-type" *Mycobacterium avium* subspecies *paratuberculosis* genotype characterized from riverine buffalo (*Bubalus bubalis*) in North India. *Comp Immunol Microbiol Infect Dis.* 31:373–87.

- Zhao B, Collins MT, Czuprynski CJ (1997). Effects of gamma interferon and nitric oxide on the interaction of *Mycobacterium avium* subsp. *paratuberculosis* with bovine monocytes. *Infect Immun.* 65:1761–6.
- Zheng H, Lu L, Wang B, Pu S, Zhang X, Zhu G, Shi W, Zhang L, Wang H, Wang S, Zhao G, Zhang Y (2008). Genetic basis of virulence attenuation revealed by comparative genomic analysis of *Mycobacterium tuberculosis* strain H37Ra versus H37Rv. *PLoS One.* 3:e2375.
- Zimmer K, Dräger KG, Klawonn W, Hess RG (1999). Contribution to the diagnosis of Johne's disease in cattle. Comparative studies on the validity of Ziehl-Neelsen staining, faecal culture and a commercially available DNA-Probe test in detecting *Mycobacterium paratuberculosis* in faeces from cattle. *Zentralbl Veterinarmed B.* 46:137–40.
- Zuñiga J, Torres-García D, Santos-Mendoza T, Rodriguez-Reyna TS, Granados J, Yunis EJ (2012). Cellular and humoral mechanisms involved in the control of tuberculosis. *Clin Dev Immunol.* 2012:193923.
- Zur Lage S, Goethe R, Darji A, Valentin-Weigand P, Weiss S (2003). Activation of macrophages and interference with CD4+ T-cell stimulation by *Mycobacterium avium* subspecies *paratuberculosis* and *Mycobacterium avium* subspecies *avium*. *Immunology.* 108:62–9.

9. ANEXO: PUBLICACIONES

APPENDIX: PUBLICATIONS

RESEARCH

Open Access

Experimental infection of lambs with C and S-type strains of *Mycobacterium avium* subspecies *paratuberculosis*: immunological and pathological findings

Miguel Fernández¹, Julio Benavides¹, Iker A Sevilla², Miguel Fuertes¹, Pablo Castaño¹, Laetitia Delgado¹, J Francisco García Marín¹, Joseba M Garrido², M Carmen Ferreras¹ and Valentín Pérez^{1*}

Abstract

The two main genotypes of recognized isolates of *Mycobacterium avium* subsp. *paratuberculosis* (*Map*) are cattle (C) and sheep (S) strains. An experimental infection was conducted to establish the effect of *Map* strain on the pathogenesis of ovine paratuberculosis. Twenty-four out of thirty 1.5-month-old Assaf lambs were divided into 4 groups of 6 and infected orally with three low passage field isolates, two of S- (22G and the pigmented Ovicap49) and one of C- (764) type, and the reference K-10 strain (C type). The remaining six animals were unchallenged controls. Animals were euthanized at 150 and 390 days post-infection (dpi). Throughout the experiment, the peripheral immune response was assessed and histological and molecular (PCR) studies were conducted on samples of intestine and related lymphoid tissue. Specific antibody and IFN- γ production was significantly higher in animals infected with the C strains, while no consistent IFN- γ responses were observed in the S-type strain infected groups. A positive intradermal skin test response was detected in all infected groups. Lambs infected with S-type strains had granulomatous lesions restricted to the lymphoid tissue with no differences in the lesion intensity over time. In both C-type strain groups, lesions were more severe at 150 dpi while at 390 dpi lesions, characterized by well-demarcated granulomas with fibrosis, decreased in severity. Only infected lambs were positive to PCR. These results suggest that the strain of *Map* has a strong influence over the immune and pathological responses developed by the host. Lesions induced by C-type strains in lambs show a regressive character and tend to decrease as the infection progresses.

Introduction

Paratuberculosis or Johne's disease, caused by *Mycobacterium avium* subspecies *paratuberculosis* (*Map*), is a chronic infection of domestic and wild ruminants characterized by granulomatous enteritis and lymphadenitis. It occurs worldwide and causes high economic losses to domestic livestock. Clinical disease results in a progressive loss of weight, usually with chronic diarrhoea, and eventual death of the infected animals.

Pathogenesis of paratuberculosis is still poorly understood. It is assumed that animals become infected early in life and can develop a variety of responses: resistance to infection, an asymptomatic status in which animals remain subclinically infected for life, or clinical disease [1-3]. Different pathological responses have also been detected among infected animals, both in natural and experimental cases depending on the intensity, location, cellular types and number of acid-fast bacilli present in the granulomas [4-6]. Briefly, these lesions are divided into *focal* forms, characterized by the presence of small granulomas restricted to the Peyer's patches; *multifocal* lesions with granulomas present in the intestinal mucosa regardless of its association with lymphoid tissue, and

* Correspondence: vperp@unileon.es

¹Departamento de Sanidad Animal, Instituto de Ganadería de Montaña (CSIC-ULE), Facultad de Veterinaria, Universidad de León, Campus de Vegazana s/n, León 24071, Spain

Full list of author information is available at the end of the article



diffuse forms, related to clinical signs, characterized by a widespread and diffuse granulomatous enteritis.

It has been suggested that these differences could be related to the immune response mounted by the host in such a way that a great number of asymptomatic animals with focal or multifocal lesions show an intense cell-mediated immune response, while the detection of the humoral immunity would be related to clinical disease [7-9]. There is also evidence suggesting that these variations in pathogenesis could be due to differences in the microorganism [10-12].

The existence of distinct strains of *Map* based on phenotypic differences has been recognised for some time [13]. Recently the use of IS900 restriction fragment length polymorphism (RFLP) and IS1311 PCR-restriction enzyme analysis (PCR-REA) methods, has led to the classification of *Map* strains into two main genotypes: sheep or ovine isolates (also called "S-type" or "type-I and III") and cattle or bovine isolates (also called "C-type" or "type II") [14-16]. Although not common, cross-species infections have been documented [17-19]. Besides the genotypic distinctions between C and S strains of *Map*, phenotypic differences have been found in *in vitro* experiments, where infected macrophages exhibit different inflammatory responses depending on the type of isolate [11,20,21]. Variations in the peripheral immune response have also been reported after the infection of sheep with C and S strains of *Map* [10]. Furthermore, in contrast to C-type isolates, the growth of S-type *Map* strains in culture media is slower and more fastidious [19,22]. The existence of pigmented isolates among S-type strains is also well documented [13,16].

Concerning the role of *Map* strains in the development of the different pathological responses, a previous study [23] showed that S-type strains cause diffuse and more severe lesions than C strains in experimentally infected lambs. However, in that study, the ovine *Map* inoculum was an intestinal mucosa homogenate from a field case of paratuberculosis and no molecularly typified strains were employed. Furthermore, the presence of lesions was only assessed at 150 days post-infection (dpi).

The aim of this study was to evaluate the influence of the different strains of *Map* on the pathogenesis of paratuberculosis, through the evaluation of lesion development and peripheral immune responses in lambs

experimentally infected with molecularly typed C and S strains obtained from pure cultures.

Materials and methods

Inocula preparation

The strains used for the challenge were the reference strain of *Map* K-10 (ATCC® BAA-968™) and three low-passage field isolates maintained as glycerol stocks at -80 °C obtained from different species and samples. The latter strains represent the most widespread C and S genotypes found in Spain as previously reported [24]. More detailed information on the strains is shown in Table 1. All strains were propagated in Middlebrook 7H9 broth [25] supplemented with OADC (oleic acid, albumin, dextrose, catalase) enrichment (Becton Dickinson and Company, MD, USA), Tween 80 (Panreac Quimica SA, Barcelona, Spain), glycerol and mycobactin J (Allied Monitor, Inc., Fayette, MO, USA). After 4-5 weeks at 37 °C, cultures were harvested by centrifugation at 2800 × g for 15 min. Bacterial pellets were washed twice in phosphate buffered saline (PBS), resuspended in PBS and the presence of clumps minimized by making the liquid flow up and down through a fine needle (26G3/8) several times. Turbidity (McFarland units) of suspensions was measured using a Densimat (bioMérieux, Marcy l'Etoile, France). Expected cell concentration was estimated considering one McFarland unit as 10⁸ cells/mL according to a previous study [26] but taking into account that this equivalence could be one log lower as reported elsewhere [25]. Suspensions were adjusted to 2 × 10⁹ cells/mL with PBS and each challenge whole-dose prepared using one mL of these suspensions as explained below.

Ten-fold serial dilutions were prepared and plated onto agar-solidified 7H9 with OADC, glycerol and mycobactin J in quadruplicate to assess the number of colony forming units (CFU) per mL in the inocula. Since bacteria were administered to animals in several aliquots and on separate days during 2 weeks, the unused aliquots of diluted inocula were kept at 4 °C until required. In order to assess any potential loss of viability during this time, the plating procedure was repeated the last challenge day when all aliquots were administered. The material used to assess the potential reduction in CFU/mL numbers was a separate aliquot prepared and kept under the same conditions as those of the administered doses.

Table 1 Origin of the strains used in the infection

Strain ID	Host	Breed	Isolated from	Location	IS1311 PCR-REA	<i>Sna</i> BI- <i>Spe</i> I PFGE
22G	Sheep	Latxa	intestinal tissue	Gipuzkoa, Spain	S	69-50 Type III
Ovicap49 ^a	Sheep	Latxa	intestinal tissue	Navarra, Spain	S	57-57 Type III
764	Cattle	Holstein	feces	Bizkaia, Spain	C	2-1 Type II
K-10	Cattle		feces	USA	C	1-1 Type II

^aPigmented strain.

Experimental animals

A total of thirty 1.5-month-old lambs of the Assaf breed were used in this study. They were randomly selected from a flock in which no clinical cases of paratuberculosis had been reported in the last 5 years. Antibody ELISA and IFN- γ release test was performed in all the dams of the lambs, and all were negative to both assays.

After a period of adaptation in the experimental facilities of the "Instituto de Ganadería de Montaña CSIC-ULE", the lambs were allocated in separate pens and randomly divided into the following five groups, each composed of six lambs, according to the strain of *Map* inoculated: 22G and Ovicap49 sheep strains; 764 and K-10 cattle strains and a fifth group of uninfected control animals challenged with saline solution. All the animals followed a diet based on fed grass hay *ad libitum* and a conventional compound feed appropriate for each age.

Experimental design

The experimental procedures carried out in this study were performed in accordance with Spanish Royal Decree 1201/2005 for the protection of animals used for experimental and other scientific purposes, and were approved by the "Instituto de Ganadería de Montaña CSIC-ULE" Animal Ethics Committee.

Each experimentally infected lamb was orally inoculated using an automatic syringe with a total amount of 2×10^9 mycobacteria diluted in 40 mL of PBS that was divided into four doses of 10 mL, administered at 3-day intervals.

On day 150 after infection, two lambs from each group were humanely culled by the intravenous injection of a veterinary euthanasia drug (T61[®], Intervet, Salamanca, Spain), followed by exsanguination. The remaining animals were killed at 390 dpi.

Blood samples were collected from the jugular vein into 10 mL evacuated tubes (Venoject[®], Terumo Europe N.V., Leuven, Belgium) containing lithium heparin or without anticoagulant for IFN- γ and antibody (Ab) determination studies respectively. Blood samples were taken at monthly intervals from day 0 up to 390 dpi.

Cell mediated immune response determination

Interferon- γ (IFN- γ) release assay (IGRA)

For the IFN- γ test, whole blood samples taken in heparinized tubes were used. They were always processed within 3 h from the time of collection. Two separate aliquots of 1.5 mL blood were mixed with either 100 μ L of sterile PBS (negative control) or an avian purified protein derivative (PPD) Ag (CZ Veterinaria, Porriño, Spain) at a final concentration of 30 μ g/mL. Whole-blood cultures were incubated for 20 h at 37 °C in a humidified atmosphere. The tubes were then centrifuged

and plasma supernatant was removed and frozen at -20 °C until required. Plasma samples were then assayed in duplicate for the IFN- γ determination using a commercial immunoassay kit ("BOVIGAM[®] *Mycobacterium bovis* Gamma Interferon Test Kit for cattle, Prionics AG, Switzerland) that has been widely used for testing ovine samples [9,10,23,27], according to the manufacturer's instructions. For avoiding inter-plate variations, all the O.D. values were adjusted by dividing the sample O.D. minus the negative control O.D., from each plate. Once the raw values were standardized, the results were expressed as a quotient between the mean O.D. of the avian PPD-stimulated plasma and the mean O.D. of the sample plasma incubated with PBS. An animal was considered as positive when the quotient was higher than 2 [9,27].

Single intradermal skin test (IDT)

One month before sampling (120 and 360 dpi), all the lambs were injected intradermally in the skin fold of the tail with 0.1 mL of avian PPD (CZ Veterinaria, Porriño, Spain) at a 0.5 mg/mL concentration. Skin-fold thickness was measured at the injection site with a calliper before injection and 72 h later. The results were expressed as the increase in millimeter of skin thickness. When used for diagnostic purposes, an animal was considered as positive when the increase in skin thickness was \geq than 2 mm [9].

Humoral immune response determination by indirect ELISA (Ab ELISA)

Blood samples without anticoagulant were allowed to clot and the serum was stored at -20 °C until required. The production of antibodies (Ab) against *Map* was determined by an indirect ELISA, using a protoplasmic antigen of *Map* (PPA-3; Allied Monitor Lab. Inc., Fayette, USA) and horseradish peroxidase conjugate protein G as a secondary Ab (Biorad, Hercules, USA). The technique was performed as previously described [23]. The absorbance values were measured spectrophotometrically at 450 nm using an ELX800 ELISA reader (Bio-Tek Instruments, Winooski, USA). The results were expressed as a quotient between the mean O.D. of each sample sera and the mean O.D. of the positive control serum in each plate. An animal is considered positive when this quotient is higher than 0.9 [8].

Pathological studies

Complete necropsies were performed in all the animals. Gross examination was carried out, with special attention to the gut and related lymph nodes. Samples from the ileocecal valve (ICV), ileum (IL) (three 5-cm samples, taken 20, 40 and 60 cm from the ileocecal valve), jejunum (JJ) and jejunal Peyer's patches (JPP) (at least 3 patches from each of the proximal, medium and distal

zones), the caudal mesenteric lymph node (MLN), one jejunal lymph node (JLN) and ileocecal lymph nodes (ICLN) were taken for histopathological examination. All the tissues were fixed in 10% neutral buffered formalin, dehydrated through a graded alcohol series before being embedded in paraffin wax. Sections 4 µm thick were stained with haematoxylin and eosin (HE), Masson's Trichrome to stain connective tissue and by the Ziehl-Neelsen (ZN) technique for acid-fast bacilli (AFB) detection.

Representative granulomatous lesions found in lambs from all the experimental groups were assessed immunohistochemically for the presence of *Map* or its antigens, using an EnVision + HRP visualization kit (Dako North America, Carpinteria, USA). The sections were incubated with a specific rabbit anti-*Map* serum at a dilution of 1/9000, as described elsewhere [28].

All the lesions consistent with *Map* infection observed in the digestive tract were classified following the guidelines previously proposed [5,28] for paratuberculosis lesions in the ovine species, according to the presence and location of granulomas in the different intestinal lymphoid tissue compartments.

After the conventional histopathological examination, the number of granulomas per tissue section was quantified in the following samples: ICV, 3 samples of the IL, JJ and JPP (proximal, middle and distal), MLN, JLN and ICLN. Three tissue sections were randomly selected from each intestinal site and 2 tissue sections from each lymph node, so that a total of 30 intestinal and 6 lymph node tissue sections were analysed from each animal. Sections were assessed blind and the mean number of granulomas per tissue section in each site was recorded by the same observer (MF), distinguishing those granulomas located in the lymphoid tissue from those in the associated lamina propria (LP) or in the mucosa not related to lymphoid tissue.

Nested PCR

The detection of *Map* DNA was assessed using a nested PCR method that was performed from paraffin-embedded tissues. In total, 10 µm of ICV, middle JPP and JLN tissue sections adjacent to those used for the ZN and immunohistochemical studies were cut twice, and DNA was isolated using Speedtools Tissue DNA extraction kit according to the manufacturer's instructions (Biotools® B&M Labs., Madrid, Spain). The nested PCR was carried out as previously described [27] using primers to detect the presence of *Map*-specific IS900 DNA.

Statistical analysis

Data on IFN-γ and Ab production as well as on granuloma count were subjected to analysis of variance using the general linear model procedure (GLM) of the SAS statistical package (version 9.1; SAS Institute, Cary, NC, USA) for the evaluation of treatment, time of killing and

lesion location main effects and interactions. The results of the O.D. indexes obtained in the IGRA, Ab ELISA tests and the tissue granuloma count figures were logarithmically transformed to submit them to normal distribution-based tests of significance. Thus, differences among the experimental groups at each time of sampling or killing were evaluated using the Student's *t*-test for pair-wise comparisons with the Tukey-Kramer correction for multiple comparisons, at the 95% significance level. The results of the IDT among the experimental groups at 120 and 360 dpi, and the PCR-positive frequencies were compared and tested for significance by chi-squared analysis.

Results

One animal from the K-10 group died at 30 dpi, during the course of the experiment from causes unrelated to Johne's disease (bacterial pneumonia) and was excluded from this study.

Assessment of the colony forming units (CFU)

The number of CFU obtained after the culture of the first and fourth (shown in Figure 1) aliquots of the different inocula gave similar results. As shown in Figure 1, the difference between the expected number of cells/mL as assessed by McFarland readings and CFU/mL counts as assessed by plating serial dilutions of inocula was lower than one logarithm in all cases except for the Ovicap49 strain. In this case the mean value for CFU/mL counts was only 3×10^7 (standard deviation = 1.41×10^7).

IFN-γ test (IGRA)

Figure 2 shows the IFN-γ production in the different experimental groups. No significant differences were observed between the groups infected with an S-type strain and the control group, although sporadically some of the infected lambs showed an index value considered as positive (> 2). However, in both experimental groups challenged with the C-type strains, the IFN-γ production was significantly higher than in the control or S strains-infected groups ($P < 0.05$) between 120 and 330 dpi. The highest values were mainly reached between 240 and 330 dpi, with significant differences ($P < 0.05$) between 764 and K-10 groups. At 120 dpi (Figure 2), both C-type strain-infected groups showed the earliest significant increase, that was also higher in the 764 group ($P < 0.05$).

Intradermal skin test (IDT)

All the infected groups showed a significant increase in skin thickness ($P < 0.05$) compared to the control group, both at 120 and 360 dpi (Figure 3), except for lambs infected with the 22G strain at 360 dpi. No significant differences in this response were detected among the different groups either at 120 or 350 dpi.

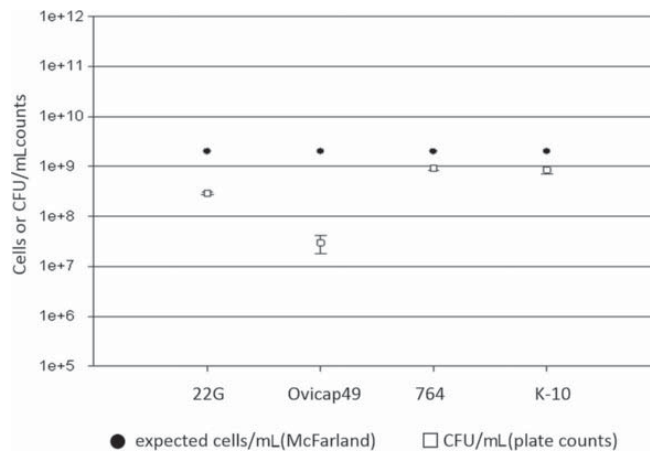


Figure 1 Assessment of the bacterial load of the inocula. Differences between the bacterial load of inocula used for the challenge of animals as assessed by optical density (McFarland) and CFU counts (plate colony counting).

Indirect ELISA

The Ab production in the different experimental groups throughout the experiment is shown in Figure 4. No significant differences were observed between the groups, except for a significant increase ($P < 0.05$) between 210 and 330 dpi in the Ab levels of the animals from the 764 group.

Pathological findings

Gross lesions

In the two lambs euthanized at 150 dpi from group 764, one and two areas of thickening of the intestinal mucosa, between 1–2.5 cm long, were observed respectively

in the middle part of the jejunum (Figure 5a). No other gross changes related to paratuberculosis were seen in any of the rest of the lambs regardless of the time of sampling.

Microscopic lesions

Granulomatous lesions consistent with *Map* infection were found in the tissue sections from all infected lambs euthanized at 150 dpi, regardless of the group, and in all but three animals (one from 22G, Ovicap49 and K-10 group each respectively) examined at 390 dpi. However, the type of lesion varied between the S and C-type *Map*

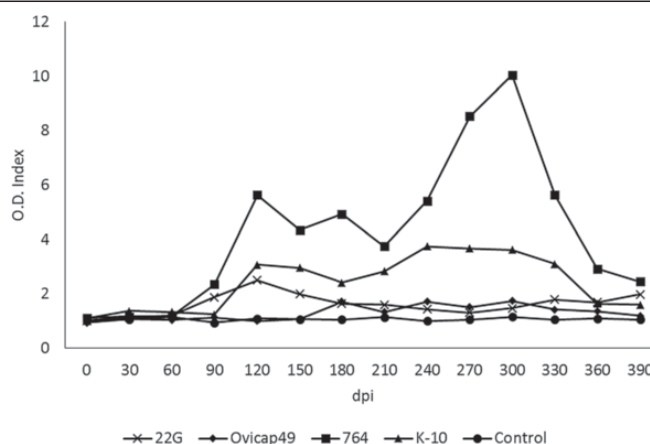


Figure 2 Kinetics of the specific IFN- γ release by whole blood stimulated with avian PPD in the five experimental groups. The results are expressed as an index obtained after dividing the mean O.D. of each sample stimulated with avian PPD by the mean O.D. of the same sample incubated with PBS. From 0 to 150 dpi, each group was formed by 6 lambs, while from 180 to 390 dpi they were composed of 4 animals (except group K-10, formed by 5 and 3 respectively). dpi: days post infection.

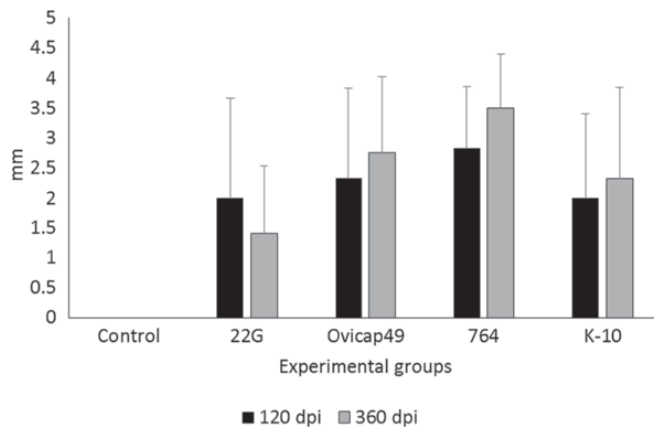


Figure 3 Response to the intradermal skin test (IDT). The results are expressed as the skin-fold thickness increase (in mm) after intradermal injection of avian PPD, at 120 and 360 dpi in the five experimental groups. Error bars: standard deviation.

strain infected groups. To categorize each animal, the final classification was always based on its more severe intestinal granulomatous lesion (Table 2).

Lambs from S strain infected groups (both 22G and Ovicap49) showed lesions that were categorized as *focal*. They were formed by small, well-defined granulomas composed of groups of 20–50 macrophages with a large pale cytoplasm and large nuclei with a few lymphocytes scattered among them (Figure 5b). These granulomas were found exclusively in the interfollicular area of the intestinal lymphoid tissue, either in the ileocecal valve or the jejunal Peyer's patches (Figure 5b). The presence of these granulomas, due to their small size, did not alter the normal structure of the Peyer's patches. These focal lesions appeared in the four lambs euthanized at 150

dpi, and in 6 out of the 8 (75%) lambs analysed at 390 dpi. The remaining two animals (one from each experimental group) did not show lesions related to *Map* infection.

Differences in the lesion type between the groups infected with the S and C strains were observed. At 150 dpi, among lambs from the K-10 group, one animal had lesions categorized as *multifocal a*, composed of more numerous granulomas than those seen in the focal forms. In addition to the granulomas present in the interfollicular areas of the Peyer's patches, small and well-defined granulomatous lesions were also detected in the lamina propria (LP) related to the intestinal lymphoid tissue. The morphology of the villi was not substantially modified. In the remaining lamb from the

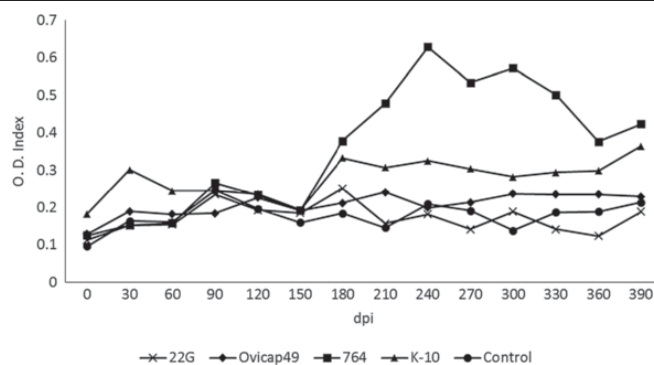


Figure 4 Kinetics of the antibody production of the five experimental groups, assessed by indirect ELISA. The results are expressed as an index obtained after dividing the mean O.D. of each sample by the mean O.D. of the positive control from each plate. From 0 to 150 dpi, each group was formed by 6 lambs, while from 180 to 390 dpi they were composed of 4 animals (except group K-10, formed by 5 and 3 respectively). dpi: days post infection.

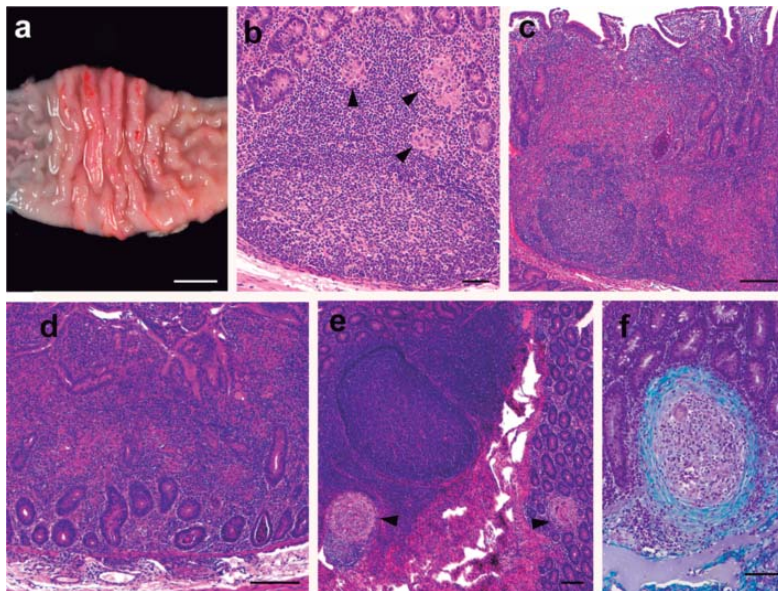


Figure 5 Pathological findings in the experimentally infected lambs. **(a)** Focal thickening of the jejunal mucosa in a lamb from the 764 group euthanized at 150 dpi. Bar = 1 cm. **(b)** Focal lesion composed of a group of macrophages (arrowheads) seen in the interfollicular area of the JPP, observed in a lamb from group Ovicap49 culled at 390 dpi. HE. Bar = 50 μ m. **(c)** Severe granulomatous infiltrate invading and modifying the lymphoid tissue architecture, that is also present in the related LP. JPP. Lamb from K-10 group with a *multifocal b* lesion, culled at 150 dpi. HE. Bar = 500 μ m. **(d)** Diffuse lesion characterized by the thickening of the jejunal lamina propria with enlargement of the intestinal villi due to the presence of an infiltrate formed by several poorly-defined granulomas surrounded by numerous lymphocytes. Jejunum. Lamb from 764 group euthanized at 150 dpi. HE. Bar = 350 μ m. **(e)** Two small and very well demarcated granulomas (arrowheads) present in the lymphoid tissue and adjacent lamina propria (*multifocal a* lesion) that do not significantly alter intestinal morphology. JPP. Animal from 764 group culled at 390 dpi. HE. Bar = 200 μ m. **(f)** Detail of a "regressive" type granuloma, with a thick fibrous capsule surrounding the macrophages and giant cells, seen in the jejunal lamina propria in a lamb from 764 group culled at 390 dpi. Masson's Trichrome. Bar = 70 μ m.

K-10 group, the lesion was classified as *multifocal b*. In that animal, granulomatous changes were more severe in the lymphoid tissue and related LP (Figure 5c), but were also extended to the LP not associated with the lymphoid tissue. At this location, granulomas were seen between the intestinal glands and caused a focal thickening of the LP, without a clear disruption of the normal structure. In both lambs from group 764 culled at 150 dpi, lesions were classified as *diffuse*. They were composed of large numbers of granulomas that coalesced and invaded the complete structure of the Peyer's patches, causing a clear modification of their normal architecture. Poorly demarcated granulomatous lesions were also found in the LP related and non-related to the lymphoid tissue (Figure 5d). In areas of the jejunum, the intestinal mucosa was markedly thickened due to the presence of granulomas surrounded by a large number of lymphocytes (Figure 5d). The presence of this infiltrate caused the enlargement and fusion of the intestinal villi and the separation of the intestinal glands. Occasionally cell debris was observed in the lumen of the glands (Figure 5c, d).

A constant feature in both groups of lambs infected with the C-type strains, in contrast to those infected with the S strains, regardless of the lesion type, was the occasional finding of multinucleated Langhans giant cells among the cells forming the granulomas, and the sporadic presence of central areas of caseous necrosis exclusively in some of the granulomas located in the lymphoid tissue, especially in the largest ones.

Among the three lambs from the K-10 group euthanized at 390 dpi, one of them had *focal* lesions, another had a *multifocal a* type lesion and there were no lesions in the last. In lambs from group 764, no diffuse lesions were observed at 390 dpi, in contrast to the pathological findings at 150 dpi. One animal had a *multifocal b* lesion, two had *multifocal a* lesions (Figure 5e), and a *focal* form was detected in the remaining lamb. The morphological features of the granulomatous lesions found at 390 dpi among the animals infected with the C-type strains, regardless of the group, differed from those observed at 150 dpi. In the former, all the granulomas, both those located in the lymphoid tissue area and in the LP (related or unrelated to the lymphoid

Table 2 Distribution of experimental animals in the infected groups according to their lesion type and the results of the nested-PCR

Experimental group	Time of sampling	Animal ID	Type of lesion	Nested PCR results		
				ICV	mJP	JLN
S-type strains						
22-G	150 dpi	1	Focal	+	+	+
		2	Focal	+	+	+
	390 dpi	3	Focal	+	+	+
		4	Focal	+	+	-
		5	Focal	+	+	+
		6	No lesion	-	+	-
Ovicap 49	150 dpi	7	Focal	+	+	+
		8	Focal	+	+	-
	390 dpi	9	Focal	+	+	+
		10	No lesion	+	-	-
		11	Focal	-	+	-
		12	Focal	+	-	-
C-type strains						
764	150 dpi	13	Diffuse	+	+	+
		14	Diffuse	+	+	+
	390 dpi	15	Multifocal a	+	+	+
		16	Multifocal a	+	+	+
		17	Focal	-	+	-
		18	Multifocal b	+	+	+
K-10	150 dpi	19	Multifocal b	+	+	+
		20	Multifocal a	+	+	+
	390 dpi	21	No lesion	-	-	-
		22	Multifocal a	+	+	+
		23	Focal	-	+	+

tissue) were significantly smaller, round and very well-demarcated from the adjacent tissue by a fibrous tissue capsule than those found at 150 dpi (Figure 5e). When the sections stained with Masson's trichrome were examined, a marked amount of collagen fibres was seen among the macrophages, lymphocytes and Langhans giant cells that formed the granulomas, regardless of their location in the intestine (Figure 5f). Very occasionally, granulomas found in the lymphoid tissue in the lamb from group 764 with a *multifocal b* lesion, showed a necrotic centre with dystrophic mineralization.

Besides the intestine, granulomatous lesions were also found in the lymph nodes, mainly in the MLN and JLN. In lambs from K-10 and 764 groups showing the more severe intestinal lesions (*multifocal b* and *diffuse*), a diffuse granulomatous lymphadenitis was observed. It was composed of a granulomatous infiltrate, similar to that seen in the intestine, formed by macrophages and some Langhans giant cells, that was spread throughout the

interfollicular and paracortical areas, with a multifocal distribution. In a number of occasions, always corresponding to the animals with *diffuse* lesions, these granulomas coalesced and invaded the adjacent lymphoid follicles, causing a marked distortion in the morphology and enlargement on the lymph node. A necrotic centre, occasionally with mineralization, was also seen in some granulomas. On the contrary, the lambs with *focal* or *multifocal a* lesions in the intestine from any of the four experimental groups, showed a focal granulomatous lymphadenitis characterized by one or two small granulomas composed of less than 10 macrophages (rarely small multinucleated cells were detected in lambs from groups K-10 and 764), located in the interfollicular part of the cortical area of the ICLN, MLN or JLN.

No AFB or *Map* antigens were detected in any of the control lambs or in all the lesions classified as *focal* or *multifocal a*, regardless of the experimental group. Only in animals with *multifocal b* or *diffuse* lesions were

solitary or few AFB detected both by ZN and immunohistochemistry, only in the granulomas located in the LP. In the lymph nodes, occasional AFB were observed in samples of lambs with intestinal *diffuse* lesions.

Granuloma count

Table 3 shows the mean of the total granuloma counts per animal, corresponding to the different experimental groups and the time of euthanasia. Differences in the lesion severity, with variations among individuals of the same group, were observed. Significant reduction in the number of granulomas ($P < 0.001$) was noticed between animals euthanized at 150 and 390 dpi in both groups infected with C-type strains whereas no differences were found in animals infected with the S-type strains either between 22G and Ovicap49 groups or the time of sampling. Moreover, animals from the 764 group had a higher amount of granulomatous lesions, both at 150 and 390 dpi ($P < 0.001$) than lambs from the K-10 group.

Figure 6 shows the mean granuloma counts corresponding to the different intestinal compartments examined in lambs from K-10 and 764 groups at 150 and 390 dpi. A reduction in the number of granulomas present in the lymphoid tissue and related LP between 150 and 390 dpi ($P < 0.05$) was observed in both groups. It is worth highlighting the marked decrease in the number of granulomas located in the LP not associated with the lymphoid tissue in the 764 group ($P < 0.001$), in agreement with the previously described types of lesion. In the groups infected with the S-type strains, all the granulomas appeared exclusively in the intestinal lymphoid tissue, with no differences between groups or time of sampling (Table 3).

The distribution of the lesions in each intestinal location examined in the different experimental groups is shown in Figure 7. In the groups infected with S-type strains (Figure 7a), lesions were found exclusively in the ICV and the different JPP. It is noteworthy that IL samples were always negative, even though lymphoid tissue was present in all the sections examined. Although granulomas appear to be slightly more numerous in the

JPP samples than in the ICV in both groups (Figure 7), differences were not statistically significant. In contrast, in the groups infected with C-type strains (Figure 7b) granulomas were appreciated in all the samples with lymphoid tissue (ICV, IL and JPP). Although the number of granulomas seemed to be higher in the JPP than in the other regions, differences were only statistically significant ($P < 0.05$) in animals from group K-10. When comparing both groups, granuloma counts were higher in all the locations in the 764 than in the K-10 group, remarkably in the ICV, IL and JJ samples ($P < 0.001$).

In addition to the intestine, granulomas were also noted in the associated lymph nodes. They were always more numerous in animals infected with the C- rather than the S-type strains ($P < 0.05$). When considering the different groups, no differences were found between the S strain challenged groups, but granulomas were more numerous in the 764 than in the K-10 group ($P < 0.05$). In accordance with the results of the intestine, a significant decrease was also appreciated in the granuloma counts between 150 and 390 dpi ($P < 0.05$) in animals from both groups infected with the C-type strains. Granulomas were counted more frequently in the JLN than in the other lymph nodes in all the groups.

Nested PCR

IS900 *Map*-specific sequence was demonstrated by nested PCR in all 12 lambs infected with the S-type strains including animals with no lesions, from at least 1 of the 3 analysed tissue sections (Table 2). No significant differences in the positivity detected among the examined locations were observed. One lamb euthanized at 390 dpi from the K-10 group, which was categorized as having no lesions, was negative to the presence of *Map* DNA (Table 2). The other animals infected with C-type strains were positive from at least 1 tissue section examined. As in the rest of the groups, no statistical differences were seen in the positivity rates among the locations analysed.

All tissue sections from the uninfected control lambs were negative using PCR.

Discussion

The results of this study show that sheep can become experimentally infected with either C or S-type strains of *Map*, as previously documented [10,23], but clear differences in the immune response and especially in the lesion development occur in relation with the type of strain.

Variations in the morphology of the granulomatous lesions due to different *Map* isolates were previously reported [23], where infection with C-type strains caused the appearance of a larger number of giant cells and central caseous necrosis in lambs examined at 150 dpi,

Table 3 Total granuloma counts per animal

	150 dpi	390 dpi
S-type strains		
22G	2.705 ± 0.86	2.16 ± 1.57
Ovicap49	2.42 ± 1.04	1.63 ± 1.75
C-type strains		
764	144.355 ± 38.4	27.122 ± 14.5
K-10	22.305 ± 2.18	8.21 ± 12.4

Granuloma counts from the tissues of lambs infected with the S and C strains and euthanised at 150 and 390 dpi. Mean number of granulomas per animal ± standard deviation.

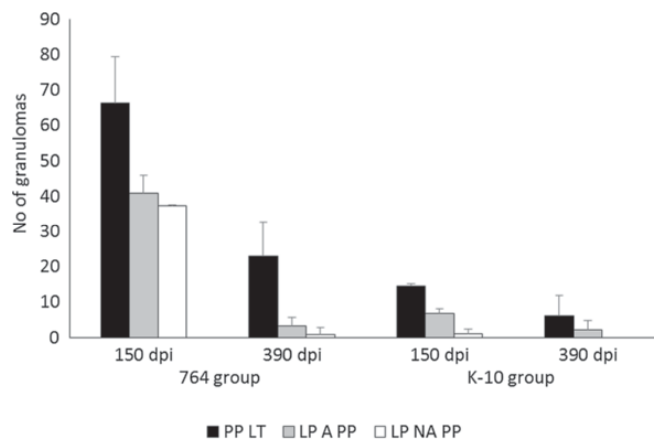


Figure 6 Granuloma counts from the C-type strains infected lambs in the different intestinal compartments. Count of granulomas from the tissues of the C-type strains infected groups (764 and K-10) culled at 150 and 390 dpi. Mean number of the granulomas per animal, corresponding to their location in the different intestinal compartments. dpi: days post infection. Error bars: standard deviation. PP LT: Peyer's patches lymphoid tissue. LP A PP: lamina propria associated with Peyer's patches. LP NA PP: lamina propria not associated with Peyer's patches.

which was demonstrated in the current study. These findings are closer to the lesions described in natural bovine paratuberculosis [6] than those seen more frequently in sheep, where giant cells are not a very characteristic hallmark [1,5]. Considering that our study and that of Verna et al. [23] used different C-type strains, with similar pathological findings, it seems feasible to conclude that C strains rather than host species, are the cause of some of the pathological characteristics of *Map* infection.

Some of the lambs infected with C-type strains, at 150 dpi showed diffuse lesions affecting wide areas of intestinal mucosa not associated with the lymphoid tissue, which has been regarded as related to more advanced stages of *Map* infection [4-6,23,28,29]. According to the pathological findings at 390 dpi, lesions induced by C strains in sheep showed an evolution towards resolution, with a marked decrease in their severity, characterized by lower numbers of smaller, well-encapsulated and fibrotic granulomas. Although Verna et al. [23] noted some degree of fibrosis in some lesions induced by C-type strains, their study ended at 150 dpi and moreover, lesion severity was not assessed. Granulomas showing fibrosis could be considered as "regressive" type lesions, as similar histological features have been described in lambs vaccinated and experimentally infected with *Map* [4,29,30], where they have been associated with a regression of the infection in immunized animals, or in minipigs infected with *Mycobacterium tuberculosis* in the lung [31], related to a contention of the infection. This finding would suggest that in lambs infected with C-type strains, if the experimental infection had been

prolonged for a longer period, infection could have been contained or even regress, with resolution of lesions and recovery of tissue morphology. The fact that one lamb from the K-10 group that showed a specific cellular immune response did not show any lesion and was negative for *Map* DNA identification in the tissues sampled at 390 dpi, further supports this hypothesis.

In paratuberculosis vaccinated animals, the efficacy of the vaccine in controlling the progression of the infection has been associated with the induction of a protective and vigorous cellular immune response [30,32]. In this study, the intense IFN- γ production seen in C-type strains infected lambs could be related to the regression of the lesions. In a previous experiment, S-type *Map* isolates also proved to be less pathogenic and induced a weaker cell-mediated immune response compared with a C strain, when infecting sheep [10], but a pathological evaluation of the lesions was not assessed. Thus, from our results, it can be hypothesized that infection induced by C-type strains could have reached its highest development around 150 dpi, but infected lambs were able to mount a more efficient and specialized immunologic response that would have caused a regression of the lesions. A similar mechanism has been proposed to occur in adult ewes or cows infected with *Map* showing a higher resistance to infection [27,28,33]. It might have been interesting to have followed these animals over a more uniform and longer timescale such as culling every two months after infection for a longer period.

On the contrary, lambs infected with S-type strains only showed focal granulomatous lesions, restricted to the lymphoid tissue, and not associated with a detectable

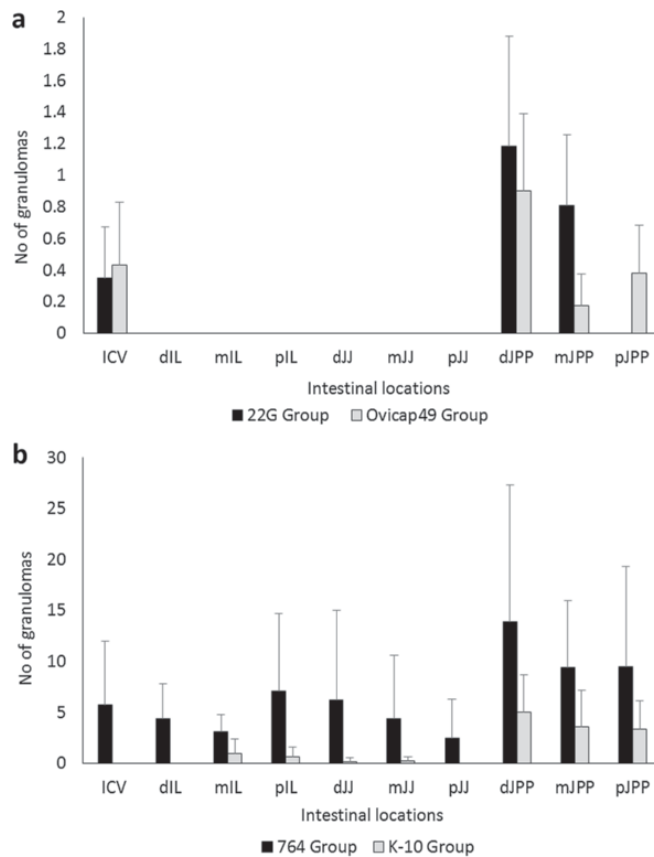


Figure 7 Granuloma counts according to their intestinal location. Total granuloma count from the tissues of the S (a) and C (b) strains infected groups, regardless of the time of sampling. Mean of the total number of granulomas per tissue section and animal, according to their intestinal location. ICV, ileocecal valve; IL, ileum; JJ, jejunum; JPP, jejunal Peyer's patches. d, distal; m, medium; p, proximal. Error bars: standard deviation.

peripheral immune response. This type of lesion has been described in experimental paratuberculosis in sheep [4,28,29,34] and also in adult animals in natural cases, raising the hypothesis that they could be considered as latent lesions present in adult animals infected earlier in life or as initial lesions of recently infected adult individuals [5]. Our results, showing the presence of similar focal granulomatous lesions at 150 dpi and 390 dpi in the infected animals that did not appear in the control lambs, would further support the hypothesis of the latent character of the focal lesions.

In natural or experimental cases, the majority of sheep with focal lesions show a marked peripheral cellular immune response [9,27]. However, in our study, only some lambs were sporadically positive to IGRA, with no statistical differences when compared with the control animals when taking the overall results, even though a

specific but weak cellular immune response was detected by IDT. This finding would indicate that IDT may be more sensitive than IGRA, as has been previously reported [9,35]. However, this is not in agreement with the results obtained in the groups infected with C-type strains, where the IDT response was similar to the S groups but accompanied by a higher IFN- γ response. From these results, it can be hypothesised that there are differences in the immune response induced by both types of strains, as has been demonstrated in several in vitro studies [20,21]. Moreover, the hypothesis that IDT and IGRA would measure different factors operating in the specific cell mediated immune response against *Map* should be considered and further investigated.

The possibility that these animals with focal forms have not mounted a persistent and measurable peripheral specific production of IFN- γ should also be considered, in the

light of the work of Vazquez et al. [36], where they found a large proportion of cattle with focal lesions negative to IGRA. In the present study, lambs infected with S-type strains would fit the recently proposed pathogenesis model of *Map* infection [36] that considers focal lesions as a condition of certain natural resistance or premonition sustained by the presence of a continuous confined inflammatory focus. Furthermore, our results from the peripheral immune responses in the whole experiment, did not support the standard model of immunity to paratuberculosis in which in the early stages of the disease peripheral IFN- γ release is the main response, while it decreases in the more advanced forms where humoral responses predominate [2,37]. Our results in the lambs infected with C-type strains show a mixed cellular and humoral response from 120 to 330 dpi, probably in coincidence with the highest severity of the inflammatory response, while in the lambs challenged with S-type strains, there were minimal inflammatory lesions, and no IFN- γ production was observed. This finding would coincide with recent studies [10,36,38] that question the Th1 dominancy in the early stages of *Map* infection.

Recent work carried out after the *in vitro* infection of bovine macrophages with different *Map* strains have shown different patterns of cytokine expression: while C-type strains have a high rate of survival inside the cells related to an anti-inflammatory response characterized by an up-regulation of IL-10, S-type strains showed a lower persistence with a significantly up-regulated pro-inflammatory response [20,21]. These findings indicate that the survival of the *Map* strains within bovine macrophages is strongly associated with the specific host from which the isolates were initially isolated [20]. A similar mechanism could operate at the level of the intestinal macrophages after *Map* infection, suggesting that the local immune responses occurring at the intestinal lymphoid tissue level should play an important role in *Map* pathogenesis. This deserves to be further investigated in the lambs from this study. In this sense, previous studies [3,39] have shown the importance of the immune response mounted in the Peyer's patches in the early stages of paratuberculosis and its lack of correspondence with the peripheral immune response.

In contrast to other experimental infections carried out by our group in lambs using S-type strains [23,28], none of the lambs of this study showed widespread lesions, that in previous studies were seen as soon as 120–150 dpi. It could be postulated that the use of low passage, pure culture of *Map* inocula in this experiment instead of an intestinal mucosal homogenate from a naturally affected sheep, as in the other studies, could explain this. *Map* infections are more easily and rapidly established when the challenge inoculum was prepared from gut mucosal tissue than from cultured bacteria

[10,40]. Our results possibly mimic what occurs in natural conditions, where a great majority of infected animals show focal and latent lesions [5,36] similar to those found in our study. Further supporting this finding, in the experiment carried out by Begg et al. [34] infecting larger groups of lambs with a cultured S strain, animals with widespread lesions only appeared in some lambs examined 10–19 months after the infection. Thus, it seems feasible that, should the length of the experimental infection had been prolonged, lesions could have progressed towards more severe forms in some of the lambs infected with the S *Map* strains. On the contrary, the possibility that the S-type strains used had a lower pathogenicity than those used in previous studies cannot be discounted. The existence of variations in pathogenicity among the different strains of *Map* has already been reported [13,23,40] and has been confirmed among the C strains in this study, where the 764 isolate induced more intense immune and pathological responses than the K-10 strain. The fact that the latter is a *Map* reference strain with a high number of culture passages could have contributed to its lower pathogenicity [40]. However, no differences were observed between the two S strains employed; both were low passage cultures, isolated from clinical cases of ovine paratuberculosis. Although traditionally ovine pigmented strains have been considered as having a higher pathogenicity [13,41], this fact is not supported by our results.

Differences in the pathogenicity have also been associated with the dose administered to the experimental animals [4,28]. In our study, the dose employed is comparable to those used in other studies [10,23,28,34] and has been shown to cause the infection. A good correlation was observed between the expected number of bacteria assessed by the McFarland method and the CFU counts evaluated by plating serial dilutions, as previously stated [26], except for the pigmented strain Ovicap49. Such an unexpected difference between optical density and viable cell count could be explained by the enormous difficulty in culturing this concrete ovine pigmented strain, especially on the surface of solid media, rather than by an actual reduction in the number of viable units.

This study has also shown the importance of the intestinal lymphoid tissue in the establishment of paratuberculosis infection, regardless of the strain used, since most of the granulomatous lesions appeared in this tissue, as was previously observed [4,5,23,28,29], further confirming the role of the Peyer's patches both as a primary portal of entry of *Map* in the organism and in the persistence for longer periods of time of focal granulomatous lesions representing forms of latency or resistance.

Regarding the distribution of the lesions along the different intestinal sites and their intensity, the granuloma

count showed a marked variation between the individuals and the different sections of the intestine, as has previously been reported as a typical feature of natural and experimental paratuberculosis [4,28,34,40]. In all the experimental groups, JPP has been the region harbouring the highest amount of lesions followed by the ICV, whereas lesions in the ileal Peyer's patches (IPP) appeared in low numbers and only in lambs infected with the C-type strains. This finding has been reported previously [28,42] and could indicate a different functional pattern between IPP and JPP related to the morphological and lymphocyte distribution differences observed [42,43]. Lesions only appeared in the lymph nodes when they were already present in the intestine in a remarkably lower number. This finding, supported by other studies [5,28], would confirm the critical role of the intestinal lymphoid tissue in the start of *Map* infection, which would be detected in the lymph nodes only when lesions are well established in the gut.

The recognized difficulty in culturing *Map* from ovine tissues [19,29] in terms of slowness and low performance of bacterial isolation, was the reason for using a nested PCR method for confirming *Map* infection in the tissues of the challenged animals, in addition to the presence of the specific granulomatous lesions or AFB. This method has successfully been used and shown to have a higher sensitivity than *Map* culture or other PCR methods [28,44]. However, it has to be taken into account that the PCR method identifies DNA in the tissues that could have originated from non-viable and/or degraded bacilli. In our study, the presence of *Map* DNA was demonstrated in all infected animals, except one from the K-10 group culled at 390 dpi in which no lesion was detected, with no other differences with the time of sampling, in contrast to the lower number of granulomas detected at 390 dpi. It can be hypothesised that if bacterial culture had been performed, a lower number of colonies would have been isolated at 390 dpi in C strain infected lambs. Furthermore, similar to previous studies [28], two lambs infected with S-type strains, in which no lesions were observed, were also positive for PCR. In contrast to the higher prevalence of lesions in the JPP, no differences in the percentages of positivity by PCR were detected among the three regions of gut analysed, suggesting that the DNA from *Map* is spread along the intestinal tissues even without being related to evident lesions.

The low rate of identification of AFB in the tissues either by ZN or immunohistochemical methods was not surprising. Previous studies have shown that the focal and multifocal lesions contain no or very few AFB [5,6,23,28]. The morphology of the diffuse lesions found in the 764 group was consistent with the so-called "lymphocytic" diffuse forms of paratuberculosis [1,5,6], characterised by the presence of very low numbers of bacteria.

This study has shown clear differences in the pathogenesis of *Map* infection related to the type of strain used in an experimental infection of lambs. Infection caused by C-type strains was more rapidly and easily established, showing the most severe lesions and a stronger immune response. However, as the infection progresses, a marked reduction in the amount and severity of the lesions, consistent with a regressive character, was observed in association with a high peripheral cellular response suggesting that, with time, infection could have disappeared in these animals. In contrast, lambs infected with S-type strains developed focal granulomas located in the intestinal lymphoid tissue that persisted throughout the experiment. Although, in field cases, cross infection between S and C strains has been reported [17-19], its occurrence has been considered as infrequent [14,15,45]. Considering our results, it seems feasible that in areas where cattle and sheep graze together and cross infection could occur naturally [18,46], most of the sheep infected with C-type-strains could recover from the infection.

Competing interests

The authors declare that they have no competing interests.

Authors' contributions

MF performed the experiment, participated in all the immune response and pathological studies and collaborated in the analysis of the data and writing of the paper. JB contributed to the sample collection, pathological studies, interpretation of the results and helped to draft the manuscript. IAS prepared the administered inocula and collaborated in writing the paper. MF participated in the sample collection, pathological studies and carried out the immunohistochemical analysis. PC performed the immune response analysis and helped in the sample collection. LD contributed to sample collection and to the pathological studies. JFGM collaborated in the pathological studies. JMG participated in the design of the experiment and inocula preparation. MCF collaborated in the sample collection, analysis of the data and helped write the manuscript. VP conceived and designed the experiment, analysed the data and wrote the paper. All the authors read and approved the final manuscript.

Acknowledgements

This work was supported by grant AGL2008-05820-C02 of the Spanish Ministry of Science and Innovation. The authors wish to thank all the staff of the IGM (CSIC-ULE) responsible for handling the experimental animals. The technical help of S. Morales, G. Belver and J. Reyero, and the proof-reading of the manuscript by Dr Stephen Maley, of the Moredun Research Institute, is also acknowledged. M. Fernández is founded by a predoctoral contract from the "Junta de Castilla y León". J. Benavides is supported by CSIC through the JAE-Doc program, financed in part by European Social Fund (ESF). We acknowledge support of the publication fee by the CSIC Open Access Publication Support Initiative through its Unit of Information Resources for Research (URIC).

Author details

¹Departamento de Sanidad Animal, Instituto de Ganadería de Montaña (CSIC-ULE), Facultad de Veterinaria, Universidad de León, Campus de Vegazana s/n, León 24071, Spain. ²Departamento de Sanidad Animal, NEIKER-Tecnalia, Berreaga 1, Derio, Bizkaia 48160, Spain.

Received: 9 September 2013 Accepted: 8 January 2014

Published: 16 January 2014

References

1. Clarke CJ: The pathology and pathogenesis of paratuberculosis in ruminants and other species. *J Comp Pathol* 1997, **116**:217-261.

2. Whittington RJ, Begg DJ, de Silva K, Plain KM, Purdie AC: **Comparative immunological and microbiological aspects of paratuberculosis as a model mycobacterial infection.** *Vet Immunol Immunopathol* 2012, **148**:29–47.
3. Gillan S, O'Brien R, Hughes AD, Griffin JFT: **Identification of immune parameters to differentiate disease states among sheep infected with *Mycobacterium avium* subsp. paratuberculosis.** *Clin Vaccine Immunol* 2010, **17**:108–117.
4. Nisbet DI, Gilmour NJL, Brotherston JG: **Quantitative studies of *Mycobacterium johnei* in tissues of sheep: III: Intestinal histopathology.** *J Comp Pathol* 1962, **72**:80–91.
5. Pérez V, García Marín JF, Badiola JJ: **Description and classification of different types of lesion associated with natural paratuberculosis infection in sheep.** *J Comp Pathol* 1996, **114**:107–122.
6. González J, Geijo MV, García Pariente C, Verna A, Corpa JM, Reyes LE, Ferreras MC, Juste RA, García Marín JF, Pérez V: **Histopathological classification of lesions associated with natural paratuberculosis infection in cattle.** *J Comp Pathol* 2005, **133**:184–196.
7. Clarke CJ, Patterson IAP, Armstrong KE, Low JC: **Comparison of the absorbed ELISA and agar gel immunodiffusion test with clinicopathological findings in ovine clinical paratuberculosis.** *Vet Rec* 1996, **139**:618–621.
8. Pérez V, Tellechea J, Badiola JJ, Gutiérrez MM, García Marín JF: **Relation between serologic response and pathologic findings in sheep with naturally acquired paratuberculosis.** *Am J Vet Res* 1997, **58**:799–803.
9. Pérez V, Tellechea J, Corpa JM, Gutiérrez M, García Marín JF: **Relation between pathologic findings and cellular immune responses in sheep with naturally acquired paratuberculosis.** *Am J Vet Res* 1999, **60**:123–127.
10. Stewart DJ, Vaughan JA, Stiles PL, Noske PJ, Tizard MLV, Prowse SJ, Michalski WP, Butler KL, Jones SL: **A long-term study in Merino sheep experimentally infected with *Mycobacterium avium* subsp. paratuberculosis: clinical disease, faecal culture and immunological studies.** *Vet Microbiol* 2004, **104**:165–178.
11. Borrmann E, Möbius P, Diller R, Köhler H: **Divergent cytokine responses of macrophages to *Mycobacterium avium* subsp. paratuberculosis** strains of Types II and III in a standardized *in vitro* model. *Vet Microbiol* 2011, **152**:101–111.
12. O'Brien R, Mackintosh CG, Bakker D, Kopecna M, Pavlik I, Griffin JFT: **Immunological and molecular characterization of susceptibility in relationship to bacterial strain differences in *Mycobacterium avium* subsp. paratuberculosis** infection in red deer (*Cervus elaphus*). *Infect Immun* 2006, **74**:3350–3357.
13. Taylor AW: **The varieties of *Mycobacterium johnei* isolated from sheep.** *J Pathol Bacteriol* 1951, **63**:333–336.
14. Collins DM, Gabric DM, de Lisle GW: **Identification of two groups of *Mycobacterium paratuberculosis* strains by restriction analysis and DNA hybridization.** *J Clin Microbiol* 1990, **28**:1591–1596.
15. Marsh I, Whittington R, Cousins D: **PCR-restriction endonuclease analysis for identification and strain typing of *Mycobacterium avium* subsp. paratuberculosis** and *Mycobacterium avium* subsp. *avium* based on polymorphisms in IS1311. *Mol Cell Probes* 1999, **13**:115–126.
16. Stevenson K, Hughes VM, de Juan L, Inglis NF, Wright F, Sharp JM: **Molecular characterization of pigmented and nonpigmented isolates of *Mycobacterium avium* subsp. paratuberculosis.** *J Clin Microbiol* 2002, **40**:1798–1804.
17. Dimareli-Malli Z, Mazaraki K, Stevenson K, Tsakos P, Zdragas A, Giantzi V, Petridou E, Heron I, Vareas G: **Culture phenotypes and molecular characterization of *Mycobacterium avium* subsp. paratuberculosis** isolates from small ruminants. *Res Vet Sci* 2013, **95**:49–53.
18. Moloney BJ, Whittington RJ: **Cross species transmission of ovine Johne's disease from sheep to cattle: an estimate of prevalence in exposed susceptible cattle.** *Aust Vet J* 2008, **86**:117–123.
19. Whittington RJ, Marsh IB, Saunders V, Grant IR, Juste R, Sevilla IA, Manning EJB, Whitlock RH: **Culture phenotypes of genomically and geographically diverse *Mycobacterium avium* subsp. paratuberculosis** isolates from different hosts. *J Clin Microbiol* 2011, **49**:1822–1830.
20. Abendaño N, Sevilla IA, Prieto JM, Garrido JM, Juste RA, Alonso-Hearn M: ***Mycobacterium avium* subspecies paratuberculosis** isolates from sheep and goats show reduced persistence in bovine macrophages than cattle, bison, deer and wild boar strains regardless of genotype. *Vet Microbiol* 2013, **163**:325–334.
21. Janagama HK, Il Jeong K, Kapur V, Coussens P, Srrevasan S: **Cytokine responses of bovine macrophages to diverse clinical *Mycobacterium avium* subspecies paratuberculosis** strains. *BMC Microbiol* 2006, **6**:10.
22. Juste RA, Marco JC, Saez de Ocariz C, Adúriz JJ: **Comparison of different media for the isolation of small ruminant strains of *Mycobacterium paratuberculosis*.** *Vet Microbiol* 1991, **28**:385–390.
23. Verna AE, García-Pariente C, Muñoz M, Moreno O, García Marín JF, Romano MI, Paolicchi F, Pérez V: **Variation in the immuno-pathological responses of lambs after experimental infection with different strains of *Mycobacterium avium* subsp. paratuberculosis.** *Zoonoses Public Health* 2007, **54**:243–252.
24. Sevilla I, Garrido JM, Geijo M, Juste RA: **Pulsed-field gel electrophoresis profile homogeneity of *Mycobacterium avium* subsp. paratuberculosis** isolates from cattle and heterogeneity of those from sheep and goats. *BMC Microbiol* 2007, **7**:18.
25. Elguezabal N, Bastida F, Sevilla IA, González N, Molina E, Garrido JM, Juste RA: **Estimation of *Mycobacterium avium* subsp. paratuberculosis** growth parameters: strain characterization and comparison of methods. *Appl Environ Microbiol* 2011, **77**:8615–8624.
26. Hughes JB, Hellmann JJ, Ricketts TH, Bohannon BJ: **Counting the uncountable: statistical approaches to estimating microbial diversity.** *Appl Environ Microbiol* 2001, **67**:4399–4406.
27. Delgado L, Juste RA, Muñoz M, Morales S, Benavides J, Ferreras MC, García Marín JF, Pérez V: **Differences in the peripheral immune response between lambs and adult ewes experimentally infected with *Mycobacterium avium* subspecies paratuberculosis.** *Vet Immunol Immunopathol* 2012, **145**:23–31.
28. Delgado L, García Marín JF, Muñoz M, Benavides J, Juste RA, García-Pariente C, Fuertes M, González J, Ferreras MC, Pérez V: **Pathological findings in young and adult sheep following experimental infection with 2 different doses of *Mycobacterium avium* subsp. paratuberculosis.** *Vet Pathol* 2013, **50**:857–866.
29. Juste RA, García Marín JF, Peris B, Sáez-de-Ocariz C, Badiola JJ: **Experimental infection of vaccinated and non-vaccinated lambs with *Mycobacterium paratuberculosis*.** *J Comp Pathol* 1994, **110**:185–194.
30. Gwozdz JM, Thompson KG, Manktelow BW, Murray A, West DM: **Vaccination against paratuberculosis of lambs already infected experimentally with *Mycobacterium avium* subspecies paratuberculosis.** *Aust Vet J* 2000, **78**:560–566.
31. Gil O, Diaz I, Vilaplana C, Tapia G, Diaz J, Fort M, Cáceres N, Pinto S, Cayla J, Corner L, Domingo M, Cardona PJ: **Granuloma encapsulation is a key factor for containing tuberculosis infection in minipigs.** *PLoS One* 2010, **5**:e10030.
32. Begg DJ, Griffin JF: **Vaccination of sheep against *M. paratuberculosis*: immune parameters and protective efficacy.** *Vaccine* 2005, **23**:4999–5008.
33. Payne JM, Rankin JD: **A comparison of the pathogenesis of experimental Johne's disease in calves and cows.** *Res Vet Sci* 1961, **2**:175–179.
34. Begg DJ, de Silva K, Di Fiore L, Taylor DL, Bower K, Zhong L, Kawaji S, Emery D, Whittington RJ: **Experimental infection model for Johne's disease using a lyophilised pure culture, seedstock of *Mycobacterium avium* subspecies paratuberculosis.** *Vet Microbiol* 2010, **141**:301–311.
35. Dunn JR, Kaneene JB, Grooms DL, Bolin SR, Bolin CA, Bruning-Fann CS: **Effects of positive results for *Mycobacterium avium* subsp. paratuberculosis** as determined by microbial culture of feces or antibody ELISA on results of caudal fold tuberculin test and interferon-gamma assay for tuberculosis in cattle. *J Am Vet Med Assoc* 2005, **226**:429–435.
36. Vazquez P, Garrido JM, Juste RA: **Specific antibody and interferon-gamma responses associated with immunopathological forms of bovine paratuberculosis in slaughtered Friesian cattle.** *PLoS One* 2013, **8**:e64568.
37. Stabel JR: **Transitions in immune responses to *Mycobacterium avium paratuberculosis*.** *Vet Microbiol* 2000, **77**:465–473.
38. Begg DJ, de Silva K, Carter N, Plain KM, Purdie A, Whittington RJ: **Does a Th1 over Th2 dominance really exist in the early stages of *Mycobacterium avium* subspecies paratuberculosis** infections? *Immunobiology* 2010, **216**:840–846.
39. Begara-McGorum I, Wildblood LA, Clarke CJ, Connor KM, Stevenson K, McInnes CJ, Sharp JM, Jones DG: **Early immunopathological events in experimental ovine paratuberculosis.** *Vet Immunol Immunopathol* 1998, **63**:265–287.
40. Begg DJ, Whittington RJ: **Experimental animal infection models for Johne's disease, an infectious enteropathy caused by *Mycobacterium avium* subsp. paratuberculosis.** *Vet J* 2008, **176**:129–145.

41. Stamp JT, Watt JA: **Johne's disease in sheep.** *J Comp Pathol* 1954, **64**:26–39.
42. Valehim M, Storset AK, Aleksandersen M, Brun-Hansen H, Press CM: **Lesions in subclinical paratuberculosis of goats are associated with persistent gut-associated lymphoid tissue.** *J Comp Pathol* 2002, **127**:194–202.
43. Corpa JM, Juste RA, García Marín JF, Reyes LE, González J, Pérez V: **Distribution of lymphocyte subsets in the small intestine lymphoid tissue of 1-month-old lambs.** *Anat Histol Embryol* 2001, **30**:121–127.
44. Bull TJ, McMinn EJ, Sidi-Boumediane K, Skull A, Durkin D, Neild P, Rhodes G, Pickup R, Hermon-Taylor J: **Detection and verification of *Mycobacterium avium* subsp. *paratuberculosis* in fresh ileocolonic mucosal biopsy specimens from individual with and without Crohn's disease.** *J Clin Microbiol* 2003, **41**:2915–2923.
45. Whittington RJ, Hope AF, Marshall DJ, Taragel CA, Marsh I: **Molecular epidemiology of *Mycobacterium avium* subsp. *paratuberculosis*: IS900 restriction fragment length polymorphism and IS1311 polymorphism analyses of isolates from animals and a human strain in Australia.** *J Clin Microbiol* 2000, **38**:3240–3248.
46. Muskens J, Bakker D, de Boer J, van Keulen L: **Paratuberculosis in sheep: its possible role in the epidemiology of paratuberculosis in cattle.** *Vet Microbiol* 2001, **78**:101–109.

doi:10.1186/1297-9716-45-5

Cite this article as: Fernández *et al.*: Experimental infection of lambs with C and S-type strains of *Mycobacterium avium* subspecies *paratuberculosis*: immunological and pathological findings. *Veterinary Research* 2014 **45**:5.

**Submit your next manuscript to BioMed Central
and take full advantage of:**

- Convenient online submission
- Thorough peer review
- No space constraints or color figure charges
- Immediate publication on acceptance
- Inclusion in PubMed, CAS, Scopus and Google Scholar
- Research which is freely available for redistribution

Submit your manuscript at
www.biomedcentral.com/submit





Contents lists available at ScienceDirect

Research in Veterinary Science

journal homepage: www.elsevier.com/locate/rvsc

Virulence attenuation of a *Mycobacterium avium* subspecies *paratuberculosis* S-type strain prepared from intestinal mucosa after bacterial culture. Evaluation in an experimental ovine model



Miguel Fernández^a, Laetitia Delgado^a, Iker A. Sevilla^b, Miguel Fuertes^a, Pablo Castaño^a, Marcos Royo^a, M. Carmen Ferreras^a, Julio Benavides^a, Valentín Pérez^{a,*}

^a Departamento de Sanidad Animal, Instituto de Ganadería de Montaña (CSIC-ULE), Facultad de Veterinaria, Universidad de León, Campus de Vegazana s/n, 24071 León, Spain

^b Departamento de Sanidad Animal, NEIKER-Tecnalia, Berreaga 1, 48160 Derio, Bizkaia, Spain

ARTICLE INFO

Article history:

Received 8 October 2014

Accepted 6 February 2015

Keywords:

Mycobacterium avium subsp.*paratuberculosis*

Sheep

Gut homogenate

Cultured strain

Experimental infection

ABSTRACT

The differences in pathogenicity between an inoculum derived directly from an intestinal tissue homogenate from a paratuberculosis affected sheep and the S-type *Mycobacterium avium* subsp. *paratuberculosis* (*Map*) strain isolated in laboratory media from the mentioned homogenate were assessed in two experiments in lambs. Specific peripheral immune responses were significantly lower in animals inoculated with the cultured organisms that showed only granulomatous lesions in the intestinal lymphoid tissue. However, in the homogenate group, more abundant granulomata also occurred in the lamina propria. *Map* was isolated only in lambs infected with the culture strain. *Map* DNA was demonstrated by nested-PCR in all the lambs but in a lower proportion (57.1% vs 100%) in those from the culture group. Under these particular experimental conditions, the results suggest that an attenuation of *Map* virulence has occurred in the cultured strain compared to the initial tissue homogenate, even after a low number of passages.

© 2015 Elsevier Ltd. All rights reserved.

1. Introduction

Paratuberculosis or Johne's disease is a chronic bacterial infection of wild and domestic ruminants caused by *Mycobacterium avium* subsp. *paratuberculosis* (*Map*). Infected animals develop granulomatous enteritis associated with a progressive loss of weight, diarrhea and eventually death. The infection by *Map* is widespread, causes important economic losses to livestock and it has been associated with Crohn's disease in humans (Bull et al., 2003; Juste, 2012).

Experimental infection is considered an essential tool to investigate different aspects of paratuberculosis as it allows control of different variables that operate in the interaction between *Map* and the host. Due to the variety of challenge models employed, standard guidelines have been proposed with the objective of being accepted worldwide (Hines II et al., 2007).

Sheep have been used as an experimental model of paratuberculosis as the results can be easily extrapolated to other ruminant species but the main difficulty encountered has been the type of

infectious inoculum employed (Begg and Whittington, 2008; Begg et al., 2010; Hines II et al., 2007). *Map* strains are classified by the use of IS900 restriction fragment length polymorphism (RFLP) and IS1311 PCR-restriction enzyme analysis (PCR-REA), into two main genotypes (Collins et al., 1990; Sevilla et al., 2005; Stevenson et al., 2002): sheep or ovine isolates (also called "S type" or "type-I and III"), associated with natural ovine paratuberculosis, and cattle or bovine isolates (also called "C type" or "type II"). When C-type strains have been used to challenge sheep, the outcome of the infection has shown marked differences with that seen in natural conditions (Fernández et al., 2014; Stewart et al., 2004; Verna et al., 2007). Therefore, it has been recommended to use S-type strains to more closely reproduce natural ovine infections (Hines II et al., 2007). However, the difficulty in culturing S-type strains (Whittington et al., 2011) is probably the main reason why tissue homogenates obtained from intestinal mucosal scrapings from clinically diseased animals have been the preferred inocula (Begg and Whittington, 2008; Delgado et al., 2013; Kurade et al., 2004; Stewart et al., 2004; Verna et al., 2007). Conversely, it has been advised not to use direct tissue homogenate as inocula for experimental challenge studies in sheep due to the low repeatability as a consequence of the limited amount of material available from any given animal. Additionally, the inability to control all the components present in the inoculum is why the use of virulent, low passage S-type strain cultivated *in vitro* has been recommended for inocula (Hines II et al., 2007).

* Corresponding author. Departamento de Sanidad Animal, Instituto de Ganadería de Montaña (CSIC-ULE), Facultad de Veterinaria, Campus de Vegazana s/n, 24071 León, Spain. Tel.: +34 987 291327; fax: +34 987 291103.

E-mail address: vperp@unileon.es (V. Pérez).

Experimental infections in sheep using ovine cultured bacteria have shown discordant results with infectious rates ranging from very low levels to 100% (Begg et al., 2005; Fernández et al., 2014; Reddacliff and Whittington, 2003; Thorel et al., 1992). Previous studies (Begg et al., 2005, 2010; Stewart et al., 2004) have shown that infection was more clearly established when the challenge inoculum was prepared from intestinal tissue compared to cultured strains. It should be noted that in those studies the cultured strain used in the inoculum was isolated from a different sheep to that used in the preparation of the intestinal homogenate. Variations in pathogenicity among the different strains of *Map* have been already reported (Begg and Whittington, 2008; Fernández et al., 2014; Verna et al., 2007) and could explain the success differences on infected animals observed among the different inocula.

Recently, a model to evaluate the outcome of *Map* infection based on the assessment of histological changes together with the peripheral immune response, and *Map* detection in tissues, has been successfully employed in experimentally infected lambs (Delgado et al., 2013; Fernández et al., 2014). Pathological changes are evaluated by counting granulomata in the intestine and lymph nodes. In addition, the distribution of lesions in the same samples is analyzed in order to estimate the stage of the disease. According to the suggested pathogenesis of paratuberculosis, initial or latent lesions are restricted to the lymphoid tissue and when the infection progresses, granulomatous lesions extend to the intestinal lamina propria (Delgado et al., 2013; Juste et al., 1994; Kurade et al., 2004; Nisbet et al., 1962; Pérez et al., 1996).

The aim of this study was to investigate, in a lamb experimental model, the existence of differences in the virulence of an inoculum composed of either (1) homogenate of gut mucosal tissue from a diseased sheep or (2) the bacteria isolated from that homogenate obtained after laboratory culture, by assessing the peripheral humoral and cellular immune responses, the degree of bacterial colonization of the tissues and the pathological changes.

2. Material and methods

2.1. Challenge inocula

2.1.1. Intestinal mucosa derived homogenate inoculum

This inoculum was prepared from several ileal and jejunal pieces of tissue obtained from one sheep with clear clinical signs of paratuberculosis. Before extracting the mycobacteria, shedding of abundant acid fast bacilli (AFB) was confirmed by microscopical examination of fecal samples and histological sections of gut tissue. Mycobacteria were extracted following the method of Ratnamohan and Spencer (1986). The inoculum obtained was IS900 positive by polymerase chain reaction (PCR) and typed as an "ovine" strain by IS1311 PCR-restriction enzyme analysis (Garrido et al., 2000; Sevilla et al., 2005). Furthermore, the strain was typed using a *SnaBI-SpeI* pulse-field electrophoresis method (Sevilla et al., 2007) and only one profile was obtained, being characterized as a 69-50 type III strain.

For determining the concentration of organisms present in the inoculum, ten-fold dilutions were prepared and plated onto Middlebrook 7H11 medium, as described previously (Adúriz et al., 1995), to assess the number of colony forming units (CFU) per milliliter in the inoculum. The final concentration resulted in 4×10^6 CFU of *Map*/ml.

2.1.2. Pure culture inoculum

A positive *Map* isolation was obtained after plating the tissue homogenate inoculum both in Löwenstein–Jensen and Middlebrook 7H11 media. According to the procedures described (Garrido et al., 2000; Sevilla et al., 2005), both isolates were IS900 positive and classified an "ovine" strain by IS1311 PCR-REA. When typed by *SnaBI-*

SpeI pulse-field electrophoresis method (Sevilla et al., 2007), both isolates showed the same profile (69-50 type III strain) than the tissue homogenate inoculum. Thus, after the first isolation of the *Map* strain in 7H11 medium from the intestinal mucosa homogenate, one passage was made in Middlebrook 7H9 broth supplemented with OADC (oleic acid, albumin, dextrose, catalase) enrichment (Becton Dickinson and Co., MD), Tween 80 (Panreac Quimica SA, Barcelona, Spain), glycerol and mycobactin J (Allied Monitor Inc, Fayette, MO) and subsequently the strain was maintained at -80°C as a glycerol stock. Finally, the strain was propagated in 7H9 broth prepared as mentioned earlier. After 5 weeks at 37°C , cultures were harvested by centrifugation at $2800 \times g$ for 15 min. Bacterial pellets were washed twice in phosphate buffered saline (PBS), resuspended in PBS and the presence of clumps minimized by making the liquid flow up and down through a fine needle (26G3/8) several times. The turbidity (McFarland units) of the resultant suspension was measured using a Densimat (bioMérieux, Marcy l'Etoile, France). Expected cell concentration was estimated assuming one McFarland unit represented 1×10^8 cells/ml (Hughes et al., 2001). Concentration of the suspension resulted in 1×10^8 cells/ml. As for the tissue homogenate inoculum, the number of CFU was assessed by plating ten-fold dilutions of the suspension onto agar-solidified Middlebrook 7H11 medium (Adúriz et al., 1995). The final concentration resulted in 5×10^7 CFU/ml.

For both inocula and in order to assess the potential reduction of viability during the administration period, the plating procedure was repeated on the last challenge day using a separate aliquot prepared and kept under the same conditions as those of the administered inocula. After 15 days at 4°C , a reduction of less than one logarithm was detected in CFU counts of both inocula. In order to assess variations in the strain during the storage of the inocula, the isolate given to the lambs in the last challenge was typed by *SnaBI-SpeI* pulse-field electrophoresis method (Sevilla et al., 2007) and the same profile (69-50 type III strain) showed by the initial challenge dose isolate and the tissue homogenate inoculum.

2.2. Animals and experimental design

All protocols involving animals were approved by the Animal Welfare Committee of the "Instituto de Ganadería de Montaña CSIC-ULE", following procedures described in Spanish and EU legislation (Law 32/2007, R.D. 1201/2005, and Council Directive 2010/63/EU). All animals used in this study were handled in strict accordance with good clinical practice and all efforts were made to minimize suffering.

A total of 21 1-month old lambs of the Churra breed were used in the study. They were randomly selected from a single flock in which no clinical cases of paratuberculosis had been reported in the past 5 years. All the dams were negative for antibody detection to *Map* and peripheral blood mononuclear cells interferon- γ release test.

In the first experiment, 14 randomly selected lambs were used. They were divided into 2 groups, each composed of 7 lambs: one was infected with the tissue homogenate inoculum (*homogenate group*) and the remaining were kept as uninfected negative controls.

As S-type strains of *Map* had a slow growth in culture, needing long periods of time to reach the amount required for infecting lambs, and in order to avoid freezing the tissue homogenate inoculum for a long period of time, the infection of lambs with cultured bacteria took place approximately 1 year after the beginning of the first study. In this experiment, a new group of 7 Churra lambs coming from the same flock and born to the same ewes employed in the previous study was infected with the pure culture inoculum (*culture group*). All the experimental procedures were carried out in the same season of the year and in the same experimental facilities where the lambs, after a period of adaptation, were

allocated to separate pens. The animals were fed grass hay *ad libitum* and a conventional compound feed appropriate for each age.

Each experimentally infected lamb was orally challenged using an automatic syringe, with a total dose of 40 ml of the respective inoculum, administered in 4 doses of 10 ml given at 3-day intervals. Lambs from the control group were challenged with saline solution.

Blood samples were collected from the jugular vein into 10 ml evacuated tubes (Vacutainer®, Becton Dickinson, Plymouth, UK) containing lithium heparin or without anticoagulant for IFN- γ and antibody (Ab) determination studies respectively. Blood samples were taken at monthly intervals from day 0 up to 240 dpi.

On day 120 after infection, three lambs from each group were humanely culled, after sedation with xylazine (Rompun®, Bayer Animal Health, Mannheim, Germany), by an intravenous overdose of embutramide and mebezonium iodide (T61®, Intervet, Salamanca, Spain), followed by immediate exsanguination. The remaining animals were killed at 240 days post-infection (dpi).

2.3. Cell mediated immune response determination

2.3.1. Single intradermal skin test (IDT)

One month before euthanasia (90 and 210 dpi), 0.1 ml of an avian protein derivative (PPD) antigen (CZ Veterinaria, Porriño, Spain), at a concentration of 0.5 mg/ml, was injected intradermally in the skin fold of the tail. Skin-fold thickness was measured at the injection site with callipers before injection and 72 h later. Results were expressed as the increase in mm of skin thickness. For diagnostic purposes, an animal was considered positive when the increase was ≥ 2 mm (Pérez et al., 1999).

2.3.2. Interferon- γ (IFN- γ) release assay (IGRA)

Two separate aliquots of 1.5 ml from the whole blood sample taken into heparinized tubes were mixed in a laminar flow hood with either 100 μ l of sterile PBS (negative control) or avian PPD (CZ Veterinaria, Porriño, Spain) at a final concentration of 30 μ l/ml, within 3 h from the time of collection. Blood cultures were incubated for 20 h at 37 °C in a humidified chamber and, after centrifugation, the plasma supernatant was removed and kept at -20 °C until required. Plasma samples were assayed in duplicate for IFN- γ determination using a commercial immunoassay kit (BOVIGAM®, Prionics AG, Switzerland). In order to avoid inter-plate variations, all the optical density (O.D.) values were adjusted by dividing the sample O.D. minus the negative control O.D., by the positive control O.D. minus the negative control O.D., from each plate. Once the raw values were standardized, results were expressed as a quotient between the mean O.D. of the avian PPD-stimulated plasma and the O.D. of the same plasma incubated with PBS.

2.4. Humoral immune response determination by indirect ELISA (Ab ELISA)

Blood samples without anticoagulant were allowed to clot and the serum was removed and frozen at -20 °C until required. The production of Ab against *Map* was assessed by an in-house indirect ELISA (Fernández et al., 2014) using the PPA-3 protoplasmic antigen of *Map* (Allied Monitor Inc, Fayette, MO) and a horseradish peroxidase conjugated to protein G (BioRad, Hercules, USA). The results were expressed as a quotient between the mean O.D. of each sample sera and the mean O.D. of the positive control serum in each plate.

2.5. Pathological studies and granuloma count

Complete necropsies were performed on all the experimental animals. Samples for histological examination were taken from the ileocecal valve (ICV), ileum (IL) (three 5-cm samples, taken 20, 40

and 60 cm from the ICV), jejunum (JJ) and jejunal Peyer's patches (JPP) (at least 3 patches from each of the proximal, mid and distal zones), the caudal mesenteric lymph node (MLN), one jejunal lymph node (JLN), and ileocecal lymph nodes (ILN). All tissues were fixed in 10% neutral buffered formalin, dehydrated through a graded alcohol series before being embedded in paraffin wax. Sections, 4 μ m thick, were stained with hematoxylin and eosin (HE) and by the Ziehl-Neelsen (ZN) technique for AFB and examined by light microscopy for histological changes. The presence of *Map* antigens in the tissue sections showing histological lesions was assessed immunohistochemically using a specific rabbit anti-*Map* serum, as described elsewhere (Delgado et al., 2013). The amount of AFB and *Map* antigens in the lesions was subjectively scored into 5 categories: 0 (no AFB or *Map* antigens), +/- (doubtful presence of bacteria), + (solitary or very few bacteria), ++ (moderate amount of AFB or antigens), +++ (large amount of AFB or *Map* antigens in the cytoplasm of macrophages).

All the lesions consistent with paratuberculosis infection observed in the examined samples were classified following the guidelines previously proposed (Delgado et al., 2013; Pérez et al., 1996) for ovine species, according to the distribution and location of the granulomata in the different intestinal compartments.

After histopathological examination, the number of granulomata per tissue was quantified, as previously reported (Delgado et al., 2013; Fernández et al., 2014). Briefly, three tissue sections from each different intestinal sites and 2 sections from each lymph node, with approximately the same area, were assessed blindly and the mean number of granulomata per tissue section in each site was recorded by the same observer (MF), distinguishing those granulomata located in the lymphoid tissue (LT) from those in the associated lamina propria (LP) or in the mucosa unrelated to LT.

2.6. Tissue culture

Bacterial isolation was performed on tissue samples from the ICV, a 5-cm sample of the distal ileum (dIL), mid jejunum Peyer's patch (mJPP) and caudal MLN. Two grams of tissues was processed for culture onto two tubes containing Middlebrook 7H11 solid medium (Difco, MD, USA) supplemented with OADC (BD, MD, USA) and also two Löwenstein-Jensen tubes (Difco, MD, USA). Both media were supplemented with mycobactin J (Allied Monitor Inc, Fayette, MO) and with penicillin, chloramphenicol, and amphotericin B (Sigma-Aldrich, Madrid, Spain). The tubes were incubated at 37 °C and growth was monitored under stereoscopic light microscopy every 2 months until 10 months post-inoculation. When a colony was detected, a smear was made and stained by the ZN method for AFB and confirmed by PCR to be IS900 positive (Garrido et al., 2000).

2.7. Nested-PCR

A nested PCR for the detection of *Map* DNA was performed on tissue samples adjacent to those taken from bacteriological culture from the ICV, dIL, mJPP and MLN. DNA was isolated from 0.5 g of each tissue sample, using Speedtools Tissue DNA extraction kit following the manufacturer instructions (Biotools® B&M Labs SA, Madrid, Spain), and the resultant DNA samples frozen at -20 °C until analysis was performed. The nested PCR was carried out as described previously (Delgado et al., 2013), using primers to detect the presence of *Map*-specific IS900 DNA.

2.8. Statistical analysis

Data from IFN- γ , Ab production and granuloma count were subjected to analysis of variance using the general linear model procedure (GLM) of the SAS statistical package (version 9.1; SAS Institute, Cary, NC, USA). The results were logarithmically transformed

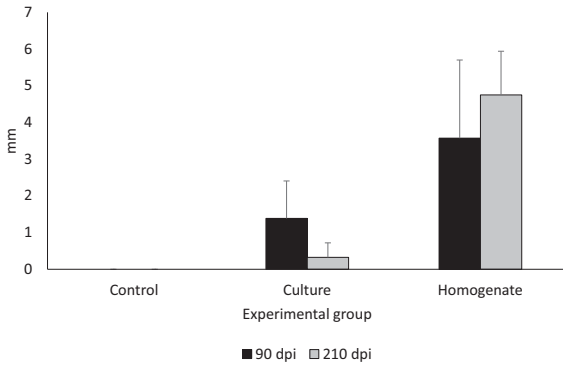


Fig. 1. Response to intradermal skin test (IDT). The results are expressed as the skin-fold thickness increase (in mm) after intradermal injection of avian PPD at 90 and 210 dpi in the three experimental groups. Error bars: standard deviation.

to enable them to be submitted to normal distribution-based tests of significance. Differences among experimental groups at each time of sampling were evaluated using Student's *t*-test for pair-wise comparisons with the Tukey–Kramer method correction, at the 95% significance level. The results of the IDT and the culture and PCR-positive frequencies were compared and tested for significance by chi-squared analysis.

3. Results

No clinical signs related to *Map* infection were detected in any of the challenged lambs.

3.1. Peripheral immune response

Figure 1 shows the results of the IDT test. An increase in skin thickness was seen in both infected groups, but the response was higher in lambs from the homogenate group ($p < 0.05$) at both tests. While there was no significant difference in the response between lambs from the homogenate group tested at 90 and 210 dpi, there was a significant decrease ($p < 0.05$) in the skin thickness of lambs from culture group between 90 and 210 dpi. The mean of increase in the skin thickness in this latter group did not reach the value considered as positive (2 mm).

The kinetics of IFN- γ production by blood cells in the different groups is represented in Fig. 2. A significant increase ($p < 0.05$) with respect to the other two groups was observed in lambs from the homogenate group from 90 dpi until the end of the experiment. However, no differences were seen between culture and control groups except for lambs tested at 90 dpi ($p < 0.05$).

The serology is shown in Fig. 3. Significant differences were seen only between the homogenate and the rest of the groups from 120 dpi until the end of the experiment ($p < 0.05$).

3.2. Pathological findings

No clinical sign or gross lesions related to paratuberculosis were seen in any lamb during the experiment. When examined microscopically, granulomatous lesions consistent with *Map* infection were found in the seven lambs from homogenate group but only in four animals from the culture group. Moreover, differences were observed in the extension and type of lesion between both groups and time of culling. No microscopic lesions were detected in the control group.

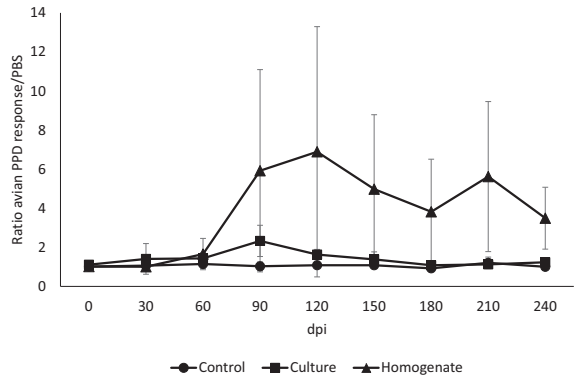


Fig. 2. Kinetics of the specific IFN- γ production by peripheral blood cells stimulated with avian PPD in the three experimental groups throughout the experiment. Error bars: standard deviation.

Lesions in lambs from the culture group (Table 1) were categorized as *focal*. They were composed of small, well-defined granulomata formed by groups of 10–40 macrophages that appeared exclusively in the interfollicular area of the intestinal LT or lymph nodes, without disturbing the normal architecture of the organ. These lesions appeared in two out of three lambs (66.6%) culled at 120 dpi and in two of the four animals (50%) examined at 240 dpi.

In contrast, lesions in lambs from the homogenate group (Table 2) were more severe. In two lambs (culled at 120 and 240 dpi) lesions were classified as *multifocal a*. They were formed by granulomata located in the LT, similar to those seen in the culture group but more abundant and, in addition to that, small granulomata were also present in the LP of the mucosa associated with the LT. Four lambs (two of each examined at both times of culling) showed lesions categorized as *multifocal b*. In these animals, granulomatous lesions were similar to those already described in the LT and related LP but also extended to areas of the intestinal LP not associated with LT, where they caused separation of the intestinal glands and enlargement of the villi. Granulomata were also present in the lymph nodes in higher numbers than in the previous types of lesion. The remaining lamb (culled at 240 dpi) showed a focal form. The number of AFB detected by ZN varied from hardly any in *focal* lesions to abundant in some granulomata located in the LP in lambs with *multifocal*

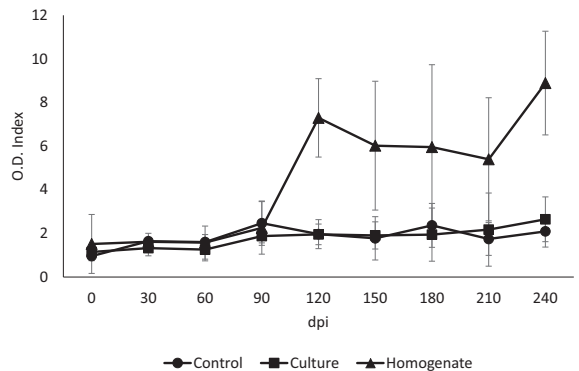


Fig. 3. Kinetics of antibody production of the three experimental groups throughout the experiment. Error bars: standard deviation.

Table 1

Distribution of lambs from the culture group according to lesion type, number of granulomata, presence of acid-fast bacilli in the tissues and result of microbiological culture and nested-PCR.

Time of culling	Lamb ID	Type of lesion ^a	Total no of granulomata	ZN ^b	IHC ^b	Culture ^c	Nested PCR ^c
120 dpi	23	F	11	0	0	Neg	JPP, LN
120 dpi	24	Neg	0	0	0	Neg	Neg
120 dpi	21	F	10	+/-	+	Neg	ICV, JPP
240 dpi	22	Neg	0	0	0	Neg	Neg
240 dpi	25	F	3	0	0	Neg	Neg
240 dpi	26	Neg	0	0	0	Neg	LN
240 dpi	27	F	6	0	+/-	Neg	JPP

^a F, focal; Neg, no lesion.

^b Intensity of staining, from 0 (no staining) to +++ (high amount of acid-fast bacilli or *Map* antigens in the cytoplasm of the macrophages).

^c Neg: negative. Tissue sample with positive result: ICV, ileocecal valve; JPP, jejunal Peyer's patch; LN, mesenteric lymph node.

ID: identification.

dpi: days post-infection.

ZN: Ziehl–Neelsen technique.

IHC: Immunohistochemistry for *Map* antigens detection.

b lesions (Tables 1 and 2). No AFB or lesions consistent with *Map* infection were seen in the negative control lambs.

The mean number of granulomata per lamb is shown in Table 3. The number of granulomata was significantly higher ($p < 0.001$) in lambs from homogenate than culture group at both sampling time points. A significant decrease ($p < 0.05$) could also be observed in both groups between lambs culled at 120 and 240 dpi. The distribution of the lesions in each location examined in both challenged experimental groups is shown in Fig. 4. In lambs from the culture group (Fig. 4a), lesions were found exclusively in the ICV, the different JPP and LN, with no statistically significant differences between the locations. In spite of the presence of LT in all the samples examined from the ileum, no lesions were seen in this location. In all the sites, except for the mJPP and ICLN, a significant reduction in the number of granulomata ($p < 0.05$) was detected between lambs culled at 120 compared to 240 dpi. In lambs from the homogenate group (Fig. 4b) granulomatous lesions were seen in all the samples examined, including the ileum and areas of the jejunum without LT. Except for the pJPP and ICLN sites, no statistically significant differences were seen in the number of granulomata according to their location between lambs culled at 120 and 240 dpi. However, when considering the distribution of the lesions in the different intestinal compartments, regardless of the location (Fig. 5), a significant decrease ($p < 0.05$) was seen in the number of granulomata located in the LT and an increase in those seen in areas of LP not associated with LT ($p < 0.05$) between lambs culled at 120 and 240 dpi from the homogenate group.

3.3. *Map* detection in tissues by culture and nested PCR

The number and samples where *Map* could be isolated by culture or *Map* DNA could be demonstrated by nested PCR in the experimental animals is shown in Tables 1 and 2. In lambs from the culture group, no isolation was successful by culture while *Map* DNA was demonstrated in four out of the eight (50%) examined lambs. In three lambs from the homogenate group *Map* could be cultured, always in samples from the ICV (in two cases in the Löwenstein–Jensen and Middlebrook 7H11 tube respectively, and in the two media in the remaining animal). By nested PCR, *Map* DNA was detected in all the lambs of this group. No *Map* isolation or DNA detection was observed in lambs from the control group.

4. Discussion

Under the experimental conditions used in this study, a marked attenuation of the virulence of a low-passage cultured *Map* strain has been observed, when compared with the tissue homogenate from which it was isolated. Previous reports have shown that experimental infection with an inoculum obtained directly from the intestinal mucosa of diseased animals results in more rapid and severe forms of disease compared to inoculation of cultured bacteria (Begg et al., 2005; Stewart et al., 2004). These differences have not been so clearly seen in other studies (Begg et al., 2010). In all experiments mentioned earlier the gut tissue homogenate and cultured bacteria used for challenge originated from different flocks,

Table 2

Distribution of lambs from the homogenate group according to their type of lesion, number of granulomata, presence of acid-fast bacilli in the tissues and results of microbiological culture and nested-PCR.

Time of culling	LambID	Type of lesion ^a	Total no of granulomata	ZN ^b	IHC ^b	Culture ^c	Nested PCR ^c
120 dpi	47	Mfa	30	+	+	Neg	ICV
120 dpi	51	Mfb	1325	++	++	ICV	ICV, JPP
120 dpi	54	Mfb	165	++	+++	Neg	ICV, JPP, MLN
240 dpi	48	Mfb	484	+++	+++	ICV	ICV, JPP, MLN
240 dpi	49	Mfb	745	+	+	Neg	ICV, JPP, MLN
240 dpi	50	Mfa	49	+	+	ICV	ICV, JPP, MLN
240 dpi	52	F	36	0	+	Neg	ICV, MLN

^a F, focal; Mfa, multifocal a; Mfb, multifocal b.

^b Intensity of staining, from 0 (no staining) to +++ (high amount of acid-fast bacilli or *Map* antigens in the cytoplasm of the macrophages).

^c Neg: negative. Tissue sample with positive result: ICV, ileocecal valve; JPP, jejunal Peyer's patch; MLN, mesenteric lymph node.

ID: identification.

dpi: days post-infection.

ZN: Ziehl–Neelsen technique.

IHC: Immunohistochemistry for *Map* antigens detection.

Table 3

Mean number of granulomata per animal \pm standard deviation, in lambs from the culture and homogenate groups culled at 120 and 240 dpi.

	Culture	Homogenate
120 dpi	6.98 (\pm 6.06)	506.59 (\pm 711.90)
240 dpi	2.22 (\pm 2.84)	328.41 (\pm 488.31)

dpi: days post-infection.

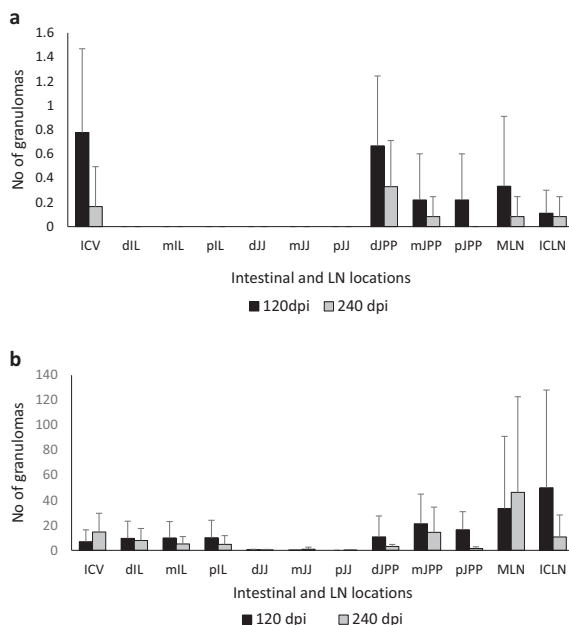


Fig. 4. Mean of the total number of granulomata per tissue section and animal according to their intestinal location in lambs from culture (a) and homogenate (b) groups, regardless of the time of sampling. ICV, ileocecal valve; IL, ileum, JJ, jejunum; JPP, jejunal Peyer's patches; MLN, mesenteric lymph node; ILN, ileocecal lymph node. d, Distal; m, mid; p, proximal. Error bars: standard deviation.

so it is possible that different strains of *Map* were used (Stewart et al., 2004). In this sense, the existence of differences in virulence between *Map* strains has been widely documented (Begg and Whittington, 2008; Fernández et al., 2014; Verna et al., 2007). However, this pos-

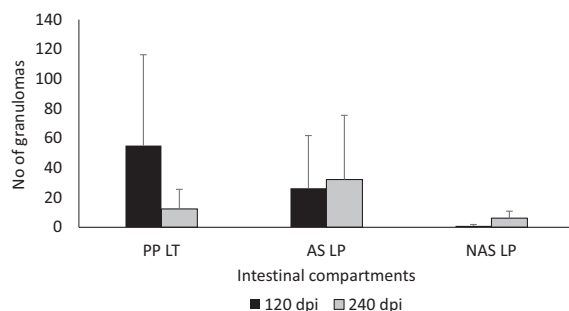


Fig. 5. Mean number of the granulomata per animal, in lambs from homogenate group, according to their location in the different intestinal compartments. PP LT, Peyer's patches lymphoid tissue; AS LP, lamina propria associated with Peyer's patches; NAS LP, lamina propria not associated with Peyer's patches. Error bars: standard deviation.

sibility is highly unlikely in this study as the same strain of *Map* was employed, as seen by the molecular typing techniques employed, either as a direct isolate from the tissue or after its passage by culture media. Although the complete absence of other *Map* strains in the tissue homogenate cannot be completely guaranteed, the bacteriological procedures employed were those recommended for the isolation of ovine *Map* strains (Adúriz et al., 1995; Hines II et al., 2007; Whittington et al., 2011).

Besides the individual strain virulence, other factors can also influence the outcome of experimental *Map* infection (Begg and Whittington, 2008; Hines II et al., 2007; Juste, 2012) such as the dose administered and the age or the genetic resistance of the experimental animals. It has been shown previously that there is a direct relationship between the dose administered and the outcome of the infection (Delgado et al., 2013; McGregor et al., 2012; Reddacliff and Whittington, 2003). In this study we have chosen an infectious dose that has been shown to be effective in previous studies (Begg and Whittington, 2008). Furthermore, despite the fact that the number of CFUs used to infect the culture group was slightly higher, the symptoms of infection were milder. Regarding the age, 1-month old lambs were used in both groups, when susceptibility to infection is high (Begg and Whittington, 2008; Delgado et al., 2013; McGregor et al., 2012).

Some of the conditions in which this study was performed should be taken into account when interpreting the results. The slow multiplication rate of S-type *Map* in strains in laboratory culture and the need to use fresh original tissue homogenate to avoid loss of bacterial viability after freezing forced to divide this experiment in two separate infections 1 year apart. Moreover, only a control group was employed in the first experiment, in order to minimize the number of experimental animals used. Although both experiments were performed in the same facilities, at the same season of the year and were carried out under the same management conditions, it cannot be completely discarded the influence of some other factors over the outcome of the infection, especially in the second experiment. On the other hand, the offspring from the same ewes and from the same flock was used in the two infections. Even though no detailed genetic analysis in relation to paratuberculosis resistance has been carried out in the lambs used in the experiment, it can be assumed that not substantial differences in the genetic background would be present among the experimental lambs.

Although bearing in mind all the considerations mentioned earlier, the most feasible hypothesis explaining the differences found in this study between the two experimental groups would be that culture in laboratory media resulted in changes in the *Map* isolate as used in the inoculum. Another possibility is that, in spite of the intense antibiotic and enzymatic treatments to which the tissue samples were exposed during the preparation of the homogenate inoculum, the potential presence of other microbial species, which theoretically might have interacted with *Map*, could have influenced the progression of the disease (Begg et al., 2010; Wu et al., 2007). In this sense, it has been proposed that impaired intestinal microbial homeostasis leads to an alteration of the permeability of tissue and the activation of specific intestine immunocompetent cells, leading to micro-environmental changes that provide the substrate for outbreaks of intestinal infections (Tomasello et al., 2011).

There are previous reports of different mycobacterial strains that show a loss of virulence after frequent *in vitro* passages (Rosseels and Huygen, 2008), associated with changes in the *Map* strain genotype (Bull et al., 2013; Kasnitz et al., 2013). Although in our study we used a low-passage inoculum, minimizing this possibility, it has been observed that the virulent factor *kdpC* gene of *Map* appears activated only in the samples directly obtained from an infected cow and not in cultured isolates (Wu et al., 2007). In this sense, it is not uncommon that bacteria, in particular slow growing organisms, switch off the expression of pathogenicity genes or discard large

pathogenicity plasmids, not needed for survival under *in vitro* conditions (DiRita et al., 2000; Zheng et al., 2008). A similar feature could have occurred in this experiment and further genetic analysis of the strains employed would be of interest. However, and not supporting this hypothesis, there is a wide range of experimental studies where a variety of cultured strains have been able to successfully reproduce the infection (Begg and Whittington, 2008; Hines II et al., 2007).

It is remarkably difficult to culture S-type strains in laboratory media (Adúriz et al., 1995; Whittington et al., 2011) and experimental infections employing these strains have shown a variety of results, from clinically evident (Begg et al., 2005, 2010; Stewart et al., 2004) or very mild (Begg et al., 2005; Fernández et al., 2014) infections to cases where no clear sign of infection was detected (Thorel et al., 1992). It is tempting to speculate that this difficulty in isolating S-type strains in laboratory media might contribute to selection of *Map* clones better adapted to growth *in vitro* rather than maintenance of *in vivo* virulence. This particularity of S-type strains could also explain why experimental infections with other types of *Map* strains have been more successful (Fernández et al., 2014; Hines II et al., 2007; Juste et al., 1994; Stabel and Robbe-Austerman, 2011; Stewart et al., 2004; Verna et al., 2007).

The presence of *Map* related lesions is considered as a good indicator of infection, since they reflect the host response to the infectious agent. The model employed in this study has already been validated for the evaluation of strain pathogenicity (Fernández et al., 2014). In our study, lambs from the homogenate group showed more severe lesions, both in number of granulomata and their distribution within several areas of the LP, thus following the progression model already described for the pathogenesis of paratuberculosis (Delgado et al., 2013; Juste et al., 1994; Kurade et al., 2004; Nisbet et al., 1962; Pérez et al., 1996). Conversely, only focal and scarce lesions were observed in the culture group. The lack of clinical signs in any of the infected lambs was consistent with the lesions found, not severe enough for developing evident clinical evidence or permanent bacterial shedding (Pérez et al., 1996). Focal lesions are considered as initial or latent lesions (Delgado et al., 2013; Fernández et al., 2014; Pérez et al., 1996) and would indicate that lambs from the culture group were able to control the infection better than those from the homogenate group. It has been stated that animals infected with *Map* mount a protective cell-mediated immune response early in the infection (Stabel, 2000). In our study, however, lambs from culture group with focal lesions showed a weak and inconstant peripheral cell-mediated immune response, as seen by IDT and IGRA results. This, although likely related to the challenge, cannot be discarded to be due to environmental factors. The absence of an evident cell-mediated immune response does not exclude the possibility of lambs having controlled the infection since in the work of Vázquez et al. (2013), a large number of cattle with focal lesions were negative to IGRA and, what is more, local immune responses mounted against *Map* infection in the intestine, crucial in the first contact with the bacteria, do not necessarily correspond to the peripheral immune responses (Charavaryamath et al., 2013). On the other hand, the marked cellular and humoral peripheral immune responses seen in lambs from the homogenate group support the hypothesis that peripheral responses are related to the extension of the lesions (Vázquez et al., 2013).

The pathology results of this study emphasize the role of intestinal LT in establishment of the initial lesions associated with *Map* infection (Delgado et al., 2013; Fernández et al., 2014; Juste et al., 1994; Kurade et al., 2004; Nisbet et al., 1962) and that significant differences between ileal and ileocecal/jejunal Peyer's patches occur as lesions appear in the former only when lesions are widespread. This finding could be a reflection of the functional differences described between both lymphoid tissue sites (Mutwiri et al., 1999).

In spite of the extension of the lesions and the identification of AFB in the tissue sections, *Map* isolation was achieved only in 3 out of 8 lambs from the homogenate group, and always in the ICV sample. According to this result, the absence of positive cultures in tissues from the culture group was not a surprise. These findings agree with the already mentioned difficulty of culturing S-type strains (Whittington et al., 2011). In contrast, infection was confirmed by nested PCR in all the lambs from homogenate group and in three from the culture group. These results support the higher sensitivity reported for nested PCR in comparison with culture (Bull et al., 2003; Delgado et al., 2013) and confirm the existence of tissue infection in both groups. However, it has to be taken into account that the PCR method identifies DNA that could have originated from non-viable and/or degraded bacilli originally present in the inocula. Except for one lamb from the culture group that gave a positive PCR result, the rest of the animals also showed histological lesions, supporting the hypothesis that an infection was established but lambs were able to control *Map* infection at least during the time of the experiment.

5. Conclusions

This study has shown the occurrence of differences in the severity of *Map* infection, as determined by pathological, microbiological and immunological parameters, after experimental oral challenge of lambs with an inoculum derived from a tissue homogenate prepared from an ovine clinical case and the isolated *Map* strain obtained after the culture of the aforementioned inoculum in laboratory media. According to these results, marked attenuation of the virulence can occur after *in vitro* culture of the *Map* strain present in the homogenate. Thus, when experimental reproduction of ovine *Map* infection is necessary for pathogenesis, vaccine, treatment efficacy or other studies, the use of intestinal tissue homogenates as inoculum is more efficient despite the disadvantages inherent to this procedure. If these disadvantages are to be overcome, the isolation of new low-passage S-type *Map* strains with the appropriate degree of pathogenicity, although probably still lower than the tissues from which they were isolated, and capable of reproducing the disease in experimentally challenged lambs, should be recommended.

Acknowledgements

This work was supported by grants AGL2009-05820-C02 and AGL2012-39818-C02-01 from the Spanish Ministry of Economy and Competitiveness. The authors wish to thank all the staff of the IGM (CSIC-ULE) responsible for handling the experimental animals. The technical support of S. Morales is acknowledged. M. Fernández and M. Royo are funded by a predoctoral contract from the "Junta de Castilla y León" and Spanish Ministry of Economy and Competitiveness, respectively. J. Benavides was supported by CSIC through the JAE-Doc program, financed in part by European Social Fund (ESF). The authors are in deep gratitude to Dr. M. Dagleish (Moredun Research Institute, Scotland, UK) for proof reading and constructive criticism of this work.

References

- Adúriz, J.J., Juste, R.A., Cortabarría, N., 1995. Lack of mycobactin dependence of mycobacteria isolated on Middlebrook 7H11 from clinical cases of ovine paratuberculosis. *Veterinary Microbiology* 45, 211–217.
- Begg, D.J., Whittington, J., 2008. Experimental animal infection models for Johne's disease, an infectious enteropathy caused by *Mycobacterium avium* subsp. *paratuberculosis*. *Veterinary Microbiology* 176, 129–145.
- Begg, D.J., O'Brien, R., Mackintosh, C.G., Griffin, F.T., 2005. Experimental infection model for Johne's disease in sheep. *Infection and Immunity* 73, 5603–5611.

- Begg, D.J., de Silva, K., Di Fiore, L., Taylor, D.L., Bower, K., Zhong, L., et al., 2010. Experimental infection model for Johne's disease using a lyophilised, pure culture, seedstock of *Mycobacterium avium* subspecies *paratuberculosis*. *Veterinary Microbiology* 141, 301–311.
- Bull, T.J., McMinn, E.J., Sidi-Boumedine, K., Skull, A., Durkin, D., Neild, P., et al., 2003. Detection and verification of *Mycobacterium avium* subspecies *paratuberculosis* in fresh ileocolonic mucosal biopsy specimens from individual with and without Crohn's disease. *Journal of Clinical Microbiology* 41, 2915–2923.
- Bull, T.J., Schock, A., Sharp, J.M., Greene, M., McKendrick, I.J., Sales, J., et al., 2013. Genomic variations associated with attenuation in *Mycobacterium avium* subspecies *paratuberculosis* vaccine strains. *BMC Microbiology* 13, 11.
- Charavaryamath, C., Gonzalez-Cano, P., Fries, P., Gomis, S., Doig, K., Scruten, E., et al., 2013. Host responses to persistent *Mycobacterium avium* subspecies *paratuberculosis* infection in surgically isolated bovine ileal segments. *Clinical and Vaccine Immunology* 20, 156–165.
- Collins, D.M., Gabric, D.M., de Lisle, G.W., 1990. Identification of two groups of *Mycobacterium paratuberculosis* strains by restriction analysis and DNA hybridization. *Journal of Clinical Microbiology* 28, 1591–1596.
- Delgado, L., García Marín, J.F., Muñoz, M., Benavides, J., Juste, R.A., García-Pariente, C., et al., 2013. Pathological findings in young and adult sheep following experimental infection with 2 different doses of *Mycobacterium avium* subspecies *paratuberculosis*. *Veterinary Pathology* 50, 857–866.
- DiRita, V.J., Engleberg, N.C., Heath, A., Miller, A., Crawford, J.A., Yu, R., 2000. Virulence gene regulation inside and outside. *Philosophical Transactions of the Royal Society of London. Series B, Biological Sciences* 355, 657–665.
- Fernández, M., Benavides, J., Sevilla, I.A., Fuentes, M., Castaño, P., Delgado, L., et al., 2014. Experimental infection of lambs with C and S-type strains of *Mycobacterium avium* subspecies *paratuberculosis*: immunological and pathological findings. *Veterinary Research* 45, 5.
- Garrido, J.M., Cortabarría, N., Oguiza, J.A., Aduriz, G., Juste, R.A., 2000. Use of a PCR method on fecal samples for diagnosis of sheep paratuberculosis. *Veterinary Microbiology* 77, 379–386.
- Hines, M.E., II, Stabel, J.R., Sweeney, R.W., Griffin, F., Talaat, A.E., Bakker, D., et al., 2007. Experimental challenge models for Johne's disease: a review and proposed international guidelines. *Veterinary Microbiology* 122, 197–222.
- Hughes, J.B., Hellmann, J.J., Ricketts, T.H., Bohannon, B.J., 2001. Counting the uncountable: statistical approaches to estimating microbial diversity. *Applied and Environmental Microbiology* 67, 4399–4406.
- Juste, R.A., 2012. Slow infection control by vaccination: paratuberculosis. *Veterinary Immunology and Immunopathology* 148, 190–196.
- Juste, R.A., García Marín, J.F., Peris, B., Sáez de Ocariz, C., Badiola, J.J., 1994. Experimental infection of vaccinated and non-vaccinated lambs with *Mycobacterium paratuberculosis*. *Journal of Comparative Pathology* 110, 185–194.
- Kasnitz, N., Köhler, H., Weigoldt, M., Gerlach, G.F., Möbius, P., 2013. Stability of genotyping target sequences of *Mycobacterium avium* subspecies *paratuberculosis* upon cultivation on different media, *in vitro*- and *in vivo* passage, and natural infection. *Veterinary Microbiology* 167, 573–583.
- Kurade, N.P., Tripathi, B.N., Rajukumar, K., Parihar, N.S., 2004. Sequential development of histologic lesions and their relationship with bacterial isolation, fecal shedding and immune responses during progressive stages of experimental infection of lambs with *Mycobacterium avium* subspecies *paratuberculosis*. *Veterinary Pathology* 41, 378–387.
- McGregor, H., Dhand, N.K., Dhungyel, O.P., Whittington, R.J., 2012. Transmission of *Mycobacterium avium* subspecies *paratuberculosis*: dose-response and age-based susceptibility in a sheep model. *Preventive Veterinary Medicine* 107, 76–84.
- Mutwiri, G., Watts, T., Lew, L., Beskorwayne, T., Papp, Z., Baca-Estrada, M.E., et al., 1999. Ileal and jejunal Peyer's patches play distinct roles in mucosal immunity of sheep. *Immunology* 97, 455–461.
- Nisbet, D.I., Gilmour, N.J.L., Brotherston, J.G., 1962. Quantitative studies of *Mycobacterium johnei* in tissues of sheep: III. Intestinal histopathology. *Journal of Comparative Pathology* 72, 80–91.
- Pérez, V., García Marín, J.F., Badiola, J.J., 1996. Description and classification of different types of lesion associated with natural paratuberculosis infection in sheep. *Journal of Comparative Pathology* 114, 107–122.
- Pérez, V., Tellechea, J., Corpa, J.M., Gutiérrez, M., García Marín, J.F., 1999. Relation between serologic response and pathologic findings in sheep with naturally acquired paratuberculosis. *American Journal of Veterinary Research* 60, 123–127.
- Ratnamohan, T.N., Spencer, T.L., 1986. A technique for the purification of *Mycobacterium paratuberculosis* from the ileal mucosa of infected cattle. *Australian Veterinary Journal* 63, 185–187.
- Reddacliff, L.A., Whittington, R.J., 2003. Experimental infection of weaner sheep with S strain *Mycobacterium avium* subspecies *paratuberculosis*. *Veterinary Microbiology* 96, 247–258.
- Rosseels, V., Huygen, K., 2008. Vaccination against paratuberculosis. *Expert Review of Vaccines* 7, 817–832.
- Sevilla, I., Singh, S.V., Garrido, J.M., Aduriz, G., Rodriguez, S., Geijo, M.V., et al., 2005. Molecular typing of *Mycobacterium avium* subspecies *paratuberculosis* strains from different hosts and regions. *Revue Scientifique and Technique de l'Office International des Epizooties* 24, 1061–1066.
- Sevilla, I., Garrido, J.M., Geijo, M.V., Juste, R.A., 2007. Pulse-field gel electrophoresis profile homogeneity of *Mycobacterium avium* subspecies *paratuberculosis* isolates from cattle and heterogeneity of those from sheep and goats. *BMC Microbiology* 7, 18.
- Stabel, J.R., 2000. *Transitions in immune responses to Mycobacterium avium paratuberculosis*. *Veterinary Microbiology* 77, 465–473.
- Stabel, J.R., Robbe-Austerman, S., 2011. Early immune markers associated with *Mycobacterium avium* subspecies *paratuberculosis* infection in a neonatal calf model. *Clinical and Vaccine Immunology* 18, 393–405.
- Stevenson, K., Hughes, V.M., de Juan, L., Inglis, N.F., Wright, F., Sharp, J.M., 2002. Molecular characterization of pigmented and nonpigmented isolates of *Mycobacterium avium* subspecies *paratuberculosis*. *Journal of Clinical Microbiology* 40, 1798–1804.
- Stewart, D.J., Vaughan, J.A., Stiles, P.L., Noske, P.J., Tizard, M.L.V., Prowse, S.J., et al., 2004. A long-term study in Merino sheep experimentally infected with *Mycobacterium avium* subspecies *paratuberculosis*. *Clinical disease, faecal culture and immunological studies*. *Veterinary Microbiology* 104, 165–178.
- Thorel, M.F., Vialard, J., Manfroni, F., Bernardot, J., Ostyn, A., Vancevelde, J., 1992. Paratuberculose expérimentale chez le mouton après inoculation par voie veineuse ou par voie orale: pouvoir pathogène et diagnostic biologique. *Annales de Recherche Vétérinaire* 23, 105–115.
- Tomasello, G., Bellavia, M., Palumbo, V.D., Gioviale, M.C., Damiani, P., Lo Monte, A.I., 2011. From gut microflora imbalance to mycobacteria infection: is there a relationship with chronic intestinal inflammatory diseases? *Annali Italiani Di Chirurgia* 82, 361–368.
- Vázquez, P., Garrido, J.M., Juste, R.A., 2013. Specific antibody and interferon-gamma responses associated with immunopathological forms of bovine paratuberculosis in slaughtered friesian cattle. *PLoS ONE* 8, e64568.
- Verna, A.E., García-Pariente, C., Muñoz, M., Moreno, O., García-Marín, J.F., Romano, M.I., et al., 2007. Variation in the immuno-pathological responses of lambs after experimental infection with different strains of *Mycobacterium avium* subspecies *paratuberculosis*. *Zoonoses Public Health* 54, 243–252.
- Whittington, R.J., Marsh, I.B., Saunders, V., Grant, I.R., Juste, R., Sevilla, I.A., et al., 2011. Culture phenotypes of genomically and geographically diverse *Mycobacterium avium* subspecies *paratuberculosis* isolates from different hosts. *Journal of Clinical Microbiology* 49, 1822–1830.
- Wu, C., Schmöller, S.K., Shin, S.J., Talaat, A.M., 2007. Defining the stressome of *Mycobacterium avium* subspecies *paratuberculosis* in vitro and in naturally infected cows. *Journal of Bacteriology* 189, 7877–7886.
- Zheng, H., Lu, L., Wang, B., Pu, S., Zhang, X., Zhu, G., et al., 2008. Genetic basis of virulence attenuation revealed by comparative genomic analysis of *Mycobacterium tuberculosis* strain H37Ra versus H37Rv. *PLoS ONE* 3, e2375.

Original Article

Macrophage Subsets Within Granulomatous Intestinal Lesions in Bovine Paratuberculosis

Veterinary Pathology
1-12
© The Author(s) 2016
Reprints and permission:
sagepub.com/journalsPermissions.nav
DOI: 10.1177/0300985816653794
vet.sagepub.com



M. Fernández¹, J. Benavides¹, P. Castaño¹, N. Elguezabal²,
M. Fuertes¹, M. Muñoz¹, M. Royo¹, M. C. Ferreras¹, and V. Pérez¹

Abstract

Animals infected with *Mycobacterium avium* subspecies *paratuberculosis* show a variety of granulomatous lesions that range from focal forms, seen in the subclinical stages, to diffuse lesions associated with clinical signs. The aim of this study was to phenotypically characterize the macrophages present in the different lesion types using immunohistochemical methods. Lesions from a total of 23 animals with bovine paratuberculosis, natural and experimental, were examined by immunohistochemistry. Antibodies against inducible nitric oxide synthase (iNOS), tumor necrosis factor α (TNF- α), CD163, interleukin 10 (IL-10), transforming growth factor β (TGF- β), major histocompatibility complex (MHC) class II, natural resistance-associated macrophage protein 1 (Nramp-1), calprotectin, Ki-67, CD68, lysozyme, and ionized calcium-binding adaptor molecule 1 (Iba-1) molecules were employed. Samples were scored semiquantitatively using a complete histological score (H-score), reflecting the staining intensity and the percentage of immunolabeled macrophages. Differences in the H-score were seen depending on the lesion type. In focal lesions, with none or few acid-fast bacilli (AFB), macrophages were polarized toward M1 phenotype, with high H-scores for iNOS and TNF- α . Diffuse multibacillary lesions showed M2 differentiation, with high expression of CD163, IL-10, and TGF- β as well as Nramp-1 and MHC class II antigens. Macrophages in diffuse paucibacillary forms showed high H-scores for iNOS but low ones for TNF- α . Diffuse lesions, either multibacillary or paucibacillary, showed high calprotectin and low Ki-67 expression, suggesting a progressive character, while focal forms, with low H-scores for these antigens, would be consistent with latency. Lysozyme and CD68 expression were related to the amount of AFB. H-score for Iba-1 antibody was similar among all types. The findings of this study provide insights into the polarization status of macrophages and lesion development in bovine paratuberculosis.

Keywords

paratuberculosis, bovine, immunohistochemistry, granuloma, macrophage, M1, M2, polarization, Johne's disease

Paratuberculosis or Johne's disease is a chronic infection of domestic and wild ruminants caused by *Mycobacterium avium* subspecies *paratuberculosis* (Map). It is distributed worldwide and causes important economic losses to domestic livestock associated with chronic diarrhea and progressive loss of body condition.¹⁹ Despite its relevance, the pathogenesis of paratuberculosis is still poorly understood. Although transplacental infection or excretion of Map in the milk or colostrum has been demonstrated, the ingestion of Map-containing feces by young animals is the most important transmission route.¹⁹ As a consequence, infected animals can show different outcomes such as resistance to infection, development of latent infections that can last for an entire lifetime, or clinical disease that will appear only in the adulthood.^{19,58}

In Map-infected animals, a variety of granulomatous lesions can be detected, which have been classified according to the intensity, location, cellular types, and number of acid-fast bacilli (AFB).^{6,18,43} Although slight differences are observed

between species, 4 main types of lesions have been recognized, which are associated with different stages of the disease: *focal* forms, composed of small, well-demarcated granulomas located exclusively in the intestinal lymphoid tissue or lymph nodes, have been related to the initial phases of infection or to

¹Dpto de Sanidad Animal, Instituto de Ganadería de Montaña (CSIC-Universidad de León), Facultad de Veterinaria, Campus de Vegazana s/n, León, Spain

²Dpto de Sanidad Animal, NEIKER-Instituto Vasco de Investigación y Desarrollo Agrario, Derio, Bizkaia, Spain

Supplemental material for this article is available on the *Veterinary Pathology* website at <http://vet.sagepub.com/supplemental>.

Corresponding Author:

V. Pérez, Dpto de Sanidad Animal, Instituto de Ganadería de Montaña (CSIC-Universidad de León), Facultad de Veterinaria, Campus de Vegazana s/n. 24071. León, Spain.

Email: vperp@unileon.es

latent stages in adult animals.^{11,18} *Multifocal* forms, seen in subclinically infected animals, are characterized by the presence of small granulomas in the lymphoid tissue and also in the lamina propria either related to or not related to the Peyer's patches; the normal histological architecture of the intestine is not substantially modified.^{11,18} Animals with clinical signs usually show *diffuse* lesions, characterized by a widespread granulomatous enteritis, affecting both the lymphoid tissue and lamina propria causing the thickening of the intestinal wall.^{6,18,43} According to the cell types and amount of AFB, they have been classified as *multibacillary/histiocytic* forms, where epithelioid cells harboring large amounts of AFB are the main component, and as *paucibacillary/lymphocytic* lesions that are characterized by a diffuse infiltrate of lymphocytes in the lamina propria, with scattered granulomas formed by macrophages and giant cells containing none or low numbers of AFB.^{18,43}

The factors responsible for the development of the different pathological responses remain unclear. A relation between the immune response developed by the host and the type of lesion has been reported.^{44,56} Focal, multifocal, or diffuse paucibacillary lesions have been associated with high peripheral cellular immune responses, while in those animals with multibacillary lesions, a humoral response is predominant. However, in some cases, this polarization of forms is not so clearly defined.^{14,56,58}

Map infection occurs mainly through M cells of the Peyer's patches and, to a lesser extent, through differentiated epithelial cells.⁴⁹ After penetrating the intestinal epithelial barrier, Map invades the subepithelial macrophages that play a crucial role in the host-pathogen interaction.⁴⁹ Granulomatous lesions, composed mainly of macrophages, are the hallmark of paratuberculosis, constituting a complex environment where mycobacteria can inhibit the maturation and acidification of phagosomes and transform the potentially hostile macrophages into protected havens assuring their replication.^{49,55} There is still a lack of information regarding macrophage function or diversity within the granuloma in paratuberculosis. In addition, why some granulomas control bacterial growth while others permit it remains unknown. As a reflection of the complexity of these interactions, the existence of different myeloid cell populations that can interact with antigens and participate in the local immune response has been described in the intestine of cattle, with differences related to age or intestinal location.¹⁷

A common feature across different species is that macrophages are characterized by a remarkable diversity and plasticity and can acquire distinct functional phenotypes depending on polarization status.^{9,34,35,48} Traditionally, it has been considered that, in response to different signals, macrophages can be differentiated into 2 main types^{34,48}: M1 or classically activated which are characterized by a proinflammatory response and promotion of Th1 responses, and M2 or alternatively activated which are considered to have immunoregulatory functions involved in parasite containment and promotion of tissue remodeling. M1 macrophages are mainly

activated by interferon γ (IFN- γ), whereas M2 cells are activated by interleukin (IL) 4 or IL-10. They can be distinguished by the differential expression of diverse markers, such as inducible nitric oxide synthase (iNOS) or tumor necrosis factor α (TNF- α) for M1 macrophages or CD163, IL-10, or transforming growth factor β (TGF- β) for M2 macrophages.^{3,32,34} Pathology of different diseases has been associated with dynamic changes in macrophage activation.^{5,23,25,30,33,48} Most of the information regarding M1 and M2 polarization have been obtained from in vitro studies involving cultured macrophages^{23,25,35} that probably do not correlate with the complexity of the immune responses and the environment that take place in the in vivo developed granulomas.^{9,55} The study of macrophage polarization associated with lesion types has been assessed through the immunohistochemical labeling of different markers associated with M1 and M2 polarization in different diseases.^{3,23,25,33}

Concerning mycobacterial infections in human tuberculosis, it has been shown that M1 macrophages are associated with early stages of infection where they promote the formation of tuberculous granulomas and a protective response, while M2 macrophages are more typically associated with an advanced stage of the disease where host responses are less effective in controlling infection.^{23,33} In paratuberculosis, a recent study on blood monocytes from subclinically infected cattle has detected a heterogeneous macrophage activation pattern characterized by both classical and alternative phenotypes.⁵⁴

The main objective of this study was to carry out the phenotypical characterization of the macrophages present within the different granulomatous lesions associated with Map infection through immunohistochemical labeling of different markers related to macrophage biology. Particularly, the existence of different polarization status among the macrophages in the lesions was also evaluated.

Materials and Methods

Animals

A total of 23 female cattle were used in the study. Eight of them were calves experimentally infected with Map for other purposes.³⁷ Briefly, 4-month-old calves were orally challenged with a total dose of 6×10^{10} bacilli obtained directly from the intestinal mucosa of a clinically affected cow, which were purified and administered in 6 different doses given every 2 days. Two calves were culled at 120 days postinfection (dpi), and the remaining 6 animals at 270 dpi. Two additional uninfected, control cattle culled at 270 dpi were also examined as negative controls. All the animals were sedated with xylazine (Rompun; Bayer, Mannheim, Germany) and immediately euthanized by an intravenous overdose of embutamide and mebezonium iodide (T61; Intervet, Salamanca, Spain). The remaining 15 animals were naturally Map-infected cows that had been killed in a slaughterhouse by

standard authorized methods. They were unvaccinated Holstein cows coming from 2 different herds in whom a follow-up study on losses due to paratuberculosis was ongoing. Infection was confirmed by bacteriological culture of frozen tissues,¹⁸ serum indirect enzyme-linked immunosorbent assay,^{14,36} and IFN- γ release test,^{14,36} following the methodology detailed in the referred articles. Complete information on the animals and the results of the different tests are provided in Supplemental Table 1. The experimental procedures carried out in this study were performed in accordance with Spanish Royal Decree 1201/2005 for the protection of animals used for experimental and other scientific purposes and were approved by the “Instituto de Ganadería de Montaña CSIC-ULE” Animal Ethics Committee (Ref LE-B-12).

Tissue Samples

After necropsy or at the slaughterhouse, at least one sample from different areas of the intestine (ileocecal valve; distal, middle, or proximal ileum; and jejunum [with and without Peyer’s patches]; duodenum; and large intestine—including cecum, colon, and rectum) and ileocecal, ileal, and jejunal mesenteric lymph nodes was taken from each animal for histopathological examination. All samples were fixed in 10% buffered formalin for less than 48 hours and subsequently dehydrated through a graded alcohol series before being embedded in paraffin wax. Sections, 3.5 μm thick, were stained with hematoxylin and eosin and Ziehl-Neelsen method for AFB identification. A subjective classification of the sections was made according to the amount of AFB present, from 0 (no detectable bacilli), 1 (scant AFB in the cytoplasm of macrophages), 2 (moderate, easily detectable bacilli), to 3 (high load of AFB). Detailed information on the lesion type and AFB category present in each examined sample are provided in Supplemental Table 1. Granulomatous lesions were detected in different small intestine and lymph node samples. Only in 1 case, granulomas were seen in the cecum (Supplemental Table 1). Control cattle did not show any lesion consistent with Map infection.

Classification of Lesions

Lesions associated with Map infection were classified into 4 categories, according to the guidelines provided by González et al¹⁸: focal, multifocal, diffuse multibacillary, and diffuse paucibacillary. Each animal was classified based on the most severe lesion found in the examined samples, bearing in mind that the type of lesion could vary among the tissue samples obtained from the same individual (Supplemental Table 1).

Focal lesions were characterized by small, well-demarcated granulomas composed of 5–50 macrophages located exclusively in the interfollicular areas of the intestinal lymphoid tissue of the ileocecal valve or the isolated jejunal Peyer’s patches. They were also detected in the paracortical

area of the lymph nodes. Acid-fast bacilli were absent or detected in very low amounts in the cytoplasm of the macrophages (category 0 or 1).

Three experimentally infected calves and 2 naturally infected cows were classified as having focal lesions. In these animals, intestinal sections from 2 locations (ileocecal valve and jejunal Peyer’s patches) presented this type of lesion (Supplemental Table 1).

Sections containing multifocal lesions presented focal granulomas in the lymphoid tissue, as well as small and well-demarcated granulomas, formed by 5–25 macrophages and giant cells in the intestinal lamina propria related to the Peyer’s patches or in the lamina propria of villi not related to the lymphoid tissue. Granulomas were scanty and did not substantially modify the normal intestinal mucosa architecture. As in focal lesions, AFB were not detected or present in very low amounts (score 0 or 1).

A total of 6 animals (3 experimentally challenged calves and 3 adult cows) were classified under this category. In this group, this lesion was detected in 24 tissue sections of the intestine (Supplemental Table 1).

Diffuse lesions were characterized by the presence of a widespread granulomatous lymphadenitis and enteritis that altered significantly the normal intestinal architecture. The lesion was present in areas of the intestine both with and without lymphoid tissue. Large numbers of macrophages and occasional giant cells appeared in the interfollicular areas, infiltrating the lymphoid follicles. The lamina propria was markedly thickened and distended due to the presence of inflammatory cells. According to the cellular types and number of AFB, 2 types of diffuse forms were considered: diffuse multibacillary lesions, characterized by the predominance of macrophages morphologically consistent with epithelioid cells harboring large numbers of AFB (category 2 or more frequently 3) and diffuse paucibacillary lesions, wherein the infiltrate was composed mainly of lymphocytes, with some macrophages and giant cells, with occasional AFB (score 1) located among them.

Diffuse multibacillary lesions were identified in six animals (1 experimentally infected and 5 naturally infected) and diffuse paucibacillary forms in an other six (5 naturally and 1 experimentally infected cattle). Concerning tissue samples, diffuse multibacillary forms were identified in 30 intestine sections and diffuse paucibacillary forms in 29 samples (Supplemental Table 1). In all 12 cattle with diffuse lesions, grossly visible thickening of the intestinal wall of the ileum and jejunum and enlargement of the regional lymph nodes were seen in different degrees.

Immunohistochemistry

Immunohistochemical studies were performed in a total of 23 intestinal sections from different animals (Supplemental Table 1), showing the 4 main types of lesions considered (6 different samples from each lesion, except for the focal lesions where 5 samples were examined). Focal lesions were

evaluated in sections obtained from the jejunal Peyer's patches, whereas multifocal, diffuse multibacillary, and diffuse paucibacillary lesions were evaluated in tissue sections obtained from the middle ileum.

Different primary antibodies raised against antigens expressed by macrophages, including M1 and M2 subpopulations, and proliferation markers were used (Supplemental Table 2). Immunohistochemistry was performed using the Envision+ System (Dako, Agilent Technologies, Glostrup, Denmark) in 3.5- μ m-thick tissue sections that were placed onto poly-L-lysine-coated slides. After deparaffinization and hydration, endogenous peroxidase was blocked by immersion of the sections into a 3% H₂O₂ in methanol solution for 30 minutes in dark at room temperature. Rehydrated slides were rinsed twice in phosphate-buffered saline (PBS) of pH 7.4, and antigen retrieval methods using enzymatic or heat-based protocols, depending on the primary antibody, were used to optimize the immunoreaction as specified in Supplemental Table 2. Sections were incubated with the primary antibodies diluted in PBS (Supplemental Table 2) overnight at 4°C in a humidified chamber. After washing in PBS, sections were incubated for 40 minutes at room temperature with EnVision + horseradish peroxidase (HRP) solution (Dako, Agilent technologies) for the appropriate monoclonal or polyclonal antibodies. After washing in PBS, antibody localization was determined using 3,3'-diaminobenzidine (Sigma-Aldrich Corp., Madrid, Spain) as chromogenic substrate for peroxidase. Sections were counterstained with Mayer's hematoxylin for 10 seconds. Appropriate species- and isotype-matched immunoglobulins were used as negative controls. As positive controls, the same examined sections were used.

All the antibodies were tested in the 23 selected intestinal sections. A single antigen was examined per section. From each intestinal sample, serial sections were used for the sequential immunostaining of the antigens.

Evaluation of Immunostains

Some of the antibodies used (mainly those against TNF- α , IL-10, major histocompatibility complex [MHC] class II, and Ki-67 antigens) immunostained other cells apart from macrophages (mainly lymphocytes). Moreover, macrophages unrelated to the granulomas and present in the intestinal lamina propria were also positively immunolabeled with some of the antibodies. For this study, only those immunolabeled cells with a clear macrophage morphology (abundant cytoplasm and ovoid nucleus) that were forming part of the granulomas present in the different lesion types were considered and evaluated.

For staining comparison among tissues and types of lesion, samples were scored semiquantitatively using a complete H-score that considers both the staining intensity and the percentage of macrophages positively immunolabeled.¹² A total of 6 different slides (5 in the case of focal lesions) were evaluated for each type of lesion. In each slide, 5 randomly selected fields containing granulomatous lesions

were selected and photographed at 400 \times . In each individual sample, granulomas were evaluated regardless of their location in the lamina propria or lymphoid tissue (for multifocal and diffuse lesions). Cell counting and image analysis were performed using the Image J processing and analysis software (US National Institutes of Health, Bethesda, Maryland).

For each type of lesion, a complete H-score was calculated by adding the products of the percentage of cells (0-100) labeled at a given staining intensity present in each selected field and the staining intensity score (0, none; 1, weak; 2, moderate; and 3, intense). The H-score obtained in each random field can be placed in a range of values between 0 and 300.

The final H-score for each antibody and type of lesion was obtained considering the average value for the 5 areas counted and the 6 (or 5 for focal forms) sections examined.

Evaluation of macrophage immunostaining was performed independently by 2 pathologists (M.F., V.P.), and discordant results were reviewed with a multiheaded microscope to reach consensus.

Statistical Analysis

Immunohistochemical data (H-score) were analyzed for normality of distribution using Shapiro-Wilk and Kolmogorov-Smirnov tests. As data were not normally distributed and logarithmic transformation failed to correct skewness, they were analyzed with nonparametric methods of statistical analysis. The Kruskal-Wallis test was used to compare groups of lesions (focal, multifocal, diffuse multibacillary, and diffuse paucibacillary) for each antibody. The Mann-Whitney test was applied for post hoc comparison when significant differences were observed. A $P \leq .05$ was considered to indicate statistical significance. Correlation between AFB category and H-scores for the different antibodies was evaluated using Spearman test. All statistical analyses were performed with the use of statistical software SPSS version 21.0 (IBM Corp., Armonk, New York).

Results

Macrophages present in the 4 types of lesions considered were immunolabeled with the 12 tested antibodies showing differences in the intensity of the signal and the number of immunolabeled cells. Figure 1 shows the mean of the H-score obtained for each antibody according to the lesion category. Images corresponding to the patterns of immunostaining for the different antibodies and the main types of lesion are shown in Figs. 2-14 (focal), Figs. 15-27 (diffuse multibacillary), and Supplemental Figs. 1-13 (diffuse paucibacillary).

Histological score values for iNOS were significantly higher in focal lesions than in diffuse multibacillary ($P < .001$) or multifocal and diffuse paucibacillary forms ($P < .05$). No differences were observed between the last 2, both of them showing higher values than diffuse multibacillary

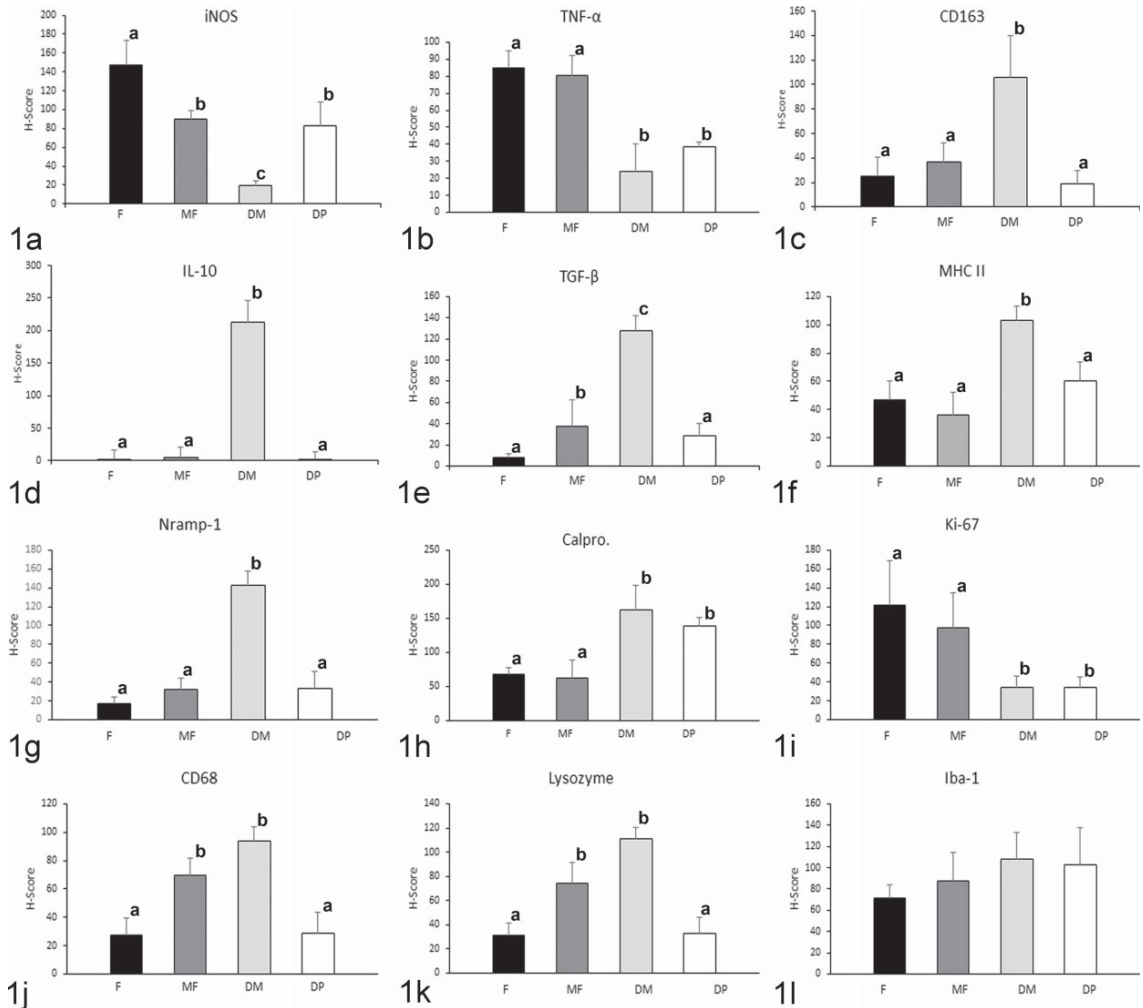


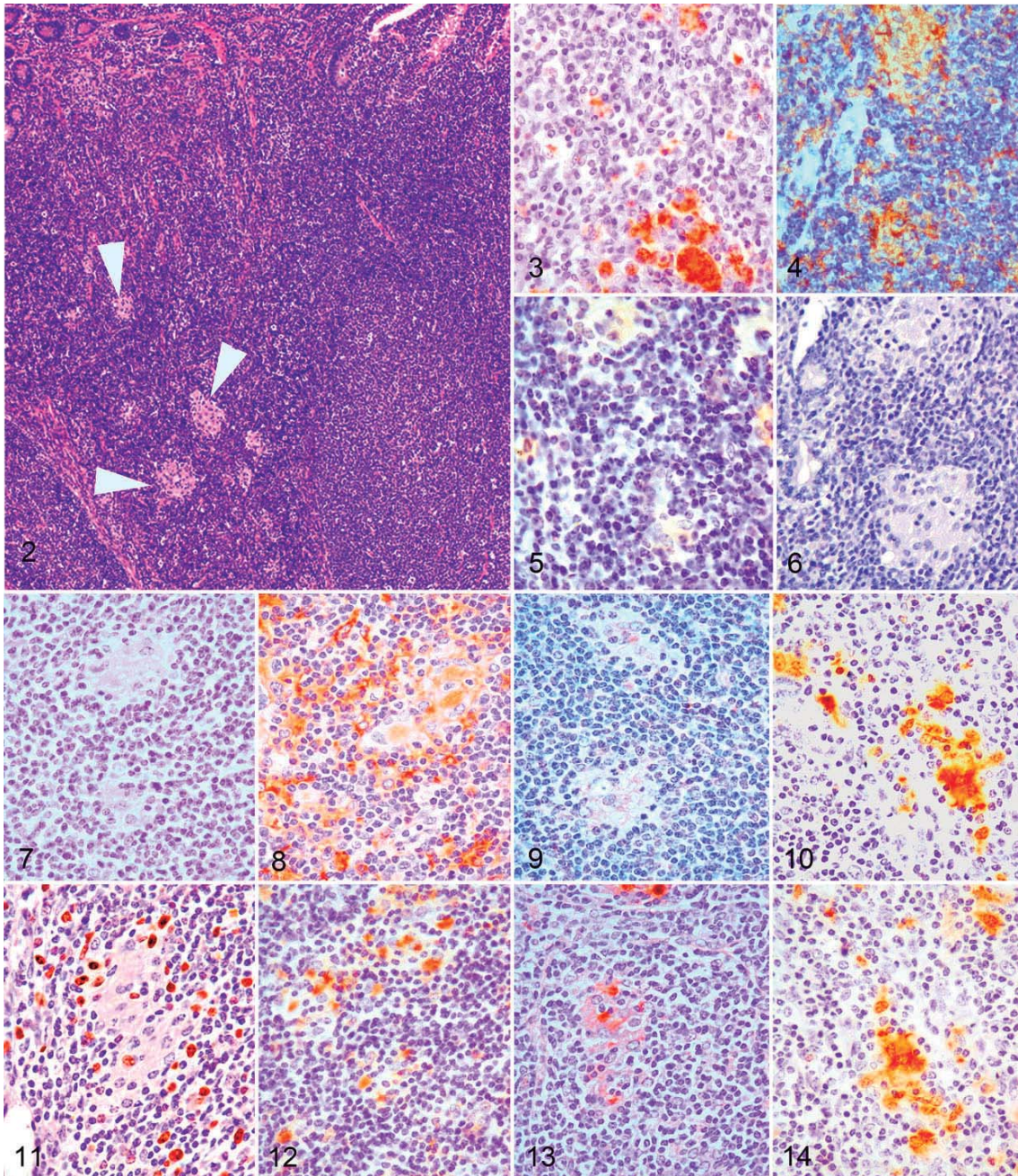
Figure 1. Mean histological score (H-score) for immunohistochemical staining according to the different lesion categories for (a) inducible oxide synthase (iNOS), (b) tumor necrosis factor- α (TNF- α), (c) CD163, (d) interleukin-10 (IL-10), (e) transforming growth factor- β (TGF- β), (f) MHC class II, (g) natural resistance macrophage protein 1 (Nrpam-1), (h) calprotectin, (i) Ki-67, (j) CD68, (k) lysozyme, and (l) ionized calcium binding adaptor molecule 1 (Iba-1) antibodies. DM indicates diffuse multibacillary; DP, diffuse paucibacillary; F, focal; MF, multifocal. Different superscript letters following the values indicate statistical significance ($P < .05$). Error bars indicate standard error of the mean.

forms. The lowest H-score values for this marker were found in diffuse multibacillary lesions. Expression of TNF- α was higher in focal and multifocal forms ($P < .05$) than in diffuse multibacillary or paucibacillary lesions, showing no differences between them.

The highest H-score values for CD163 and IL-10 antibodies were obtained in diffuse multibacillary lesions, with significant differences compared to the rest of the lesion types ($P < .001$). High H-scores were also obtained for TGF- β immunolabeling, although in this case differences were also

observed between focal and multifocal and diffuse paucibacillary type lesions ($P < .05$).

Immunohistochemical expression of MHC class II antigen, associated with antigen-presenting cells, was significantly higher in diffuse multibacillary lesions than in the rest of the forms ($P < .001$), where significant differences were not observed. Expression of natural resistance-associated macrophage protein 1 (Nrpam-1) was higher in diffuse multibacillary lesions than in the rest of forms ($P < .001$) exhibiting similar H-score values.



Figures 2–14. *Mycobacterium avium* subspecies *paratuberculosis* infection, focal lesion, jejunal Peyer's patches, cattle. **Figure 2.** Small and well-demarcated granulomas (arrowheads) in the interfollicular area of the lymphoid tissue. Hematoxylin and eosin. **Figure 3.** Inducible oxide synthase (iNOS) immunoperoxidase stain showing marked immunolabeling in macrophages forming the granulomas. **Figure 4.** Intense immunoreactivity for tumor necrosis factor α (TNF- α) antibody in the granulomas and in lymphocytes from the surrounding lymphoid tissue. **Figure 5.** Weak immunoperoxidase stain for CD163 in macrophages of the granulomas. **Figure 6.** Lack of interleukin

The intensity of immunostaining for calprotectin antibody was significantly lower in focal and multifocal forms than in diffuse lesions ($P < .001$), with no differences between both diffuse types. Histological scores for immunodetection of Ki-67 antigen, which marks nuclear proteins expressed in cells that are proliferating, were significantly lower in both types of diffuse lesions, that is, focal and multifocal forms ($P < .001$) that rendered the highest values.

CD68 and lysozyme antibody immunolabeling rated the highest H-score values in multifocal and diffuse multibacillary lesions in relation to focal and diffuse paucibacillary forms ($P < .05$) that showed similar levels. For ionized calcium-binding adaptor molecule 1 (Iba-1) antibody, no significant differences in the H-score values were observed among the different types of lesions.

Antibody Immunolabeling According to the Type of Lesion

Focal lesions showed high H-score values for iNOS, TNF- α , and Ki-67 antibodies, as observed in Figs. 1 and 2. A similar pattern was observed in multifocal lesions except for the immunolabeling of TGF- β , CD68, and lysozyme, which was higher. Diffuse multibacillary lesions showed high H-score values for CD163, IL-10, TGF- β , lysozyme, CD68, calprotectin, Nramp-1, and MHC class II antibodies, whereas iNOS and TNF- α immunolabeling was significantly lower. Diffuse paucibacillary lesion immunolabeling profiles were also similar to those of focal forms, except for the immunolabeling of TNF- α , calprotectin, and Ki-67 antibodies which showed a pattern similar to that presented by the diffuse multibacillary forms. High H-score values were observed for Iba-1 antibody in the 4 types of lesions, with no differences between them.

Correlation Between AFB Category and H-Scores for the Different Antibodies

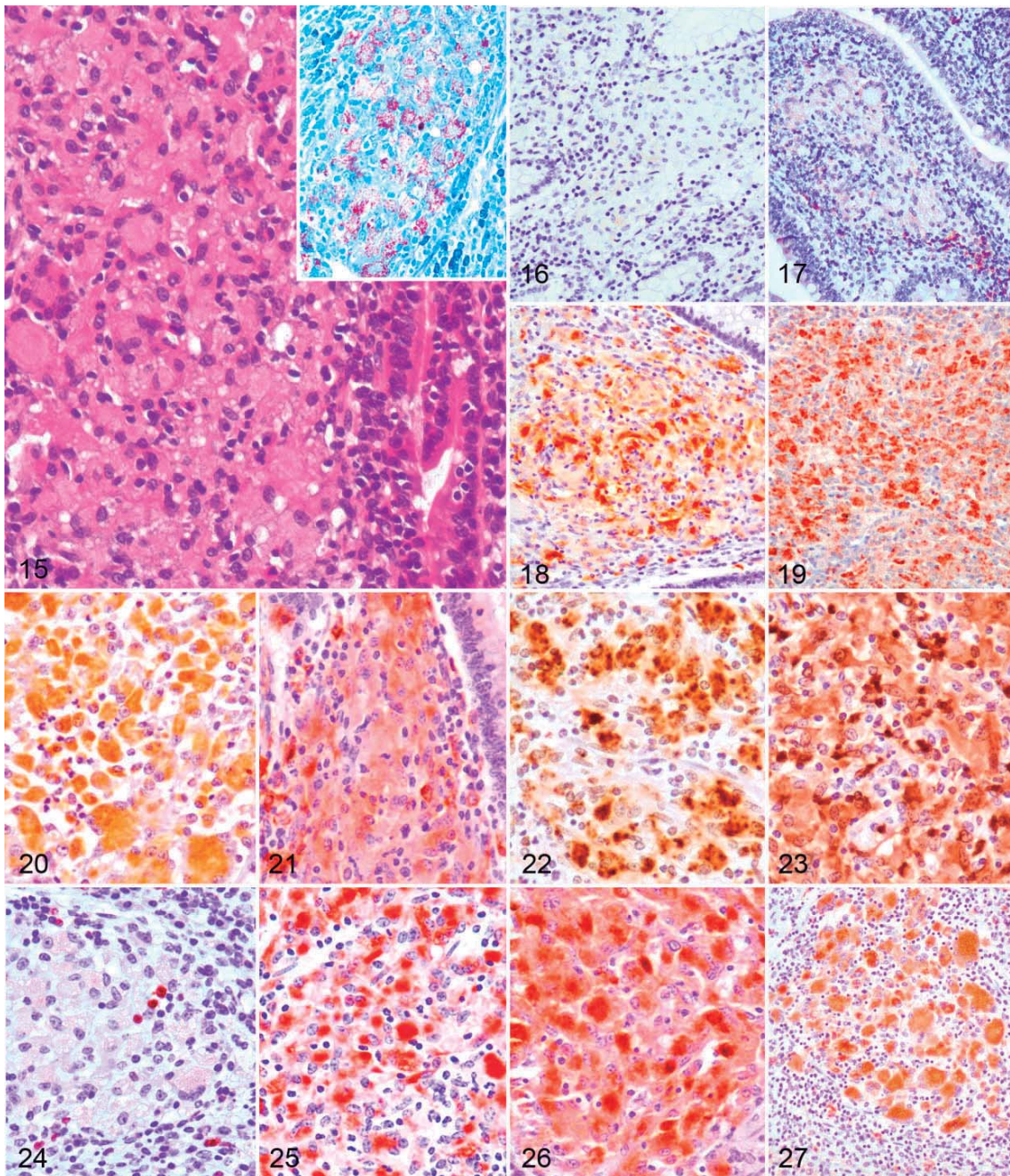
The amount of AFB present in the lesions was directly correlated with the H-score for the different antibodies used, with a variable statistical significance (between $P < .05$ and $P < .0001$) depending on the marker used (Supplemental Fig. 14). Histological scores for iNOS, TNF- α , and Ki-67 were negatively correlated with the amount of AFB, whereas a positive correlation was confirmed with the H-scores for the rest of the markers.

Discussion

As a consequence of Map infection, animals can develop morphologically distinct granulomatous lesions, from focal forms seen in the subclinical phase of the disease to diffuse lesions usually related to clinical signs.^{6,11,18} This study has shown that macrophages present in the granulomatous infiltrates show different immunohistochemical expression of the markers examined, as seen by the differences in the H-scores for several of these markers, depending on the lesion type. These differences can probably play different roles in their development. Considering this, the semiquantitative method used (H-score) has proven to be a useful tool to evaluate immunostaining, also enabling statistical comparison between these antibodies. Since it was initially proposed for the quantification of hormone receptors in neoplastic cells,¹² the H-score has been proven to be useful for the immunophenotypic characterization of different cell populations.⁸ However, this method has evident disadvantages such as only permitting a semiquantitative evaluation of biomarker production that cannot completely correlate with the real expression and the difficulty in assessing the immunostaining when it is not present in a single cell population.¹³

Depending on the polarization status, 2 different phenotypes of macrophages, named M1 and M2, have been recognized. Briefly, M1 or classically activated macrophages are involved in the response against intracellular pathogens throughout the secretion of proinflammatory cytokines and iNOS, whereas M2 or alternatively activated macrophages have immunoregulatory functions and play a role in tissue remodeling.^{25,32,34,48} Several of the molecules whose expression has been evaluated in this study are considered to be M1 (iNOS, TNF- α) or M2 (CD163, IL-10, or TGF- β) markers and have shown differential expression. The results of this study suggest that after Map infection, there is a modulation in the macrophage polarization toward proinflammatory and anti-inflammatory forms in the different types of lesions in such a way that in focal lesions, macrophages express markers related to M1 status, whereas in diffuse multibacillary lesions, M2 macrophages would predominate. Similar findings have been reported in *Mycobacterium tuberculosis* infection.^{23,33} In a recent study on paratuberculosis, a heterogeneous macrophage activation pattern was observed, characterized by both classical and alternative phenotypes⁵⁴; although in the same study, it was found that in animals with low peripheral IFN- γ responses, the proportion of monocytes expressing CD163 (an M2 marker) was higher, while they showed the lowest expression of iNOS (an M1 marker), in accordance with our results. In any case, that study was

Figure 6. (continued) I0 (IL-10)+ macrophages. **Figure 7.** Absence of transforming growth factor β (TGF- β) expression. **Figure 8.** Positive immunolabeling for MHC class II antibody in macrophages and other lymphoid tissue cells. **Figure 9.** Weak brownish immunoperoxidase stain for natural resistance macrophage protein 1 (Nramp-1) in macrophages. **Figure 10.** Calprotectin immunoperoxidase stain showing moderate immunolabeling in granuloma macrophages. **Figure 11.** Positive nuclear immunoreactivity for Ki-67 antibody in macrophages and lymphocytes. **Figure 12.** Weak immunoperoxidase stain for CD68+ macrophages. **Figure 13.** Moderate expression of lysozyme immunoperoxidase stain in macrophages. **Figure 14.** Positive immunolabeling for ionized calcium-binding adaptor molecule 1 (Iba-1) antibody in the macrophages.



Figures 15–27. *Mycobacterium avium* subspecies *paratuberculosis* infection, diffuse multibacillary lesion, ileum, cattle. **Figure 15.** Granulomatous infiltrate in the lamina propria composed mainly of macrophages together with some giant cells and low numbers of lymphocytes Hematoxylin and eosin. Inset: Macrophages contain large numbers of acid-fast bacilli. Ziehl-Neelsen. **Figure 16.** Weak immunoperoxidase staining for inducible oxide synthase (iNOS) in the granulomatous infiltrate. **Figure 17.** Tumor necrosis factor α (TNF- α) immunoperoxidase stain showing weak expression in macrophages. **Figure 18.** Strong immunoreactivity for CD163 antibody in macrophages. **Figure 19.** Interleukin 10 (IL-10)

conducted in blood monocytes from subclinically affected calves, where the lesions were not determined.

Macrophages in focal lesions that have been related to the subclinical stages of paratuberculosis, either to initial phases of Map infection or to latent stages,^{11,18,43} show an M1 phenotype associated with the absence or low numbers of AFB and the production of high levels of iNOS and TNF- α , a proinflammatory cytokine.^{32,34} A similar finding has been observed in the initial granulomas in *M. bovis* infection^{40,42} also with very low numbers or absence of bacilli and with a similar histological morphology of lesions. Moreover, IFN- γ and TNF- α are the main stimuli that will drive macrophages to an M1 phenotype.^{32,34} In this sense, focal lesions are associated with high levels of plasma IFN- γ production after lymphocyte stimulation.^{14,45,56} Tumor necrosis factor α has been shown previously to be produced by macrophages after infection with mycobacteria and it is considered, together with IFN- γ , as an endogenous cofactor in the induction of mycobacterial growth inhibition.¹⁵ Inducible nitric oxide synthase induces the production of nitric oxide (NO) that has reported to play a role in mycobacterial infections by supporting killing mechanisms within macrophages^{22,40} and has been related to the subclinical phases of paratuberculosis.²⁷ The expression of MHC class II, a molecule that plays a key role in antigen presentation, has also been previously observed in M1-polarized macrophages^{5,32} and in granulomas found in the initial phases of paratuberculosis in goats, with weaker intensity of labeling in those macrophages harboring low amounts of mycobacteria,^{29,55} as in this study. In this sense, *in vitro* studies have revealed that, shortly after mycobacterial infection, monocytes downregulate MHC class II expression.⁵⁷ Natural resistance-associated macrophage protein 1 has been linked to innate resistance to intracellular pathogens⁴ by reducing the susceptibility to phagosome rupture in macrophages infected with *M. tuberculosis*.⁵⁰ Since it is almost undetected in nonactivated macrophages,¹⁰ its presence in focal lesions could be linked to their ability to control Map multiplication, suggesting an activated state of macrophages in these lesions. All these findings suggest that focal lesions could be the reflection of highly protective stages that could last long periods of time (latency), where subclinically infected animals can control the growth of Map inside the M1-polarized macrophages, without developing a severe inflammatory response related to clinical signs.

Macrophages in diffuse multibacillary lesions exhibit an M2 profile, as seen by the high expression of CD163, IL-10, and TGF- β markers and the low levels of iNOS and TNF- α . CD163 has been widely considered an M2 marker,^{3,23,48} but some

studies have reported that it is not totally specific, and macrophage characterization should be done in combination with other markers.^{3,25} Following these suggestions, we explored CD163, IL-10, and TGF- β immunostaining, whose high expression has been recognized to be linked to an M2 phenotype,^{32,34} more precisely to the M2c category. In contrast to M2a macrophages, associated with allergy and killing and encapsulation of parasites,³² or M2b macrophages, related to a Th2 activation induced by IL-1,³² M2c macrophages induced by the presence of IL-10 and TGF- β ³² show a high immunoregulatory and anti-inflammatory activity^{32,34} and predominate in the late stages of tuberculosis infection, posing a risk of exacerbating the disease.³⁰ These mechanisms are probably operating in Map infection, since diffuse multibacillary lesions are detected in the late stages of the disease and are characterized by harboring large amounts of AFB, low numbers of other inflammatory cells rather than macrophages,^{6,18} and low expression of iNOS²² as in our case. These immunoregulatory actions are related to the production of TGF- β and IL-10 by macrophages that have been demonstrated to play a role in the downregulation of NO production.^{27,35} This scenario is consistent with the low levels of iNOS and TNF- α (a well-known proinflammatory cytokine) expression found in this type of lesions opposed to those found in focal forms. In paratuberculosis infection, upregulation of TGF- β and IL-10 has been reported in clinical cases during the late stages of the disease,^{1,27} which are highly expressed in macrophages harboring high numbers of Map,^{36,53} in agreement with our results. Expression of MHC class II was significantly higher in diffuse multibacillary lesions compared to the rest of the lesion types. In contrast to this finding, Navarro et al³⁸ did not find immunohistochemical expression of this marker in the cytoplasm of epithelioid cells associated with diffuse lesions and harboring AFB in goats. However, in agreement with the results of this study, Lybeck et al³¹ and Krüger et al²⁹ have also reported positive immunolabeling of MHC class II in macrophages from diffuse lesions and showing AFB in their cytoplasm, also in goats and using antibodies different to the one used in this work. A high level of Nramp-1 expression was also observed in these lesions, in the presence of abundant AFB, as it was noted previously by Delgado et al¹⁰ in paratuberculosis or by Pereira-Suárez et al⁴² for *M. bovis* infection. For these authors, the expression was interpreted as a reflection of mycobacterial infection, since they only examined lesions with remarkable numbers of AFB. In our study, the differential expression of Nramp-1 is also strongly related to the high numbers of AFB as seen in the multibacillary forms. Since this protein is located on

Figure 19. (continued) immunoperoxidase stain showing intense expression in macrophages. **Figure 20.** Marked macrophage immunolabeling for transforming growth factor β (TGF- β). **Figure 21.** Major histocompatibility complex (MHC) II immunoperoxidase stain showing intense immunolabeling in the inflammatory infiltrate. **Figure 22.** Strong immunoreactivity for natural resistance macrophage protein 1 (Nramp-1) antibody. **Figure 23.** Macrophages in the infiltrate are intensively immunolabeled for calprotectin antibody. **Figure 24.** Only few macrophages show positive immunolabeling for Ki-67 antibody in their nuclei. **Figure 25.** Marked immunoperoxidase stain for CD68+ macrophages. **Figure 26.** Lysozyme immunoperoxidase stain showing intense expression in macrophages. **Figure 27.** Macrophages in the infiltrate are positively immunolabeled for ionized calcium-binding adaptor molecule 1 (Iba-1) antibody.

the membrane of the macrophage-containing phagosomes,¹⁶ its higher level of expression would be linked to the higher number of these structures present in these cells as a consequence of harboring AFB. Its action in mycobacterial infections would be both to reduce phagosomal rupture⁵⁰ and to inhibit the capacity of mycobacteria to arrest phagosome maturation,¹⁶ hampering bacterial growth. In diffuse multibacillary lesions, however, these mechanisms would not be efficiently activated, despite high level of Nramp-1 expression, permitting Map intracellular growth and whose nature deserves further investigation.

In comparison with diffuse multibacillary lesions, macrophages in paucibacillary lesions would be mostly polarized toward an M1 type, as shown by high H-scores for iNOS and low scores for CD163, IL-10, and TGF- β .^{32,34} However, paucibacillary granulomas showed lower level of TNF- α expression compared to focal lesions. Similar findings have been reported previously,^{51,53} and these are probably related to the severe T-lymphocyte infiltration observed in paucibacillary lesions,^{38,51} which are not reported in focal forms. Supporting this, in human patients with Crohn's disease, a disorder in which Map has been proposed to play an etiological role, and where lesions similar to the diffuse paucibacillary forms reported in this study have been observed,²⁰ a downregulation of TNF- α has been found.⁷ It has already been pointed out that severe lesions of paratuberculosis are related to low TNF- α expression regardless of the amount of mycobacteria.¹ Further research is necessary to elucidate the mechanisms underlying these findings.

An interesting finding of this study is the difference between focal and diffuse lesions in the expression levels of calprotectin. Calprotectin is a major cytosolic protein complex present in monocytes that is expressed in tissue macrophages recently recruited from peripheral blood but whose expression is lost upon further differentiation.⁵² This fact together with the differences observed in the H-score for Ki-67 protein—a cellular marker for cell proliferation⁴⁷—leads to the hypothesis that a high number of macrophages forming granulomas in diffuse lesions would have been recently recruited from blood, while in focal forms, these would be multiplying in situ, supporting the latent character of this type of lesion and the active and progressive character of diffuse forms, seen in the advanced and uncontrolled cases of paratuberculosis.^{6,18} Supporting this, Valheim et al⁵⁵ also found a high number of macrophages expressing Ki-67 in granulomas from subclinically paratuberculosis-affected goats, and high levels of calprotectin in plasma have been associated with severe and active tuberculosis in humans.⁴¹ Opposed to this hypothesis, Jenkins et al²⁴ have pointed out that local macrophage proliferation is a signature of a Th2 inflammation. However, their study was conducted in pleural macrophages from rodents infected with a nematode, while Map is an intracellular pathogen affecting the intestine. Probably these facts together with the different methods used for macrophage evaluation in both studies could explain the different results. In any case, this hypothesis should be carefully considered, since lesions in

paratuberculosis can show a dynamic character,²⁸ as seen in this study by the coexistence of multifocal and diffuse lesions in the same animal and that in this work only one single time point has been evaluated.

Multifocal lesions, with a majority of M1-polarized macrophages showing high H-scores for iNOS and TNF- α ,^{32,34} could represent transient lesions between focal and diffuse forms. This is supported by the simultaneous higher expression of TGF- β and lower expression of calprotectin and Ki-67 compared to focal lesions. Thus, although there is a reduced Map multiplication and low numbers of new macrophages recruited from the blood, the increased expression of TGF- β could indicate that they are starting to progress to more severe and uncontrolled lesions.^{27,36}

CD68 and lysozyme have been widely used as general macrophage markers,^{2,29,43,46,55} which is in agreement with our findings, since they have been found in all the lesion types. However, their expression is shown to be positively correlated with the number of AFB, with the highest H-score levels observed in diffuse multibacillary lesions, as previously reported in paratuberculosis.^{2,22} The fact that CD68 antigen is located in lysosomal membranes, especially in phagolysosomes, and that lysozyme is also produced in the lysosomes²⁶ would explain why its expression is increased when the number of intracellular bacteria is high.^{21,46} A marked expression of Iba-1 has been found in all the lesion types with no differences in the H-score between them. This is a marker for a calcium-binding protein that has been considered to be specific for macrophages/microglia.³⁹ According to our results, it may be used as a general macrophage marker in granulomatous lesions.

According to the results of this study, the macrophages composing the granulomas associated with Map infection show differences in the expression of several proteins, reflecting changes in their functionality based on the type of lesion. M1-type macrophages will predominate in focal and multifocal forms, suggesting their latent character and the ability to control Map infection, and partially in diffuse paucibacillary lesions. M2 are the main type in diffuse multibacillary forms, with an immunoregulatory profile that would permit intracellular Map growth. The immunohistochemical analysis of macrophage subsets within Map infection-associated lesions has contributed to increased knowledge on the pathogenesis of this disease.

Acknowledgements

We acknowledge the excellent technical assistance of Gloria Belver, Carmen Espiniella, and María Jesús González. We also thank F. Javier Giraldez for his help with the statistical analysis.

Declaration of Conflicting Interests

The author(s) declared no potential conflict of interest with respect to the research, authorship and/or publication of this article.

Funding

The author(s) disclosed receipt of the following financial support for the research, authorship, and/or publication of this article: The study

was financially supported by grant AGL2012-39818-C02-01 of the Spanish Ministry of Economy and Competitiveness. M. Fernández and P. Castaño are the recipients of a predoctoral contract from the “Junta de Castilla y León,” partially funded by the European Social Found (European Union). J. Benavides and M. Royo are supported by a “Ramón y Cajal” and a “Predoctoral” contract of the Spanish Ministry of Economy and Competitiveness, respectively.

References

- Abendaño N, Juste RA, Alonso-Hearn M. Anti-inflammatory and antiapoptotic responses to infection: a common denominator of human and bovine macrophages infected with *Mycobacterium avium* subsp. *paratuberculosis*. *Biomed Res Int*. 2013;**2013**:908348.
- Ackermann MR, DeBey BM, Stabel TJ, et al. Distribution of anti-CD-68 (EBM11) immunoreactivity in formalin-fixed, paraffin-embedded bovine tissues. *Vet Pathol*. 1994;**31**(3):340–348.
- Barros MH, Hauck FM, Dreyer JH, et al. Macrophage polarisation: an immunohistochemical approach for identifying M1 and M2 macrophages. *PLoS One*. 2013;**8**(11):e80908.
- Barton CH, Biggs TE, Baker ST, et al. Nramp1: a link between intracellular iron transport and innate resistance to intracellular pathogens. *J Leuk Biol*. 1999;**66**(5):757–762.
- Benoit M, Desnues B, Mege JL. Macrophage polarization in bacterial infections. *J Immunol*. 2008;**181**(6):3733–3739.
- Buergelt CD, Hall C, McEntee K, et al. Pathological evaluation of paratuberculosis in naturally infected cattle. *Vet Pathol*. 1978;**15**(2):196–207.
- Campos N, Magro F, Castro AR, et al. Macrophages from IBD patients exhibit defective tumour necrosis factor- α secretion but otherwise normal or augmented pro-inflammatory responses to infection. *Immunobiology*. 2011;**216**(8):961–970.
- Charafe-Jauffret E, Tarpin C, Bardou VJ, et al. Immunophenotypic analysis of inflammatory breast cancers: identification of an “inflammatory signature”. *J Pathol*. 2004;**202**(3):265–273.
- Davies LC, Jenkins SJ, Allen E, et al. Tissue-resident macrophages. *Nat Immunol*. 2013;**14**(10):986–995.
- Delgado F, Estrada-Chávez C, Romano M, et al. Expression of NRAMP1 and iNOS in *Mycobacterium avium* subsp. *paratuberculosis* naturally infected cattle. *Comp Immunol Microbiol Infect Dis*. 2010;**33**(5):389–400.
- Delgado L, Marín JF, Muñoz M, et al. Pathological findings in young and adult sheep following experimental infection with 2 different doses of *Mycobacterium avium* subsp. *paratuberculosis*. *Vet Pathol*. 2013;**50**(5):857–866.
- Detre S, Saclani Jotti G, Dowsett M. A “quickscore” method for immunohistochemical semiquantitation: validation for oestrogen receptor in breast carcinomas. *J Clin Pathol*. 1995;**48**(9):876–878.
- Fedchenko N, Reifenrath J. Different interpretation and reporting of immunohistochemistry analysis results in the bone tissue. A review. *Diagn Pathol*. 2014;**9**:221.
- Fernández M, Benavides J, Sevilla IA, et al. Experimental infection of lambs with C and S-type strains of *Mycobacterium avium* subsp. *paratuberculosis*: immunological and pathological findings. *Vet Res*. 2014;**45**:5.
- Flesch IE, Hess JH, Oswald IP, et al. Growth inhibition of *Mycobacterium bovis* by IFN- γ stimulated macrophages: regulation by endogenous tumor necrosis factor- α and by IL-10. *Int Immunol*. 1994;**6**(5):693–700.
- Frehel C, Canonne-Hergaux F, Gros P, et al. Effect of *Nramp1* on bacterial replication and on maturation of *Mycobacterium avium*-containing phagosomes in bone marrow-derived mouse macrophages. *Cell Microbiol*. 2002;**4**(8):541–556.
- Fries PN, Popowych YI, Guan LL, et al. Age-related changes in the distribution and frequency of myeloid and T cell populations in the small intestine of calves. *Cell Immunol*. 2011;**271**(2):428–437.
- González J, Geijo MV, García-Pariente C, et al. Histopathological classification of lesions associated with natural paratuberculosis infection in cattle. *J Comp Pathol*. 2005;**133**(2–3):184–196.
- Harris NB, Barletta RG. *Mycobacterium avium* subsp. *paratuberculosis* in veterinary medicine. *Clin Microbiol Rev*. 2001;**14**(3):489–512.
- Hermon-Taylor J, Bull TJ, Sheridan JM, et al. Causation of Crohn’s disease by *Mycobacterium avium* subspecies *paratuberculosis*. *Can J Gastroenterol*. 2000;**14**(6):521–539.
- Holness C, Simmons DL. Molecular cloning of CD68, a human macrophage marker related to lysosomal glycoproteins. *Blood*. 1993;**81**(6):1607–1613.
- Hostetter J, Huffmann E, Byl K, et al. Inducible nitric oxide synthase immunoreactivity in the granulomatous intestinal lesions of naturally occurring bovine Johne’s disease. *Vet Pathol*. 2005;**43**(3):241–249.
- Huang Z, Luo Q, Guo Y, et al. *Mycobacterium tuberculosis*-induced polarization of human macrophage orchestrates the formation and development of tuberculous granulomas in vitro. *PLoS One*. 2015;**10**(6):e0129744.
- Jenkins SJ, Ruckerl D, Cook PC, et al. Local macrophage proliferation, rather than recruitment from the blood, is a signature of Th2 inflammation. *Science*. 2011;**332**(6035):1284–1288.
- Ka MB, Daumas A, Textoris J, et al. Phenotypic diversity and emerging new tools to study macrophage activation in bacterial infectious diseases. *Front Immunol*. 2014;**5**:500.
- Keshav S, Chung P, Milon G, et al. Lysozyme is an inducible marker of macrophage activation in murine tissues as demonstrated by in situ hybridization. *J Exp Med*. 1991;**174**(5):1049–1058.
- Khalifeh MS, Al-Majali AM, Stabel JR. Role of nitric oxide production in dairy cows naturally infected with *Mycobacterium avium* subsp. *paratuberculosis*. *Vet Immunol Immunopathol*. 2009;**131**(1–2):97–104.
- Koets AP, Eda S, Sreevatsan S. The within host dynamics of *Mycobacterium avium* ssp. *paratuberculosis* infection in cattle: where time and place matter. *Vet Res*. 2015;**46**:61.
- Krüger C, Köhler H, Liebler-Tenorio EM. Cellular composition of granulomatous lesions in gut-associated lymphoid tissues of goats during the first year after experimental infection with *Mycobacterium avium* subsp. *paratuberculosis*. *Vet Immunol Immunopathol*. 2015;**163**(1–2):33–45.
- Lugo-Villarino G, Verollet C, Maridonneau-Parini I, et al. Macrophage polarization: convergence point targeted by *Mycobacterium tuberculosis* and HIV. *Front Immunol*. 2011;**2**:43.
- Lybeck KR, Løvoll M, Johansen TB, et al. Intestinal strictures, fibrous adhesions and high local Interleukin-10 levels in goats infected naturally with *Mycobacterium avium* subsp. *paratuberculosis*. *J Comp Pathol*. 2013;**148**(2–3):157–172.
- Mantovani A, Sica A, Sozzani S, et al. The chemokine system in diverse forms of macrophage activation and polarization. *Trends Immunol*. 2004;**25**(12):677–686.
- Marino S, Cilfone NA, Mattila JT, et al. Macrophage polarization drives granuloma outcome during *Mycobacterium tuberculosis* infection. *Infect Immun*. 2015;**83**(1):324–338.
- Martinez FO, Gordon S. The M1 and M2 paradigm of macrophage activation: time for reassessment. *F1000 Prime Rep*. 2014;**6**:13.
- Mills CD, Kincaid K, Alt JM, et al. M-1/M-2 macrophages and the Th1/Th2 paradigm. *J Immunol*. 2000;**164**(12):6166–6173.
- Muñoz M, Delgado L, Verna A, et al. Expression of transforming growth factor- β 1 (TGF- β 1) in different types of granulomatous lesions in bovine and ovine paratuberculosis. *Comp Immunol Microbiol Infect Dis*. 2009;**32**(3):239–252.
- Muñoz M, García-Marín JF, García-Pariente C, et al. Efficacy of a killed vaccine (SILIRUM) in calves challenged with *Mycobacterium avium* subsp. *paratuberculosis*. In: Manning EJB, Nielsen SS, eds. *Proceedings of the 8th International Colloquium on Paratuberculosis*. Madison, WI: IAP; 2006:208–217.
- Navarro JA, Ramis G, Seva J, et al. Changes in lymphocyte subsets in the intestine and mesenteric lymph nodes in caprine paratuberculosis. *J Comp Pathol*. 1998;**118**(2):109–121.
- Ohsawa K, Imai Y, Sasaki Y, et al. Microglia/macrophage-specific protein Iba1 binds to fimbriin and enhances its actin-bundling activity. *J Neurochem*. 2004;**88**(4):844–856.

40. Palmer MV, Waters WR, Thacker TC. Lesion development and immunohistochemical changes in granulomas from cattle experimentally infected with *Mycobacterium bovis*. *Vet Pathol*. 2007;**44**(6):863–874.
41. Pechkovsky DV, Zalutskaya OM, Ivanov GI, et al. Calprotectin (MRP8/14 protein complex) release during mycobacterial infection *in vitro* and *in vivo*. *FEMS Immunol Med Microbiol*. 2000;**29**(1):27–33.
42. Pereira-Suárez AL, Estrada-Chávez C, Arriaga-Díaz C, et al. Coexpression of NRAMP1, iNOS and nitrotyrosine in bovine tuberculosis. *Vet Pathol*. 2006;**43**(5):709–717.
43. Pérez V, García Marín JF, Badiola JJ. Description and classification of different types of lesion associated with natural paratuberculosis infection in sheep. *J Comp Pathol*. 1996;**114**(2):107–122.
44. Pérez V, Tellechea J, Badiola JJ, et al. Relation between serologic response and pathologic findings in sheep with naturally acquired paratuberculosis. *Am J Vet Res*. 1997;**58**(8):799–803.
45. Pérez V, Tellechea J, Corpa JM, et al. Relation between pathologic findings and cellular immune responses in sheep with naturally acquired paratuberculosis. *Am J Vet Res*. 1999;**60**(1):123–127.
46. Redacliff LA, McClure SJ, Whittington RJ. Immunoperoxidase studies of cell mediated immune effector cell populations in early *Mycobacterium avium* subsp. *paratuberculosis* infection in sheep. *Vet Immunol Immunopathol*. 2004;**97**(3–4):149–162.
47. Scholzen T, Gerdes J. The Ki-67 protein: from the known and unknown. *J Cell Physiol*. 2000;**182**(3):311–322.
48. Sica A, Mantovani A. Macrophage plasticity and polarization: in vivo veritas. *J Clin Invest*. 2012;**122**(3):787–795.
49. Sigurdardóttir OG, Valheim M, Press CM. Establishment of *Mycobacterium avium* subsp. *paratuberculosis* infection in the intestine of ruminants. *Ann Drug Deliv Rev*. 2004;**56**(6):819–834.
50. Simeone R, Sayes F, Song O, et al. Cytosolic access of *Mycobacterium tuberculosis*: critical impact of phagosomal acidification control and demonstration of occurrence *in vivo*. *PLoS Pathog*. 2015;**11**(2):e1004650.
51. Smeed JA, Watkins CA, Rhind S, et al. Differential cytokine gene expression profiles in the three pathological forms of sheep paratuberculosis. *BMC Vet Res*. 2007;**3**:18.
52. Soulas C, Conerly C, Kim WK, et al. Recently infiltrating MAC387+ monocytes/macrophages. A third macrophage population involved in SIV and HIV encephalic lesion formation. *Am J Pathol*. 2011;**178**(11):2121–2135.
53. Tanaka S, Sato M, Onitsuka T, et al. Inflammatory cytokine gene expression in different types of granulomatous lesions during asymptomatic stages of bovine paratuberculosis. *Vet Pathol*. 2005;**42**(5):579–588.
54. Thirunavukkarasu S, de Silva K, Begg DJ, et al. Macrophage polarization in cattle experimentally exposed to *Mycobacterium avium* subsp. *paratuberculosis*. *Pathog Dis*. 2015;**73**(9):ftv085.
55. Valheim M, Sigurdardóttir OG, Sotorset AK, et al. Characterization of macrophages and occurrence of T cells in intestinal lesions of subclinical paratuberculosis in goats. *J Comp Pathol*. 2004;**131**(2–3):221–232.
56. Vázquez P, Garrido JM, Juste RA. Specific antibody and interferon-gamma responses associated with immunopathological forms of bovine paratuberculosis in slaughtered Friesian cattle. *PLoS One*. 2013;**8**(5):e64568.
57. Weiss DJ, Evanson OA, McClenahan D, et al. Regulation of expression of major histocompatibility antigens by bovine macrophages infected with *Mycobacterium avium* subsp. *paratuberculosis* and *Mycobacterium avium* subsp. *avium*. *Infect Immun*. 2001;**69**(2):1002–1008.
58. Whittington RJ, Begg DJ, de Silva K, et al. Comparative immunological and microbiological aspects of paratuberculosis as a model of mycobacterial infection. *Vet Immunol Immunopathol*. 2012;**148**(1–2):29–47.

Supplemental table 1: Details on the Origin, Age, Lesion Category and Distribution in the Different Tissue Samples, PCR, Culture and Immunological Test Results of the Animals Included in the Study.

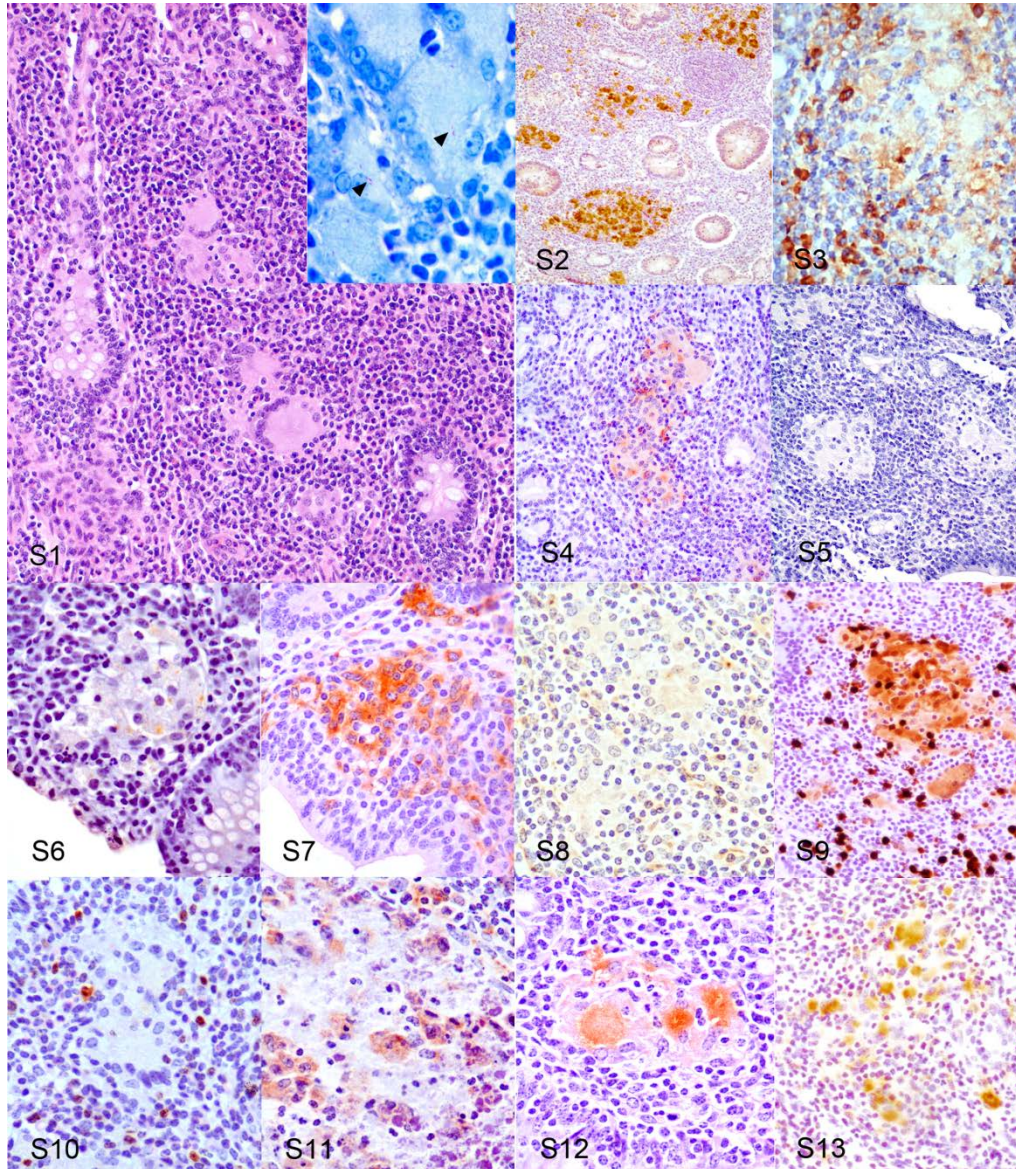
ID	Age	Lesion type	ICV		dIL		mIL		pIL		JPP		dJ		mJ		pJ		ILn		JLn		LI		Tissue culture			ELISA	Ifn				
			L	A	L	A	L	A	L	A	L	A	L	A	L	A	L	A	L	A	L	A	L	A	IL	J	Ln						
1E	0.75	F	F	0	0	0	0	0	0	0	0	F*	1	0	0	0	0	0	0	+	0	+	0	0	0	0	-	+	+	-	+		
2E	0.75	F	F	1	0	0	0	0	0	0	0	F*	0	0	0	0	0	0	0	+	0	0	0	0	0	0	-	-	+	-	+		
3E	0.75	F	0	0	0	0	0	0	0	0	0	F*	1	0	0	0	0	0	0	0	0	+	0	0	0	-	+	-	-	-	+		
4N	2	F	F	1	0	0	0	0	0	0	0	F*	0	0	0	0	0	0	0	0	0	+	0	0	0	+	-	-	-	-	+		
5N	2.5	F	0	0	0	0	0	0	0	0	0	F*	0	0	0	0	0	0	0	+	0	0	0	0	0	-	+	-	-	-	+		
6E	1.2	MF	F	0	0	1	MF*	1	MF	0	MF	1	0	0	0	0	0	0	+	1	+	0	0	0	0	+	-	-	-	-	+		
7E	1.2	MF	0	0	MF	0	MF*	0	MF	0	F	0	MF	1	MF	0	0	0	+	0	0	0	0	0	0	-	+	-	-	-	+		
8E	1.2	MF	MF	1	0	0	MF*	1	0	0	MF	1	0	0	MF	0	0	0	+	1	+	0	0	0	0	+	+	+	-	-	+		
9N	4	MF	F	0	MF	0	MF*	1	MF	0	MF	1	MF	0	MF	1	0	0	0	0	+	0	0	0	0	-	+	+	-	+	+		
10N	2.75	MF	F	1	0	0	MF*	1	MF	0	0	1	F	0	0	0	0	0	+	0	0	0	0	0	0	+	-	-	-	-	+		
11N	3.5	MF	0	0	MF	0	MF*	0	0	0	MF	0	0	0	MF	0	0	0	0	0	0	0	0	0	0	-	+	-	-	+	+		
12E	1.2	MB	MB	0	MF	2	MB*	3	MF	2	MB	3	MB	3	MB	2	MF	2	+	2	+	2	0	0	0	+	+	+	+	+	-	+	
13N	2.75	MB	MF	2	MF	3	MB*	3	MB	3	MB	2	MB	3	MB	2	MF	2	+	1	+	2	0	0	0	+	+	+	+	+	+	+	
14N	2.5	MB	F	2	MB	3	MB*	3	MF	2	MB	3	MF	2	MB	3	MB	2	+	2	+	1	0	0	0	+	+	+	+	+	+	+	
15N	3.5	MB	MB	2	MF	2	MB*	2	MF	2	MB	3	MB	3	MB	3	MB	2	+	1	+	1	+	0	0	+	+	+	+	+	+	-	+
16N	5	MB	MF	2	MB	3	MB*	3	MB	3	MF	2	MB	3	MF	2	MF	2	+	1	+	1	0	0	0	+	+	+	+	+	+	+	+
17N	3.7	MB	MF	2	MB	3	MB*	3	MF	3	MB	3	MF	3	MB	3	MB	3	+	2	+	2	0	0	0	+	+	+	+	+	+	+	+
18E	1.2	PB	MF	1	MF	0	PB*	1	PB	1	PB	1	MF	1	0	0	0	0	+	1	-	1	0	0	0	+	+	+	+	-	-	+	+
19N	3.2	PB	F	0	PB	1	PB*	1	MF	1	PB	0	PB	1	PB	0	MF	0	+	1	+	0	0	0	0	+	+	+	+	+	+	+	+
20N	2.5	PB	F	1	PB	1	PB*	1	PB	1	PB	0	PB	1	PB	1	MF	1	0	0	+	1	0	0	0	+	+	+	-	-	-	+	+
21N	3.5	PB	MF	0	PB	1	PB*	1	PB	1	PB	1	PB	0	PB	1	PB	1	+	1	+	1	0	0	0	+	+	+	-	-	-	+	+
22N	4	PB	F	1	MF	1	PB*	1	PB	1	PB	1	PB	1	PB	1	0	0	+	0	+	0	0	0	0	+	+	+	-	-	-	+	+
23N	2.7	PB	MF	1	PB	1	PB*	1	MF	0	PB	1	MF	0	MF	1	0	0	+	1	+	0	0	0	0	+	+	+	+	+	+	+	+

Abbreviations: E, experimental; N, natural; 0, no lesion; F, focal; MF, multifocal; MB, diffuse multibacillary; PB, diffuse paucibacillary; 0, no lesion; ICV, ileocaecal valve; d, distal; m, medium; p, proximal; IL, ileum; JPP, jejunal Peyer's patches; J, jejunum; ILn, ileocaecal-ileal lymph nodes; JLn, jejunal lymph nodes; LI, large intestine (caecum, colon, rectum); Ln, ileal, jejunal lymph nodes; L, lesion type; A, acid-fast bacilli category (0 to 3) assessed by Ziehl-Neelsen; +, positive; -, negative. Ifn: interferon- γ release assay. *Samples chosen for the immunohistochemical characterization of macrophages in this study.

Supplemental Table 2. Details of the primary antibodies and procedures used for the immunohistochemical examination of macrophages.

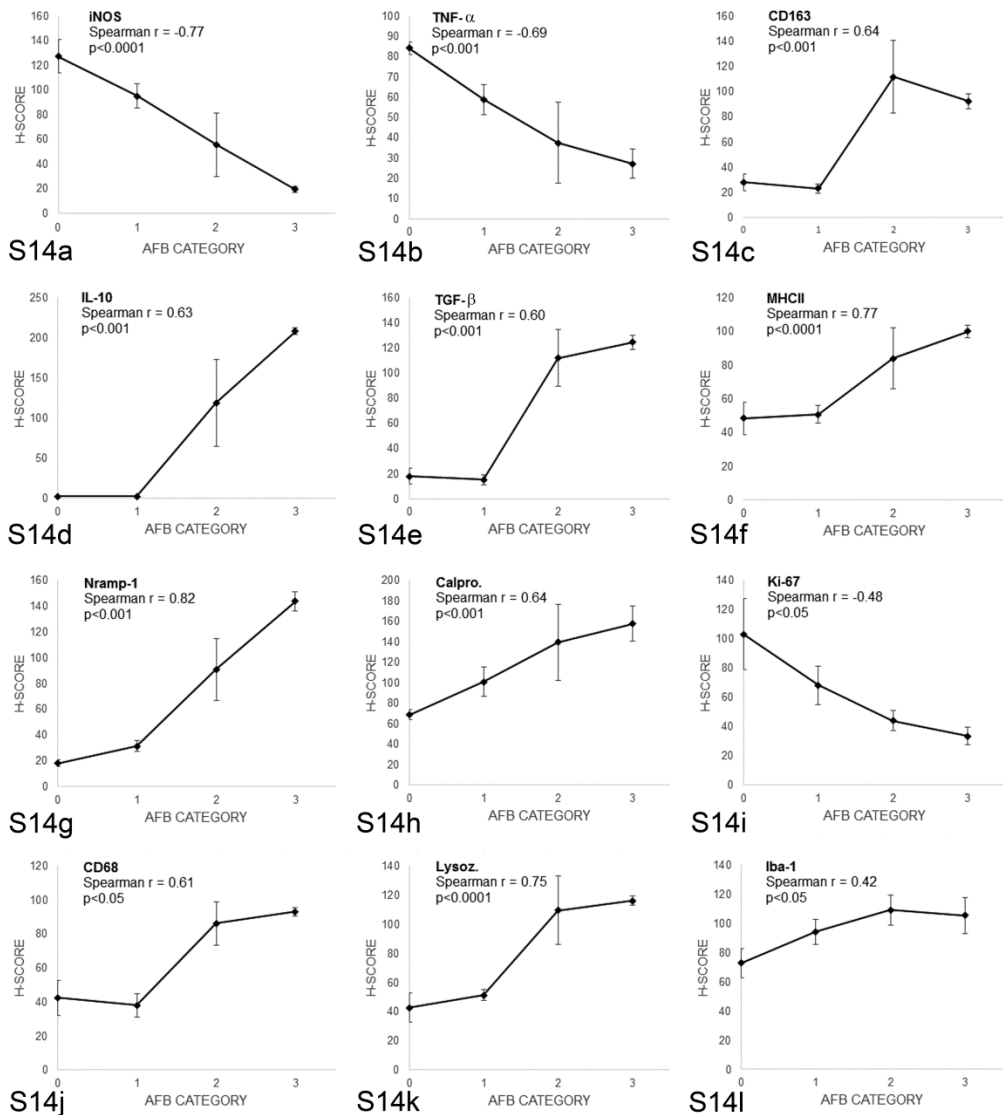
Target	Specificity (clone)	Source	Epitope demasking	Dilution
Murine iNOS	Inducible nitric oxide synthase (Rabbit polyclonal). M1 marker.	Millipore	Heat mediated Antigen Retrieval (AR) EDTA buffer, pH 9.0, 20 min	1:1000
Bovine TNF- α	Tumor necrosis factor- α (Clone CC327). M1 marker	Serotec	Heat mediated AR Citrate buffer, pH 6.0, 20 min	1:200
Human CD163	Tissue macrophages (Clone EDHu-1). M2 marker	Serotec	Heat mediated AR Citrate buffer, pH 6.0, 20 min	1:200
Human IL-10	Interleukin-10 (Rabbit polyclonal). M2 marker	Biorbyt	Heat mediated AR Citrate buffer, pH 6.0, 20 min	1:300
Human TGF- β	Transforming growth factor- β (Rabbit polyclonal). M2 marker	Santa Cruz	Microwave-mediated AR Citrate buffer, pH 6.0, 20 min	1:1000
Ovine MHC class II	Antigen-presenting cells (Clone VPM36)	Serotec	None	1:100
Human Nramp-1	Natural resistance associated macrophage protein 1 (Rabbit polyclonal)	Santa Cruz	Trypsin 0.1%, 15 min	1:50
Human myeloid/histiocyte antigen	Calprotectin (Clone MAC 387)	Dako	Protease 0.1%, 20 min	1:100
Human Ki-67 antigen	Proliferating cells (Clone MIB-1)	Dako	Heat mediated AR Citrate buffer, pH 6.0, 20 min	1:75
Human CD68	Monocytes and macrophages (Clone KP-1)	Dako	Trypsin 0.1%, 40 min	1:100
Human lysozyme	Lysozyme (Rabbit polyclonal)	Dako	Proteinase K 0.2%, 20 min	1:200
Iba-1	Macrophages (Rabbit polyclonal)	Wako	Heat mediated AR Citrate buffer, pH 6.0	1:2000

Supplemental Figure S1-S13



Supplemental figures S1-S13. *Mycobacterium avium* subsp *paratuberculosis* infection, cattle, ileum, diffuse paucibacillary lesion. **Figure S1.** Inflammatory infiltrate in the lamina propria is composed mainly of lymphocytes with small groups or macrophages scattered among them. HE. Inset: Macrophages or giant cells contain (arrowheads) few acid-fast bacilli. Ziehl Neelsen. **Figure S2.** iNOS immunoperoxidase stain showing marked immunolabelling in macrophages forming the granulomas. Immunohistochemistry (IHC). **Figure S3.** Weak positive immunoreactivity for TNF- α antibody in the granulomas and more intense in lymphocytes surrounding them. IHC. **Figure S4.** Weak immunoperoxidase stain for CD163 in macrophages of the granulomas. IHC. **Figure S5.** Lack of IL-10+ macrophages. IHC. **Figure S6.** Weak TGF- β expression in the macrophages. IHC. **Figure S7.** Positive immunolabelling for MHC class II antibody in macrophages and other lymphoid tissue cells. IHC. **Figure S8.** Very weak immunoperoxidase stain for Nramp-1 in macrophages. IHC. **Figure S9.** Calprotectin immunoperoxidase stain showing marked immunolabelling in granuloma macrophages. IHC. **Figure S10.** Absence of nuclear immunoreactivity for Ki-67 antibody in macrophages. IHC. **Figure S11.** Weak immunoperoxidase stain for CD68+ macrophages. IHC. **Figure S12.** Moderate expression of lysozyme immunoperoxidase stain in macrophages. IHC. **Figure S13.** Positive immunolabelling for Iba-1 antibody in the macrophages. IHC.

Supplemental Figure S14



Supplemental figure S14: Relationship between the amount of acid-fast bacilli (AFB) categories in the tissue sections and the histological scores (H-Scores) for (a) inducible oxide synthase (iNOS), (b) tumor necrosis factor- α (TNF- α), (c) CD163, (d) interleukin-10 (IL-10), (e) transforming growth factor- β (TGF- β), (f) MHC class II, (g) natural resistance macrophage protein-1 (Nramp-1), (h) calprotectin, (i) Ki-67, (j) CD68, (k) lysozyme, and (l) Iba-1 antibodies.



Immunohistochemical expression of interferon- γ in different types of granulomatous lesions associated with bovine paratuberculosis



Miguel Fernández^a, Miguel Fuertes^a, Natalia Elguezabal^b, Pablo Castaño^a, Marcos Royo^a, M. Carmen Ferreras^a, Julio Benavides^a, Valentín Pérez^{a,*}

^a Dpto de Sanidad Animal, Instituto de Ganadería de Montaña (CSIC-Universidad de León), Facultad de Veterinaria, Campus de Vegazana s/n, 24071, León, Spain

^b Dpto de Sanidad Animal, NEIKER-Instituto Vasco de Investigación y Desarrollo Agrario, 48160 Derio, Bizkaia, Spain

ARTICLE INFO

Article history:

Received 17 August 2016

Received in revised form

23 December 2016

Accepted 3 January 2017

Keywords:

Paratuberculosis

Bovine

Immunohistochemistry

IFN- γ

Lesion

ABSTRACT

Animals infected with *Mycobacterium avium* subsp. *paratuberculosis* (Map) show a variety of lesions, from focal forms, seen in subclinical stages to diffuse lesions in clinical cases. The purpose of this study was to evaluate the local expression of IFN- γ by immunohistochemistry in relation with the type of lesion in naturally Map-infected cows. The number of immunolabelled cells, –the majority morphologically consistent with lymphocytes–, was higher in focal and diffuse paucibacillary forms than in diffuse multibacillary lesions, where they appeared closely related to epithelioid cells. Diffuse multibacillary lesions had the lowest numbers, but higher than controls, and positive cells were intermingled among the macrophages. The peripheral IFN- γ production was higher in all Map infected cows and a positive correlation was found with the number of immunolabelled cells in the intestine. The findings of this study show that IFN- γ would play a role in the development of the different types of lesions in paratuberculosis, and also points out the importance of adequate sampling of lymphoid tissue containing samples when studying the local immune response in which IFN- γ expression may be involved, especially in cases where focal lesions are present.

© 2017 Elsevier Ltd. All rights reserved.

1. Introduction

Paratuberculosis or Johne's disease is a worldwide distributed infectious disease that causes a negative impact on domestic livestock, characterized by a decrease in productivity associated with a progressive loss of weight and eventual death of affected animals [1,2]. It is caused by *Mycobacterium avium* subspecies *paratuberculosis* (Map) and characterized by a chronic granulomatous enteritis and lymphadenitis that concerns domestic and wild ruminants [1–3]. Furthermore, speculation on the possibility of Map representing a zoonotic threat, as a possible causative agent of Crohn's disease, has elevated the priority of this disease to an issue of food safety [2].

Many studies support that animals get infected at an early age through ingestion of Map contained in feces shed by infected ani-

mals but only some of them develop clinical disease that appears only in adulthood [2,3]. Map-infected animals can show a variety of granulomatous lesions, according to their location, intensity, cellular types and number of acid-fast bacilli (AFB) [4–6]. Three main types of lesions, related to the stage of the disease, have been considered: *focal* forms, seen in subclinical phases of infection, are characterized by few, well-demarcated granulomas located exclusively in the intestinal lymphoid tissue; *diffuse* lesions, associated with clinical cases, show a wide-spread granulomatous enteritis that affects both the lymphoid tissue and lamina propria. According to the main cell types present in the inflammatory infiltrate and the number of AFB in diffuse lesions, two different categories have been distinguished: *diffuse multibacillary* forms, where epithelioid cells containing large numbers of AFB are the hallmark, and *diffuse paucibacillary* lesions characterized by an infiltrate formed by lymphocytes with isolated granulomas without AFB or a scarce number of them [5,6].

Several studies have shown a relationship between the type of lesion and the peripheral immune response [7–9]. Traditionally,

* Corresponding author.

E-mail address: vperp@unileon.es (V. Pérez).

it has been considered that a Th1 type immune response would predominate in the early and subclinical stages of Map infection shifting to a Th2 type response in the late phases of the disease [10,11]. However, recent evidence suggests that an overlap of these pathways can occur in some animals [9,12–14]. The strong Th1 bias dominated by an enhanced expression and secretion of interferon- γ (IFN- γ) in the early stages of Map infection suggests that this cytokine is critical for controlling the infection [2,8,10,11]. IFN- γ is produced predominantly by CD4+ Th1 cells and natural killer (NK) cells, and activates macrophages classically to bestow protection against Map infection by killing mycobacteria during phagocytosis [2,10,15].

In any case, scant information is available in relation to the local immune response. Furthermore, previous studies have mentioned that the peripheral immune response in Map infection does not correlate directly with the immune response at the intestinal lymph node level [16,17]. Concerning the role of IFN- γ at the local level, most of the previous research has focused on the quantification of gene transcription of this cytokine in tissue samples –intestine or lymph nodes– and has shown an upregulation of IFN- γ mRNA transcription associated with Map infection in cattle [17–19] or sheep [16]. However, the relationship between transcription levels and lesion types is not clear. While some studies have failed to detect significant differences in the local IFN- γ gene transcription between diffuse multibacillary and paucibacillary forms in cattle [20] or sheep [21], other studies have shown higher IFN- γ transcription levels in paucibacillary forms in sheep [22] or increased gene transcription that is directly correlated with the severity of the lesion, regardless of the type [17]. An increase of IFN- γ secretion by lymphocytes derived from intestine or lymph nodes after stimulation with johnin-PPD has been also recorded in sheep with paucibacillary lesions respect to multibacillary forms [23]. However, there are no studies focused on the immunohistochemical detection of IFN- γ expression in relation to the types of lesion. Only Redacliiff et al. [24] used immunoperoxidase methods for the evaluation of IFN- γ expressing cells in sheep positive to Map isolation but without gross or microscopic lesions, where few immunostained cells were detected and no comparison with the uninfected controls was possible.

Thus, bearing in mind the scarcity of studies that investigate the local expression of IFN- γ at the primary site of infection using immunohistochemical techniques, the main purpose of this study was the evaluation of the local expression of IFN- γ in relation with the different types of lesions associated with Map infection, in both control and naturally infected cows using these type of methods. Particular attention was paid to the assessment of the amount of positively immunolabelled cells and their distribution along the granulomatous infiltrate that characterizes each type of lesion as well as the relationship with the IFN- γ production after peripheral blood stimulation.

2. Material and methods

2.1. Experimental design

A total of twenty adult Holstein female cattle were analyzed in the study. They were adult animals (between 3 and 6 years-old), non-pregnant, dry cows that belonged to a herd that was undergoing a follow-up study on losses due to paratuberculosis. Infection was confirmed in 15 of them by both bacteriological culture of frozen tissues [6] and nested-PCR for Map DNA detection in the paraffin-embedded tissues used in the study [13]. The remaining 5 cows were examined as negative controls. All the cows were killed according to the standard methods in the current legislation in an authorized slaughterhouse.

2.2. Tissue samples

Gut and related lymph nodes were macroscopically evaluated and samples were collected for histopathological and immunohistochemical analysis. Particularly, samples from ileocecal valve, distal, middle or proximal ileum and jejunum (with and without Peyer's patches) as well as ileocecal, ileal and jejunal mesenteric lymph nodes were taken from each animal. Samples were fixed in 10% buffered formalin for less than 48 h and conventionally processed through a graded alcohol series before being embedded in paraffin wax. Sections 3.5 μ m thick were obtained from each sample and stained with Mayer's haematoxylin and eosin and Ziehl-Neelsen method for AFB identification. A subjective classification of the sections according to the number of AFB present was made, from 0 (no detectable bacilli), 1 (scant AFB in the cytoplasm of macrophages, seen with difficulty), 2 (moderate, easily detectable bacilli) to 3 (high load of AFB).

2.3. Classification of lesions

No lesion consistent with Map infection was observed in the five uninfected control cattle, while granulomatous lesions were detected in different samples from the intestine and lymph nodes from the remaining animals. Lesions were categorized following the guidelines previously proposed [6] for paratuberculosis lesions –according to the presence and location of granulomas in the different intestinal compartments, cell types present in the infiltrate and the amount of AFB–, as focal, diffuse multibacillary and diffuse paucibacillary. Only in the two latter types grossly visible thickening of the intestinal wall was noted. Each animal was classified based on the most severe lesion found in the studied intestinal samples. Focal lesions were composed of small, well-demarcated granulomas, up to 40–50 epithelioid cells, located exclusively in the interfollicular areas of the intestinal lymphoid tissue. Granulomas were also detected in the paracortical areas of the lymph nodes. None or very few AFB was detected. This type of lesion was present in 5 Map-infected cows.

Diffuse lesions were characterized by a widespread granulomatous lymphadenitis and enteritis where the normal intestinal architecture was notably distorted. Lesions were present in areas of the intestine with and without lymphoid tissue. In Peyer's patches, macrophages and occasional Langhan's type giant cells were seen both in the interfollicular areas and in the lymphoid follicles. The lamina propria was markedly distended due to the presence of abundant inflammatory cells. According to the cellular type and number of AFB, two different diffuse forms were considered: diffuse multibacillary lesions, seen in 5 Map-infected cows, were characterized by the predominance of epithelioid cells harbouring large numbers of AFB (categories 2 and 3); diffuse paucibacillary lesions, identified in another 5 Map-infected cows, showed large numbers of lymphocytes in the infiltrate, with some epithelioid and giant cells, with none or occasional AFB (categories 0 and 1).

2.4. Immunohistochemistry

Immunohistochemical studies were performed in a total of 20 intestinal tissue sections, one from each animal included in the study. From each animal, a sample from middle jejunum containing Peyer's patches was examined. This section was representative of the lesion category assigned to the animal. In total, five tissue sections from each type of lesion, from five different animals, were included, as well as five samples of middle jejunum (with Peyer's patches) without Map associated lesions, from the control cows.

A primary monoclonal antibody (IgG1 isotype) against bovine IFN- γ (Clone CC330; Bio-Rad laboratories Inc[®], Hercules, USA) was used. After deparaffinization, rehydration and drying, sec-

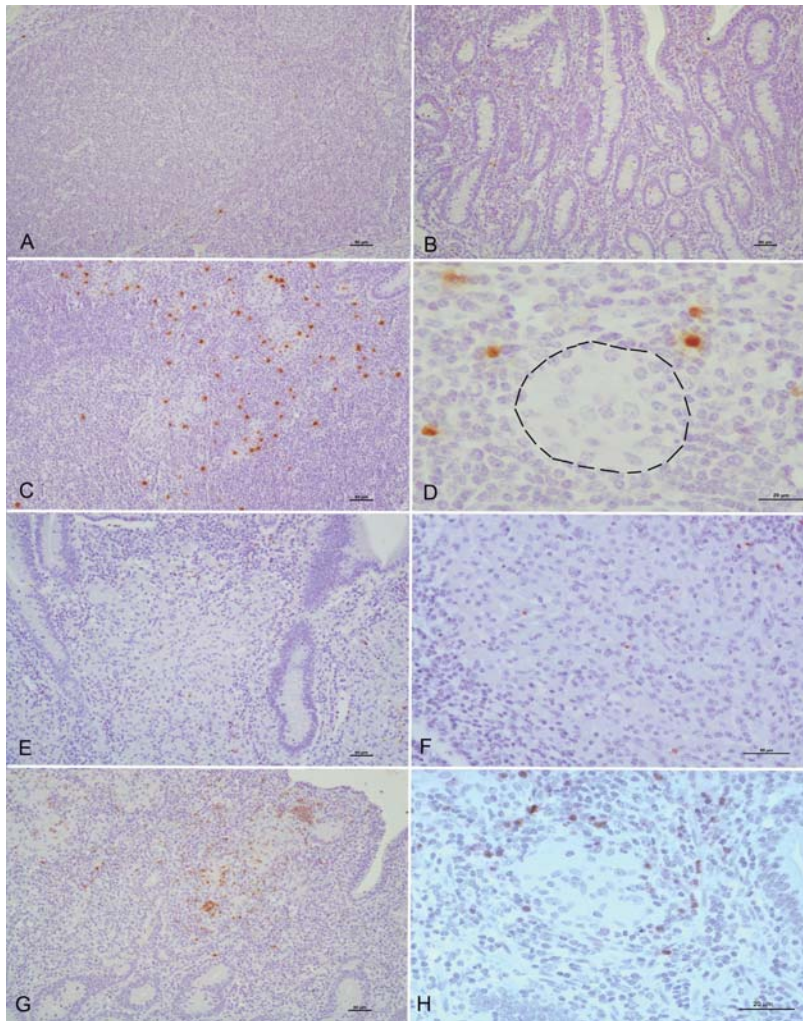


Fig. 1. Tissue sections from control and infected animals showing different types of lesions associated with Map infection, immunolabelled for IFN- γ . Positively immunostained cells show a brown-colored cytoplasm. Very few IFN- γ + cells in the interfollicular areas of the Peyer's patches (A) and intestinal lamina propria (B) in a control uninfected cow. Focal lesion. Positively immunolabelled cells are mainly located in relation with the granulomatous infiltrate. (C) Focal lesion. A higher magnification field showing IFN- γ + cells disposed close to the epithelioid cells (delimited by a line) that show no immunolabelling. Diffuse multibacillary lesion. Few, scattered immunolabelled cells are intermingled between the epithelioid cells forming the inflammatory infiltrate (E, F). Diffuse paucibacillary lesion. Numerous IFN- γ + cells mainly located in relation with epithelioid and giant cells where they can be seen forming aggregates or clusters and also intermingled between the granulomatous infiltrate (G, H).

tions were immersed into a 3% H₂O₂ in methanol solution during 30 min at room temperature and darkness, to block endogenous peroxidase. Heat mediated antigen retrieval was performed by means of PT Link[®] system, using the pH 6.0 target retrieval solution (Dako-Agilent technologies, Glostrup, Denmark) for 20 min. Samples were incubated overnight at 4 °C with the primary antibody at a 1:250 dilution in PBS in a humidified chamber. After washing, immunolabelling was performed using a ready-to-use kit EnVision System[®] (Dako-Agilent technologies, Glostrup, Denmark) where slides were incubated for 40 min at room temperature. After washing twice in PBS, antibody localization was determined using 3,3-diaminobenzidine (Dako-Agilent technologies, Glostrup, Denmark) as chromogenic substrate for peroxidase. Finally, slides were counterstained with Mayer's haematoxylin. Appropriate

species- and isotype- matched immunoglobulins were used as negative controls.

2.5. Evaluation of immunolabelling

Samples were scored according to the number of positively immunolabelled cells. In each slide, a total of 40 randomly chosen fields containing granulomatous lesions were selected and photographed at 400 \times . In tissues showing diffuse lesions, the inflammatory infiltrate occupying all the intestinal mucosa and granulomas were evaluated regardless of their location in the lamina propria or lymphoid tissue. In each of the 5 tissue sections presenting focal lesions, cell counting was performed in 40 microscopic fields in areas of lymphoid tissue with granulomatous lesions, 40 in the lymphoid tissue with no granulomas and another

40 fields in the lamina propria. Similarly, in the control cows, positively immunolabelled cells were counted in 40 fields each of the lamina propria and the lymphoid tissue areas independently.

Immunolabelled cells were counted on digital images using the Cell Counting add-on of Image J program® (U.S. National Institutes of Health, Bethesda, Maryland, USA). The final value for each type of lesion was obtained firstly calculating the average value for the 40 fields with granulomas examined in each tissue section and then, extracting the mean value between the 5 tissue slides evaluated. For the control cows, the average value for the 40 areas examined in the lymphoid tissue and lamina propria respectively was calculated independently and then, the mean value for each animal and finally the average between the 5 slides analyzed.

Evaluation of the different tissue sections for lesion classification as well as immunohistochemical stain, was performed independently by two pathologists (M. Fernández, V. Pérez) and discordant results were reviewed with a multi-headed microscope to reach consensus.

2.6. Interferon- γ release assay (IGRA) in peripheral blood

Between 2–4 days before slaughter, whole blood samples were collected from the tail vein in 5 ml vacutainer tubes (Venoject®, Terumo Europe N. V., Leuven, Belgium) with heparin. For the IFN- γ release assay (IGRA), two separate aliquots of 1.5 ml of blood were mixed with either 100 μ l of a sterile PBS or an avian purified protein derivative (PPD) antigen (CZ Veterinaria, Porriño, Spain) at a final concentration of 30 μ g/ml, within 3 h from the time of blood collection. After 20 h of whole-blood culture at 37 °C, the plasma supernatant was removed and frozen at –20 °C until required. Then, the assay for the IFN- γ determination was carried out following the manufacturer's instructions (BOVIGAM® TB Kit, ThermoFisher Scientific, Waltham, USA). In order to avoid inter-plate variations, all the O.D. values were adjusted by dividing the sample O.D. minus the negative control O.D., by the positive control O.D. minus the negative control O.D. from each plate. Once the raw values were standardised, results were expressed as a ratio between the mean OD of the avian PPD-stimulated plasma and the mean OD of the same plasma incubated with PBS.

2.7. Statistical analysis

As data for cell counting and IGRA index were not normally distributed, they were analyzed with nonparametric methods of statistical assessment. The Kruskal-Wallis test was used to compare the cell counts for the different groups of lesions (focal, diffuse multibacillary, diffuse paucibacillary) and the Mann-Whitney test was applied for post hoc comparison when significant differences were observed. A $P < 0.05$ was considered to indicate statistical significance. Correlation between cell counts and IGRA indexes for the different animals was evaluated using the Spearman test. All statistical analyses were performed using the statistical software Stata/SE version 12.0 (Stata Corp., Texas, USA).

3. Results

3.1. Distribution of immunolabelled cells

IFN- γ positively immunolabelled cells showed the cytoplasm markedly brown-colored and their identification was made according to their morphological features. The majority of positively immunostained cells had round nuclei and scant cytoplasm, morphologically consistent with lymphocytes, although the existence of larger positive cells that could be compatible with macrophages was also detected, always in low numbers. Epithelioid or multinu-

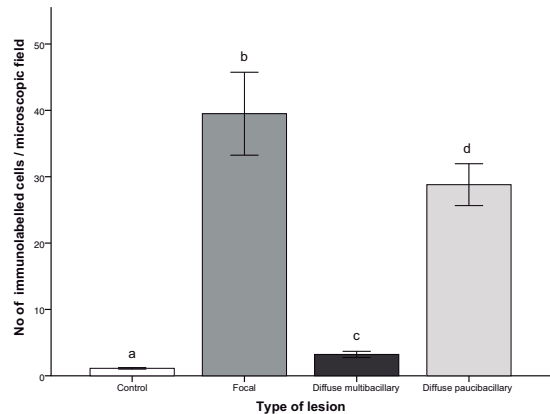


Fig. 2. Mean number of immunolabelled cells for IFN- γ per microscopic field, according to the type of lesion. Each type of lesion was assessed in 5 cows. A total of 40 microscopic fields was evaluated per animal. Different superscript letters indicate statistical significance ($P < 0.05$). Error bars: standard error.

cleated giant cells present in the granulomas of the different types of lesion did not show any immunostaining. Positively immunolabelled cells were always located in the lamina propria and in the intestinal lymphoid tissue.

In the control cows, very few cells were positively immunolabelled and they were scattered both in the lamina propria and the interfollicular area of the lymphoid tissue (Fig. 1A and B).

In samples with focal lesions, a high number of immunolabelled cells were seen in close relationship with the epithelioid cells forming the granulomas in the lymphoid tissue, where they appeared intermingled or in their vicinity (Fig. 1C and D). In the rest of the intestine, both in the lamina propria or lymphoid tissue with no lesions, few, scattered positively immunolabelled cells were detected with a similar distribution as in the control uninfected cows.

Regarding diffuse multibacillary lesions, few positive cells were intermingled with the epithelioid cells that were the main component of the inflammatory infiltrate, showing a similar distribution along the entire tissue section (Fig. 1E and F). However, in diffuse paucibacillary lesions, the number of positively immunolabelled cells was higher than in diffuse multibacillary lesions. They were more abundant in relation with the epithelioid or giant cells that formed the granulomas, appearing intermingled or surrounding them. They were frequently disposed forming aggregates or clusters. Positively immunolabelled cells were also found among the entire inflammatory infiltrate but to a lesser extent than in the areas with granulomas (Fig. 1G and H).

3.2. Number of immunolabelled cells for IFN- γ in relation to the type of lesion

The results of the cell counting in the tissue sections representing the different types of lesion are shown in Fig. 2. The number of cells labelled for IFN- γ was significantly higher ($P < 0.001$) in tissue sections presenting Map-associated lesions than in those from the control animals. The highest number of immunolabelled cells was observed in samples with focal lesions and was significantly higher ($P < 0.001$) than in the rest of the groups. Among the different types of lesion, sections with diffuse multibacillary forms showed significantly lower ($P < 0.001$) number of immunolabelled cells than the other two types.

In tissue sections with focal lesions, the number of labelled cells in areas without granulomas was assessed and the results

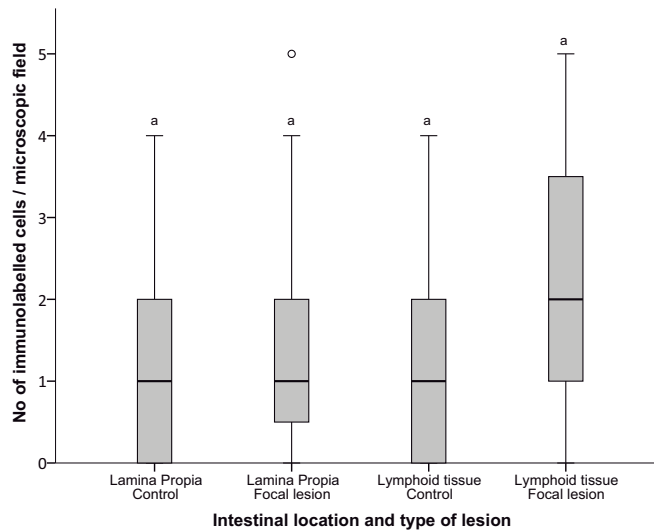


Fig. 3. Box-plot showing the mean number of immunolabelled cells for IFN- γ in the different intestinal compartments (lamina propria or lymphoid tissue) in the 5 control animals and in the 5 cows with focal lesions (in areas devoid of granulomatous infiltrate). A total of 40 microscopic fields was evaluated per location and animal. The solid lines show the median values and the open circles represent outlier values. Different superscript letters indicate statistical significance ($P < 0.05$).

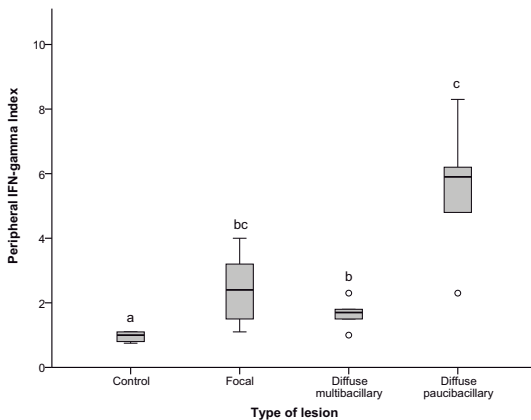


Fig. 4. Box-plot that shows the IFN- γ index obtained after peripheral blood stimulation with avian-PPD, according to the type of lesion showed by the cows. The solid lines show the median values and the open circles represent outlier values. Different superscript letters indicate statistical significance ($P < 0.05$).

are shown in Fig. 3. In this case, no significant differences were observed in the number of cells stained for IFN- γ both in the lamina propria or lymphoid tissue, between sections from control, uninfected cows and those with focal lesions.

3.3. Peripheral production of IFN- γ measured by IGRA

Fig. 4 shows the mean of the IFN- γ production indexes after blood stimulation in IGRA, according to the lesion category of the animals. Significant differences were observed ($P < 0.001$) between the control cows and the rest of the groups. The highest values were seen in animals with diffuse paucibacillary lesions, that were significantly higher than in those showing diffuse multibacillary forms ($P < 0.001$), whereas no statistical difference was observed in cows with focal lesions. Likewise, no significant differences were

detected in the IFN- γ index between animals with focal lesions and those with diffuse multibacillary forms.

As seen in Fig. 5, a positive correlation ($r_s = 0.6184$; $P < 0.05$) could be established between the number of cells positively immunolabelled for IFN- γ in the intestinal sections examined for each animal and the peripheral production of IFN- γ by IGRA of the same cow after blood stimulation.

4. Discussion

The results of this study have shown that IFN- γ could play a role in the development of the different types of granulomatous lesions associated with Map infection, since an increase in the number of IFN- γ positively immunolabelled cells has been observed in lesion containing samples in contrast to uninfected controls. Although lymphocytes are the main cells that produces this cytokine [25] other types of cells such as macrophages or dendritic cells have been also identified as able to produce IFN- γ [26–28]. In our study, we have not specifically identified the positively immunolabelled cells, although the majority of them were morphologically consistent with lymphocytes. In a previous work in tuberculosis lesions in deer [27] positive IFN- γ immunohistochemical labelling has been also found in cells morphologically compatible with epithelioid and multinucleated giant cells [26] that in our study have been always negative, suggesting the existence of differences between both mycobacterial infections or both animal species.

The critical function of IFN- γ in the immune defense against intracellular pathogens, including mycobacteria, has been widely documented [2,10,15,25]. This cytokine is essential for the activation of phagocytes and antigen presentation so that after infection, respiratory burst contributing to reactive oxygen and nitrogen intermediates production is induced in macrophages, with a known bactericidal activity [2,15].

Animals infected with Map can develop a variety of lesions, from focal forms seen in the subclinical phase of the disease to diffuse lesions usually related to clinical signs [4–6]. The highest number of IFN- γ immunolabelled cells was detected in focal lesions. They are related to initial or latent phases of paratuber-

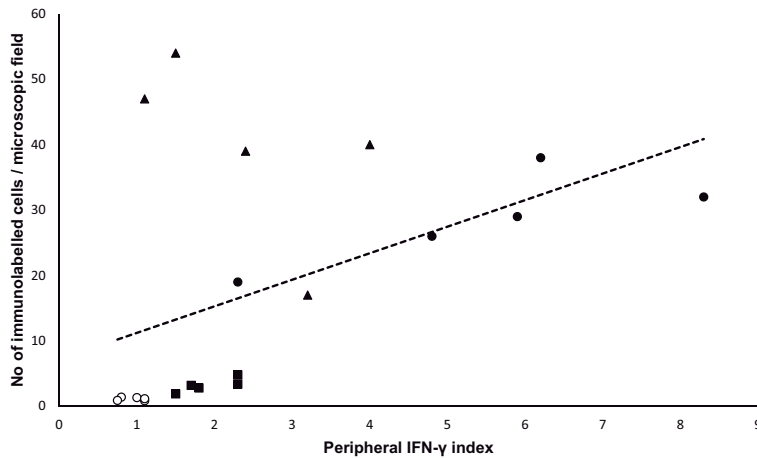


Fig. 5. Relationship between the number of immunolabelled cells for IFN- γ per microscopic field and the IFN- γ index obtained after peripheral blood stimulation with avian-PPD. Each type of lesion was assessed in 5 cows. A total of 40 microscopic fields was evaluated per animal. \circ control uninfected cows; \blacktriangle animals with focal lesions; \blacksquare diffuse multibacillary lesion; \bullet diffuse paucibacillary lesion.

culosis, with AFB rarely present, and are characterized by a very well demarcated inflammatory infiltrate composed of granulomas located exclusively in the intestinal lymphoid tissue [5,6,13]. This finding suggests that IFN- γ has activated macrophages and limited Map growth. In this sense, it has recently been reported that macrophages present in focal lesions show an M1 or classically activated profile [29] characterized by iNOS production and mycobacteria growth inhibition [29,30]. IFN- γ is one of the main stimuli that drive macrophages to a M1 phenotype [30,31] and the results of this study suggest that the production of this cytokine by lymphocytes located in the vicinity of the granulomas would be responsible of macrophage activation. Similarly, in tuberculosis caused by *Mycobacterium bovis* in deer, an increase in the number of cells expressing IFN- γ evaluated by immunohistochemistry has been found in stage I granulomas –considered as initial lesions with no AFB–, in comparison with more advanced forms [27].

In diffuse paucibacillary lesions, IFN- γ would play a similar role to that played in focal forms, since the number of immunolabelled cells was also high and they were located closely to granulomas with no or few AFB. Moreover, the presence of M1 or classically activated macrophages has been reported in this type of lesion [29]. Some other cytokines or other factors different from IFN- γ should be responsible for the development, in the Map-infected animal, either of focal or diffuse paucibacillary lesions [21,22]. In diffuse multibacillary lesions, the low levels of IFN- γ expressing cells would fit with the presence of abundant AFB in the cytoplasm of the macrophages. These macrophages show a M2 phenotype [29] and are associated with low levels of IFN- γ [30,31]. The presence of a widespread and non-organized granulomatous infiltrate in the intestine in this type of lesion, seems therefore related to low local expression of IFN- γ . It has been shown, in *M. avium* or other opportunistic mycobacterial species infections, that the presence of IFN- γ is necessary for the development of organized granulomas and in its absence, there is a disorganized accumulation of mixed cellular infiltrates [32]. Thus IFN- γ , in addition to its role as a limiting factor in lymphocyte accumulation [15], would also play a role in granuloma formation.

All these findings would be broadly consistent with the already proposed model of a Th1 to Th2 transition in the immune response in paratuberculosis [10]. Although this paradigm may not be present in all infected animals [9,12,13], the findings from this

study would indicate that, at a local level, in initial or latent, sub-clinical forms of the disease, a Th1 response characterized by the presence of high numbers of IFN- γ producing cells is predominant whereas, when the infection progresses to diffuse multibacillary forms, with high numbers of AFB, lesions are associated with low levels of cells expressing IFN- γ . However, in those animals in which infection has progressed to diffuse paucibacillary lesions, a Th1 response would be operating, although it is not able to control the inflammatory response. The factors responsible for this shift are still unknown [14] and deserve further investigation. Probably a complex coordination of immune responses occurs with these responses shifting as the host transits through the different stages of infection and disease [11]. It has been seen that the Map strain [13,33], the age of the animals at infection [34] or individual factors such as pattern recognition receptor expression [35] can play a role in the development of different immune or pathological responses, but other factors such as infection load, T cell exhaustion or hormonal changes have been also considered [14]. In our case, all were adult cows from the same breed, herd and managed under the same conditions so that presumably infected with the same Map strain. Although the age of infection was unknown, it seems feasible that individual factors would have played a role in the development of the different forms.

There are multiple studies that have outlined the importance of IFN- γ to the pathogenesis of paratuberculosis. In most of them, the role of this cytokine at local level has been investigated by the measurement of its production in stimulated lymphocytes extracted from the mesenteric lymph nodes [23] or by the gene transcription analysis [16–19] that is usually higher in Map infected animals. However, when the relationship with pathology has been determined, the results are variable and discordant. While in some studies in cattle, gene transcription for IFN- γ is directly correlated with the severity of the lesion [17], in other works it is higher in subclinically rather than in clinically infected animals, presumably with more severe lesions [36]. There is also discordance in the results from the studies analyzing the relation between IFN- γ mRNA transcription and the type of lesion. While there seems to be no differences between uninfected cattle and those showing lesions equivalent to diffuse multibacillary or paucibacillary forms [20], a higher gene transcription has been seen but in sheep suffering from paucibacillary lesions in comparison to uninfected animals

[22]. In our study, however, clear differences have been found in the number of cells immunolabelled for IFN- γ between diffuse multibacillary and paucibacillary lesions. Nevertheless, the main variations were observed in asymptomatic but infected animals that in most of these studies [17,19–22] did not show differences with the uninfected controls, while in our case, those animals with focal lesions showed the highest number of immunolabelled cells for IFN- γ . Considering the small size and demarcation of granulomas in focal forms and their exclusive presence in the intestinal lymphoid tissue, when a piece of tissue is taken for gene expression analysis, the likelihood of having a granulomatous lesion would be very low. Since the majority of immunomarked cells were located closely associated with the granulomas and in areas where no lesion was present no differences in the number of cells with the controls was observed, as demonstrated in this study, it seems feasible that no differences in gene expression with control animals could be obtained. This hypothesis could explain the absence of IFN- γ gene expression in infected but asymptomatic animals already mentioned [17,21,22]. A similar situation could occur when diffuse lesions are analyzed, since the number of lymphocytes expressing IFN- γ can vary among tissue sections, especially in paucibacillary forms. Thus, in further studies, the sampling of areas of the intestine with lymphoid tissue (ileocecal union or jejunal Peyer's patches) would increase the probability of having focal granulomatous lesions in the tissue sample. Furthermore, it has to be considered that these variations in the results can be due to the different nature of the methodology employed. The role of post-transcriptional modifications of IFN- γ expression [37] has also to be taken into account.

A direct correlation has been found between the number of immunolabelled cells for IFN- γ in the intestine and the released levels of this cytokine in plasma after blood stimulation. This result suggests that, in this study, the peripheral immune response can be a reflection of the local immune response and sensitized peripheral lymphocytes could have migrated from the intestine to the blood [38]. However, this possibility has to be carefully taken, considering that in the present work we have measured different parameters such as the number of cells that are producing IFN- γ in the intestine, and the quantity of this cytokine produced by peripheral blood cells after their stimulation.

5. Conclusion

The results of this study show that lymphocytes expressing IFN- γ would play a role in the development of the lesion types with Map infection and also that the presence of positively immunolabelled cells is closely related to the macrophages that form the granulomas and the quantity of AFB. Bearing this in mind, and in order to increase the chance of analyzing focal lesions, the choice of tissue samples with lymphoid tissue, especially in subclinically affected animals is recommended when evaluating the effects of this cytokine. Finally, the fact that all the animal groups with lesions, even severe, have shown higher levels of IFN- γ immunolabelled cells than the control group, suggest that this cytokine cannot prevent the development of diffuse forms, related clinical signs, although it is associated with Map growth inhibition inside the macrophages that are present in these lesions.

Competing interests

The authors declared no potential conflicts of interest with respect to the research, authorship and/or publication of this article.

Acknowledgements

This study was funded by grants AGL2012-39818-C02-01 and AGL2015-66540-C2-1 from the Spanish Ministry of Economy and Competitiveness. M. Fernández and P. Castaño are supported by a predoctoral contract from the “Junta de Castilla y León” and “Fondo Social Europeo” (European Union). J. Benavides and M. Royo are the recipients of a “Ramón y Cajal” and a “Predoctoral” contract of the Spanish Ministry of Economy and Competitiveness, respectively.

References

- [1] N.B. Harris, R.G. Barletta, *Mycobacterium avium* subsp. *paratuberculosis* in veterinary medicine, *Clin. Microbiol. Rev.* 14 (2001) 489–512.
- [2] R.J. Arsenault, P. Maattanen, J. Daible, A. Potter, P. Griebel, S. Napper, From mouth to macrophage: mechanisms of innate immune subversion by *Mycobacterium avium* subsp. *paratuberculosis*, *Vet. Res.* 45 (2014) 54.
- [3] R.W. Sweeney, Pathogenesis of paratuberculosis, *Vet. Clin. Food Anim.* 27 (2011) 537–546.
- [4] C.D. Buergelt, C. Hall, K. McEntee, J.R. Duncan, Pathological evaluation of paratuberculosis in naturally infected cattle, *Vet. Pathol.* 15 (1978) 196–207.
- [5] V. Pérez, J.F. García Marín, J.J. Badiola, Description and classification of different types of lesion associated with natural paratuberculosis infection in sheep, *J. Comp. Pathol.* 114 (1996) 107–122.
- [6] J. González, M.V. Geijo, C. García-Pariente, A. Verna, J.M. Corpa, L.E. Reyes, M.C. Ferreras, R.A. Juste, J.F. García Marín, V. Pérez, Histopathological classification of lesions associated with natural paratuberculosis infection in cattle, *J. Comp. Pathol.* 133 (2005) 184–196.
- [7] V. Pérez, J. Tellechea, J.J. Badiola, M. Gutiérrez, J.F. García Marín, Relation between serologic response and pathologic findings in sheep with naturally acquired paratuberculosis, *Am. J. Vet. Res.* 58 (1997) 7099–7803.
- [8] V. Pérez, J. Tellechea, J.M. Corpa, M. Gutiérrez, J.F. García Marín, Relation between pathologic findings and cellular immune responses in sheep with naturally acquired paratuberculosis, *Am. J. Vet. Res.* 60 (1999) 123–127.
- [9] P. Vázquez, J.M. Garrido, R.A. Juste, Specific antibody and interferon-gamma responses associated with immunopathological forms of bovine paratuberculosis in slaughtered Friesian cattle, *PLoS One* 8 (2013) e64568.
- [10] J.R. Stabel, Host responses to *Mycobacterium avium* subsp. *paratuberculosis*: a complex arsenal, *Anim. Health Res. Rev.* 7 (2007) 61–70.
- [11] J.R. Stabel, S. Robbe-Austerman, Early immune markers associated with *Mycobacterium avium* subsp. *paratuberculosis* infection in a neonatal calf model, *Clin. Vaccine Immunol.* 18 (2011) 393–405.
- [12] D.J. Begg, K. de Silva, N. Carter, K.M. Plain, A. Purdie, R.J. Whittington, Does a Th1 over Th2 dominancy really exist in the early stages of *Mycobacterium avium* subspecies *paratuberculosis* infections, *Immunobiology* 216 (2011) 840–846.
- [13] M. Fernández, J. Benavides, I.A. Sevilla, M. Fuertes, P. Castaño, L. Delgado, J.F. García Marín, J.M. Garrido, M.C. Ferreras, V. Pérez, Experimental infection of lambs with C and S-type strains of *Mycobacterium avium* subspecies *paratuberculosis*: immunological and pathological findings, *Vet. Res.* 45 (2014) 5.
- [14] A.P. Koetz, E. Shigetosi, S. Sreevatsan, The within host dynamics of *Mycobacterium avium* ssp. *paratuberculosis* infection in cattle: where time and place matter, *Vet. Res.* 46 (2015) 61.
- [15] A.M. Cooper, L.B. Adams, D.K. Dalton, R. Appelberg, S. Ehlers, IFN- γ and NO in mycobacterial disease: new jobs for old hands, *Trends Microbiol.* 10 (2002) 221–226.
- [16] I. Begara-McGorum, L.A. Wildblood, C.J. Clarke, K.M. Connor, K. Stevenson, C.J. McInnes, J.M. Sharp, D.G. Jones, Early immunopathological events in experimental ovine paratuberculosis, *Vet. Immunol. Immunopathol.* 63 (1998) 265–287.
- [17] D. Shu, S. Subharat, D.N. Wedlock, D. Luo, G.W. de Liste, B.M. Buddle, Diverse cytokine profile from mesenteric lymph node cells of cull cows severely affected with Johne's disease, *Clin. Vaccine Immunol.* 18 (2011) 1467–1476.
- [18] H. Lee, J.R. Stabel, M.E. Kehrli Jr., Cytokine gene expression in ileal tissues of cattle infected with *Mycobacterium paratuberculosis*, *Vet. Immunol. Immunopathol.* 82 (2001) 73–85.
- [19] P.M. Coussens, N. Verman, M.A. Coussens, M.D. Elftman, A.M. McNulty, Cytokine gene expression in peripheral blood mononuclear cells and tissues of cattle infected with *Mycobacterium avium* subsp. *paratuberculosis*: evidence for an inherent proinflammatory gene expression pattern, *Infect. Immun.* 72 (2004) 1409–1422.
- [20] S. Tanaka, M. Sato, T. Onitsuka, H. Kamata, Y. Yokomizo, Inflammatory cytokine gene expression in different types of granulomatous lesions during asymptomatic stages of bovine paratuberculosis, *Vet. Pathol.* 42 (2005) 579–588.
- [21] S. Gillan, R. O'Brien, A.D. Hughes, J.F.T. Griffin, Identification of immune parameters to differentiate disease states among sheep infected with *Mycobacterium avium* subsp. *paratuberculosis*, *Clin. Vaccine Immunol.* 17 (2010) 108–117.

- [22] J.A. Smeed, C.A. Watkins, S.M. Rhind, J. Hopkins, Differential cytokine gene expression profiles in the three pathological forms of sheep paratuberculosis, *BMC Vet. Res.* 3 (2007) 18.
- [23] C. Burrells, C.J. Clarke, A. Colston, J.M. Kay, J. Porter, D. Little, J.M. Sharp, Interferon-gamma and interleukin-2 release by lymphocytes derived from the blood, mesenteric lymph nodes and intestines of normal sheep and those affected with paratuberculosis (John's disease), *Vet. Immunol. Immunopathol.* 68 (1999) 139–148.
- [24] L.A. Redacliff, S.J. McClure, R.J. Whittington, Immunoperoxidase studies of cell mediated immune effector cell populations in early *Mycobacterium avium* subsp. *paratuberculosis* infection in sheep, *Vet. Immunol. Immunopathol.* 97 (2004) 149–162.
- [25] J. Zuñiga, D. Torres-García, T. Santos-Mendoza, T.S. Rodríguez-Reyna, J. Granados, E.J. Yunis, Cellular and humoral mechanisms involved in the control of tuberculosis, *Clin. Dev. Immunol.* 2012 (2012) 193923.
- [26] S. Gessani, F. Belardelli, IFN- γ expression in macrophages and its possible biological significance, *Cytokine Growth Factor Rev.* 9 (1998) 117–123.
- [27] W.L. García-Jiménez, P. Fernández-Llario, L. Gómez, J.M. Benítez-Medina, A. García-Sánchez, R. Martínez, D. Risco, J. Gough, A. Ortiz-Peláez, N.H. Smith, J. Hermoso de Mendoza, F.J. Salguero, Histological and immunohistochemical characterisation of *Mycobacterium bovis* induced granulomas in naturally infected fallow deer (*Dama dama*), *Vet. Immunol. Immunopathol.* 149 (2012) 66–75.
- [28] D. Vremec, M. O'Keefe, H. Hochrein, M. Fuchsberger, I. Caminschi, M. Lahoud, K. Shortman, Production of interferons by dendritic cells, plasmacytoid cells, natural killer cells, and interferon-producing killer dendritic cells, *Blood* 109 (2007) 1165–1173.
- [29] M. Fernández, J. Benavides, P. Castaño, N. Elguezabal, M. Fuertes, M. Muñoz, M. Royo, M.C. Ferreras, V. Pérez, Macrophage subsets within granulomatous intestinal lesions in bovine paratuberculosis, *Vet. Pathol.* 54 (2017) 82–93.
- [30] A. Mantovani, A. Sica, S. Sozzani, P. Allavena, A. Vecchi, M. Locati, The chemokine system in diverse forms of macrophage activation and polarization, *Trends Immunol.* 25 (2004) 677–686.
- [31] F.O. Martínez, S. Gordon, The M1 and M2 paradigm of macrophage activation: time for reassessment, *F1000 Prime Rep.* 6 (2014) 13.
- [32] S. Ehlers, E. Richter, Differential requirement for interferon- γ to restrict the growth of or eliminate some recently identified species of nontuberculous mycobacteria *in vivo*, *Clin. Exp. Immunol.* 124 (2001) 229–238.
- [33] A.E. Verna, C. García-Pariente, M. Muñoz, O. Moreno, J.F. García Marín, M.I. Romano, F. Paolicchi, V. Pérez, Variations in the immuno-pathological responses of lambs after experimental infection with different strains of *Mycobacterium avium* subsp. *paratuberculosis*, *Zoonoses Public Health* 54 (2007) 243–252.
- [34] L. Delgado, R.A. Juste, M. Muñoz, S. Morales, J. Benavides, M.C. Ferreras, J.F. García Marín, V. Pérez, Differences in the peripheral immune responses between lambs and adult ewes experimentally infected with *Mycobacterium avium* subsp. *paratuberculosis*, *Vet. Immunol. Immunopathol.* 145 (2012) 23–31.
- [35] K. Nalubamba, J. Smeed, A. Gossner, C. Watkins, R. Dalziel, J. Hopkins, Differential expression of pattern recognition receptors in the three pathological forms of sheep paratuberculosis, *Microbes Infect.* 10 (2008) 598–604.
- [36] R.W. Sweeney, D.E. Jones, P. Habecker, P. Scott, Interferon-gamma and interleukin 4 gene expression in cows infected with *Mycobacterium paratuberculosis*, *Am. J. Vet. Res.* 59 (1998) 842–847.
- [37] G. Maarifi, M.A. Maroui, J. Dutrieux, L. Dianoux, S. Nisole, M.K. Chelbi-Alix, Small ubiquitin-like modifier alters IFN response, *J. Immunol.* 195 (2015) 2312–2324.
- [38] H.J. Rothkötter, R. Pabst, M. Bailey, Lymphocyte migration in the intestinal mucosa: entry, transit and emigration of lymphoid cells and the influence of antigen, *Vet. Immunol. Immunopathol.* 72 (1999) 157–165.

