



Case Report

Peritoneal tuberculosis due to *Mycobacterium caprae*T. Nebreda^{a,*}, E. Álvarez-Prida^b, B. Blanco^c, M.A. Remacha^a, S. Samper^d, M.S. Jiménez^e^a Servicio de Microbiología, Complejo Asistencial Universitario de León, León, Spain^b Servicio de Cirugía General, Complejo Asistencial Universitario de León, León, Spain^c Servicio de Medicina Interna, Complejo Asistencial Universitario de León, León, Spain^d Instituto de Investigación Sanitaria Aragón, Instituto Aragonés de Ciencias de la Salud, Consorcio Centro de Investigación Biomédica en Red de Enfermedades Respiratorias, Zaragoza, Spain^e Centro Nacional de Microbiología, Instituto Carlos III, Majadahonda, Madrid, Spain

ARTICLE INFO

Article history:

Received 8 February 2016

Received in revised form 24 February 2016

Accepted 24 February 2016

Available online

Keywords:

Mycobacterium caprae

Peritoneal tuberculosis

Spoligotype SB0416

ABSTRACT

The incidence of tuberculosis in humans due to *Mycobacterium caprae* is very low and is almost confined to Europe. We report a case of a previously healthy 41-year-old Moroccan with a 6 month history of abdominal pain, weight loss, fatigue and diarrhea. A diagnosis of peritoneal tuberculosis due to *M. caprae* was made.

© 2016 The Authors. Published by Elsevier Ltd. This is an open access article under the CC BY-NC-ND license (<http://creativecommons.org/licenses/by-nc-nd/4.0/>).

Introduction

Peritoneal tuberculosis is an uncommon site of extrapulmonary infection in industrialized countries caused by *Mycobacterium tuberculosis* complex. The diagnosis can be challenging, since the most common findings are nonspecific, and a high index of suspicion is required to make the diagnosis in a timely manner. *Mycobacterium caprae* causes tuberculosis in humans and animals, but the incidence in humans is very low worldwide [1]. To our knowledge, we report the first case of peritoneal tuberculosis caused by *M. caprae*.

Case report

A 41-year-old Moroccan male, who had been living in Spain for 7 years, was admitted to the rapid diagnosis unit of Internal Medicine of the Complejo Asistencial Universitario de León, Spain with a 6 month history of abdominal pain, weight loss (10 kg in two months), fatigue and diarrhea. The patient had no relevant past medical history. He lived in an urban area, working as an electrician, and had no reported animal contact and denied ingesting unpasteurized dairy products.

A depressible, soft and painless abdomen was revealed on examination with diffuse discomfort on palpation and no signs of guarding. Laboratory tests showed a normal white blood cell count and a normocytic anemia. A HIV antibody test was negative. Mantoux test (17 mm) and interferon γ release assays were both positive. Chest X-ray and chest CT scan were normal and an abdominal CT scan showed mild ascites with small bilateral inguinal lymphadenopathy.

An intense plastic peritonitis was encountered at laparoscopy affecting all abdominal spaces with soft rubbery adhesions that virtually blocked all initial access to the abdominal cavity. Countless amount of nodules were seen on the omentum and both the parietal and the visceral peritoneum and mainly on Glisson's sheath and digestive tube serosal surfaces (Fig. 1). A small amount of fluid was observed around liver and spleen. Careful adhesiolysis was needed for exposure and to obtain fluid samples. Various biopsies were taken from the omental and peritoneal nodules. All specimens were sent for microbiology, cytology and pathological examinations. Histopathology showed non-necrotizing granuloma. Acid fast stains of the tissue were negative. There was no evidence of malignancy. No acid fast bacilli (AFB) were seen on stain of the peritoneal fluid. The fluid PCR and culture were also negative for mycobacteria.

Mycobacterial DNA was identified in the biopsy by PCR (Xpert[®] MTB/Rif PCR, Cepheid AB, Solna, Sweden). Mycobacterial growth was detected with Bactec[™] MGIT[™] 960 system, (Becton

* Corresponding author at: Servicio de Microbiología, Complejo Asistencial Universitario de León, Avda. Altos de Nava s/n, León, Spain. Tel.: +34 606184089; fax: +34 987235165.

E-mail address: tnebreda@gmail.com (T. Nebreda).

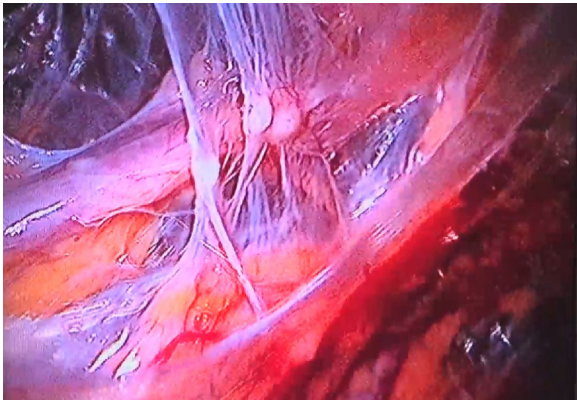


Fig. 1. Nodules and peritoneal adhesions seen at laparoscopy.

Table 1
Members of the *Mycobacterium tuberculosis* complex.

Microorganism	Primary host(s)
<i>Mycobacterium tuberculosis</i>	Man
<i>Mycobacterium africanum</i>	Man (West Africa)
<i>Mycobacterium canettii</i>	Man (Horn of Africa)
<i>Mycobacterium bovis</i>	Cattle and other animals
<i>Mycobacterium bovis</i> BCG	Vaccine
<i>Mycobacterium microti</i>	Voiles and other small rodents
<i>Mycobacterium caprae</i>	Goats, cattle and other animals (Europe)
<i>Mycobacterium pinnipedii</i>	Seals

Dickinson, Oxford, UK) on Day 26 of the peritoneal biopsy. Immunochromatographic test for MTC (TB Ag MPT 64 rapid, Standard diagnostics, INC, Republic of Korea) classified this isolate within the *M. tuberculosis* complex. Identification and susceptibility testing were performed as described [2] at the National de *Mycobacterium* laboratory, Instituto Carlos III, Majadahonda, Madrid, Spain as *M. caprae* being fully sensitive to isoniazid, streptomycin, ethambutol, rifampin and pyrazinamide. The *M. caprae* isolate corresponded to spoligotype SIT646 in the international SITVIT database and SB0416 in the *Mycobacterium bovis* spoligotype database (<http://www.Mbovis.org>). It was performed Aragon Institute for Health Research (IIS Aragon), Zaragoza, Spain as previous described [3].

Treatment for tuberculous peritonitis was initiated after the laparoscopy with a 4-drug regimen of including isoniazid, rifampin, pyrazinamide and ethambutol. Two months after starting antituberculous treatment, the patient reported improvement of symptoms. The patient completed 2 months of four-drug therapy without complications and an additional 7 months of isoniazid and rifampin. He is asymptomatic.

Discussion

M. caprae, a member of the *M. tuberculosis* complex (Table 1) can cause tuberculosis in man and many domesticated and wild animals. The organism was first characterized in 1999 and the name *M. tuberculosis* subspecies *caprae* was proposed [4]. In 2003, it was elevated to species rank as *M. caprae* [5]. Zoonotic transmission of this bacterium from livestock, mainly goats or cattle, to man seems to be the major route of human acquisition and no clear evidence of man-to-man transmission has been reported.

The incidence of infection with *M. caprae* in humans does not exceed 0.3% of total tuberculosis cases and is almost entirely confined to Europe. This low incidence is due to public health measures introduced decades ago to prevent zoonotic tuberculosis

transmission in industrialized nations: pasteurization of dairy products and culling of infected cattle herds [1]. Although, zoonotic tuberculosis in some European countries has increased recently due to the migration of people from areas more endemic for *M. bovis*, this does not seem to be the case for infection with *M. caprae* as most infected individuals have been native Europeans [1,6]. Outside Europe, *M. caprae* has been reported in only 1 human case in Morocco [7] and in 3 cattle cases (2 cases in Algeria and 1 case in Tunisia) [1]. The Morocco isolate showed spoligotype SIT644 [7].

In Spain, *M. caprae* is widespread in domesticated goats and cattle and in a variety of wild animals, representing 7.4% of all *M. tuberculosis* complex isolates from animals [8]. The percentage of human *M. tuberculosis* complex infections, however, is low, about 0.3% [2]. Although SB0157 is the most dominant spoligotype, both in humans and animals, the SB0416 spoligotype found in our patient is the second most common in animals in our region [8] and have been isolated in humans in other regions of Spain, in Germany and in Austria [1], so it is likely that the infection was acquired in Spain.

Dürr et al. [9] found a strong association between zoonotic tuberculosis and extrapulmonary diseases as compared to non-zoonotic human tuberculosis with, being lymph nodes and genitourinary systems the most often affected primary sites. In European countries, patients with zoonotic tuberculosis suffered more from reactivation of old infections, which mainly leads to pulmonary tuberculosis. This could explain that only few cases due to *M. caprae* have been reported in detail in case reports: 2 cases of cutaneous tuberculosis [10,11] and 1 each of pericarditis case [12], urinary tract involvement [13] and meningitis [14].

A high rate of tuberculosis is reported in Leon's Health Area with an incidence of active tuberculosis in 2013 of 18 per 100.000 populations as [12] compared with Spain's overall rate of 12 per 100.000 [15]. Tubercular peritonitis is very uncommon with only 6 cases of abdominal tuberculosis of a total of 596 cases of TB have been confirmed in our laboratory between 2006 and 2015; five of them were native people unlike others European studies in which a higher proportion of peritoneal tuberculosis in immigrant populations from developing countries is found [16,17].

In low incidence countries, the diagnosis of peritoneal tuberculosis is often delayed for more than 4 months or even overlooked [16,17], partly due to a nonspecific clinical presentation in the absence of lung involvement and in part because more than 20% of patients do not have risk factors with nonspecific laboratory tests [17]. The diagnosis in our patient was made following 6 months of symptoms.

Laparoscopy is the gold standard for diagnosis of peritoneal tuberculosis, yielding the diagnosis in up to 92% of cases [16]. It permits a complete exploration of the peritoneal cavity and allows the ability to sample various tissues for biopsy and culture. Peritoneal tuberculosis is a paucibacillar process and is rarely possible to demonstrate acid-fast bacilli in ascitic fluid. In this case, as reflected in the literature, AFB stain, PCR and culture did not assist in the initial management of the patient [16].

References

- [1] Prodinge WM, Indra A, Koksalan OK, Kilicaslan Z, Richter E. *Mycobacterium caprae* infection in humans. *Expert Rev Anti Infect Ther* 2014;12:1501–13.
- [2] Rodríguez E, Sánchez LP, Pérez S, Herrera L, Jiménez MS, Samper S, et al. Human tuberculosis due to *Mycobacterium bovis* and *M. caprae* in Spain, 2004–2007. *Int J Tuberc Lung Dis* 2007;13:1536–41.
- [3] Kamerbeek J, Schouls L, Kolk A, Van Agterveld M, Van Spoolingen D, Kuijper S, et al. Simultaneous detection and strain differentiation of *Mycobacterium tuberculosis* for diagnosis and epidemiology. *J Clin Microbiol* 1997;35:907–14.
- [4] Aranaz A, Liébana E, Gómez-Mampaso E, Galán HC, Cousins D, Ortega A, et al. *Mycobacterium tuberculosis* subsp. *caprae* subsp. nov.: a taxonomic study of a new member of the *Mycobacterium tuberculosis* complex isolated from goats in Spain. *Int J Syst Bacteriol* 1999;49:1263–73.

- [5] Aranaz A, Cousins D, Mateos A, Domínguez I. Elevation of *Mycobacterium tuberculosis* subsp. *caprae* Aranaz et al., 1999 to species rank as *Mycobacterium caprae* comb. Int J Syst Bacteriol 2003;53:1785–9.
- [6] Aime B, Lequen L, Balageas A, Haddad N, Maugein J. Infection a *M. bovis* et *M. caprae* in Aquitaine: etude clinico-épidémiologique de 15 cas. Pathol Biol (Paris) 2012;60:156–9.
- [7] Lahlou O, Millet J, Chaoui I, Sabouni R, Filali-Maltouf A, Akrim M, et al. The genotypic population structure of *Mycobacterium tuberculosis* complex from Moroccan patients reveals a predominance of Euro-American lineages. PLoS One 2012;7:e47113.
- [8] Rodríguez S, Bezos J, Romero B, de Juan L, Álvarez J, Castellanos E, et al. The Spanish network on surveillance and monitoring of animal tuberculosis *Mycobacterium caprae* infection in livestock and wildlife, Spain. Emerg Infect Dis 2011;17:532–5.
- [9] Dürr S, Müller B, Alonso S, Hattendorf J, Laisse JM, Van Helden PD, et al. Differences in primary sites of infection between zoonotic and human tuberculosis: results from a worldwide systematic review. PLoS Negl Trop Dis 2013;7:e2399.
- [10] Meyer S, Naumann L, Landthaler M, Vogt T. Lupus vulgaris caused by *Mycobacterium bovis* spp. *caprae*. Br J Dermatol 2005;153:220–2.
- [11] Tar SY, Bozdemir B, Gurel MS, Bilgin FU, Baran MF, Demirkesen C. *Mycobacterium bovis caprae*: a rare agent of lupus vulgaris. Clin Exp Dermatol 2009;34:532–533.
- [12] Blaas SH, Böhm S, Martin G, Erler W, Glück T, Lehn N, et al. Pericarditis as primary manifestation of *Mycobacterium bovis* ssp. *caprae* infection. Diagn Microbiol Infect Dis 2003;47:431–3.
- [13] Sintchenko V, Jelfs P, Dally M, Crighton T, Gilbert GL. A case of urinary tuberculosis due to *Mycobacterium bovis* subspecies *caprae*. Pathology 2006;38:376–7.
- [14] Hansen N, Seiler C, Rumpf J, Kraft P, Dlaske H, Abele-Horn M, et al. Human tuberculosis meningitis caused by *Mycobacterium caprae*. Case Rep Neurol 2012;4:54–60.
- [15] Rodríguez E, Villarrubia S, Díaz O. Tuberculosis en España en el año 2013. Situación epidemiológica. Bol Epidemiol Sem 2014;22:201–9.
- [16] Rai S, Thomas WM. Diagnosis of abdominal tuberculosis: the importance of laparoscopy. J R Soc Med 2003;96:586–8.
- [17] Mamo J, Brij S, Enoch D. Abdominal tuberculosis: a retrospective review of cases presenting to a UK district hospital. Q J Med 2013;106:347–54.