

Atrioventricular dissociation in a cat with persistent *truncus arteriosus*

Oscar Monge-Utrilla¹ | M Belén García-Rodríguez²  | Nerea Cuesta-García³ | Inmaculada Díez-Prieto²

¹Veterinary Hospital University of León, University of León, León, Spain

²Department of Veterinary Medicine, Surgery and Anatomy, University of León, León, Spain

³Clinical Analysis Laboratory, Idexx Laboratories, Wetherby, United Kingdom

Correspondence

M Belén García-Rodríguez, Veterinary Hospital University of León, Avenida Pedro Cármenes s/n, León 24007, Spain.
Email: mbgarr@unileon.es

Abstract

A 10-month-old female domestic shorthaired (DSH) cat was presented with peracute respiratory problems. Physical examination revealed dyspnoea, tachypnoea, cyanosis, weak pulse and bradycardia. Auscultation showed pulmonary crepitation and attenuated heart sounds and a pansystolic grade V/VI murmur. The electrocardiogram showed atrioventricular dissociation identified as third-degree sinoatrial block. X-rays showed increased density in the ventral and middle zones of the thorax and loss of definition of the cardiac silhouette and increased diffuse radiographic density of the entire abdomen.

Echocardiography revealed dilatation of the right atrium and concentric biventricular hypertrophy. A type 1 persistent *truncus arteriosus* was diagnosed at necropsy.

This is the first case report of this type of arrhythmia in a cat with persistent *truncus arteriosus*, and its relationship with the described congenital cardiac anomaly is discussed.

KEYWORDS

arrhythmia, atrioventricular dissociation, cardiac malformation, feline

1 | INTRODUCTION

Persistent *truncus arteriosus* is a very rare congenital malformation in domestic animals (Scansen et al., 2015; Schrope, 2015). This lesion consists of an absence of division of the *truncus arteriosus* into the pulmonary artery and aorta during embryonic development and is usually associated with the presence of a ventricular septum defect (Collett & Edwards, 1949). This malformation occurs only occasionally in animals and sometimes is observed at the slaughterhouse in farm animals (Eroksuz et al., 2015).

The feline clinical cases previously described did not report arrhythmias except for premature ventricular complexes in one of them (Nicolle et al., 2005). The case reported was presented with an atrioventricular dissociation, an arrhythmia not previously described in this cardiac malformation.

1.1 | Case history

A female, 10 months of age, domestic shorthaired (DSH) cat (2.650 kg) was examined at the Veterinary Hospital of the University of León (Spain) because difficult breathing of peracute onset. According to the owners, the animal was apparently healthy until 3 days prior, when it became apathetic and intolerant to exercise.

Physical examination indicated a body condition score of 4/9 (WSAVA scale), body temperature of 38.1°C and slightly cyanotic mucous membranes. Tachypnoea (60 rpm), dyspnoea, bradycardia (90 ppm) and weak pulse were observed. Upon palpation, cardiac thrill and ascites waves were observed.

Pulmonary auscultation revealed crepitations in the dorsal lung lobes and in the medial and ventral areas the lung noise became inaudible. Cardiac auscultation was difficult with attenuated heart sounds

This is an open access article under the terms of the [Creative Commons Attribution-NonCommercial-NoDerivs](https://creativecommons.org/licenses/by-nc-nd/4.0/) License, which permits use and distribution in any medium, provided the original work is properly cited, the use is non-commercial and no modifications or adaptations are made.

© 2023 The Authors. *Veterinary Medicine and Science* published by John Wiley & Sons Ltd.

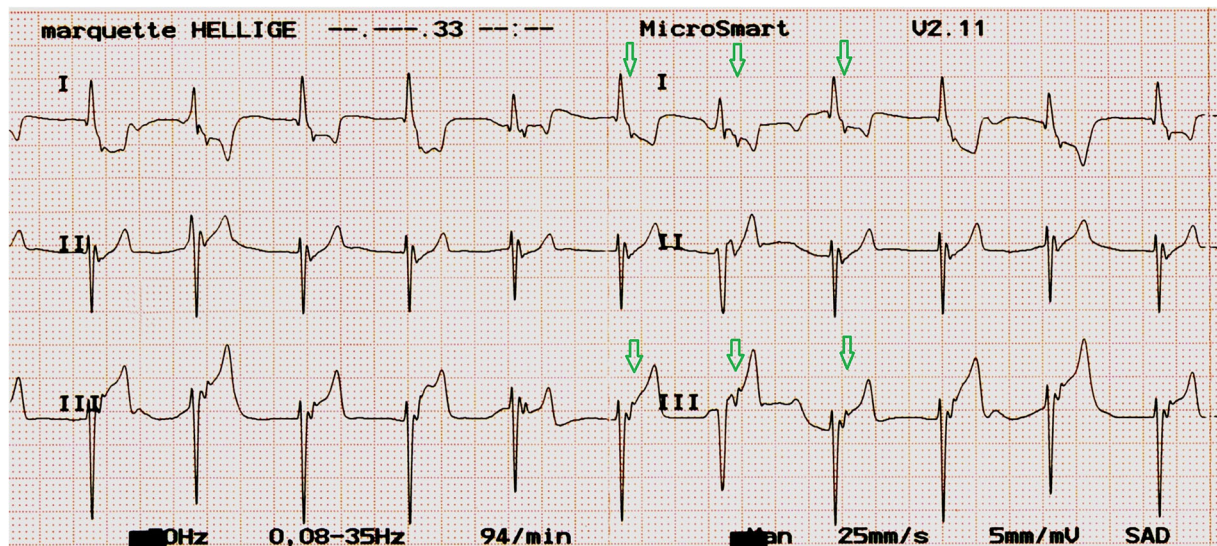


FIGURE 1 Electrocardiographic tracing leads I, II and III, acquired with the animal in the right lateral decubitus position, electrode placement as standard. Speed 25 mm/s and voltage 5 mm/mV. Regular rhythm at 90 bpm, dissociation of atrial and ventricular electrical activity, presence of a notch in the ST segment compatible with the P' wave marked with a green arrow.

and a pansystolic grade V/VI murmur, with maximum intensity in the left hemithorax in the cardiac base zone, radiating to the apex and right hemithorax.

The electrocardiogram showed atrioventricular dissociation, with a slow ventricular rhythm to 90 bpm, a normal scape rhythm of the atrioventricular node, rS-type QRS complexes of 50-ms duration, with mean electrical axis deviated to the left and ventral-dorsal direction (left axis deviation, -63°), presence of P' waves with a mean electrical axis of $\pm 180^\circ$ originating in the left atrium free wall, no QRS complex preceded by a P wave and presence of the P' wave in the ST segment (Figure 1).

X-rays showed changes compatible with pleural effusion and ascites. The echocardiographic examination showed a severely dilated right atrium and biventricular concentric hypertrophy and mild pleural and pericardial effusion. Due to dyspnoea, tachypnoea and cyanosis, it was decided to interrupt the examination to begin medical stabilisation.

Treatment was started with diuretics [constant rate infusion of furosemide (Seguril, Sanofi-Aventis S.A.) at 1 mg/kg/h after an initial bolus of 3 mg/kg], analgesia [butorphanol (Torbugesic Vet, Zoetis Spain), 0.1 mg/kg] and cage oxygen therapy. Despite initial improvement the patient died.

The post-mortem study revealed serosanguineous fluid in the abdominal and thoracic cavities. The liver was congested, the lungs failed to collapsed when opening the thoracic cavity as expanded with a diffuse red-tinged watery fluid and soft consistency (congestion). The heart was increased in size with severe thickening of the left ventricle (8–10 mm) and right ventricle (5–8 mm). The right atrium was markedly distended. A proximal ventricular septal defect was identified (Figure 2). Emerging from the semilunar valves of the right heart was a markedly distended arterial vestibule from which the main cardiac arteries emerged. This arterial vestibule was contiguous to the proximal ventricular septal defect given focal

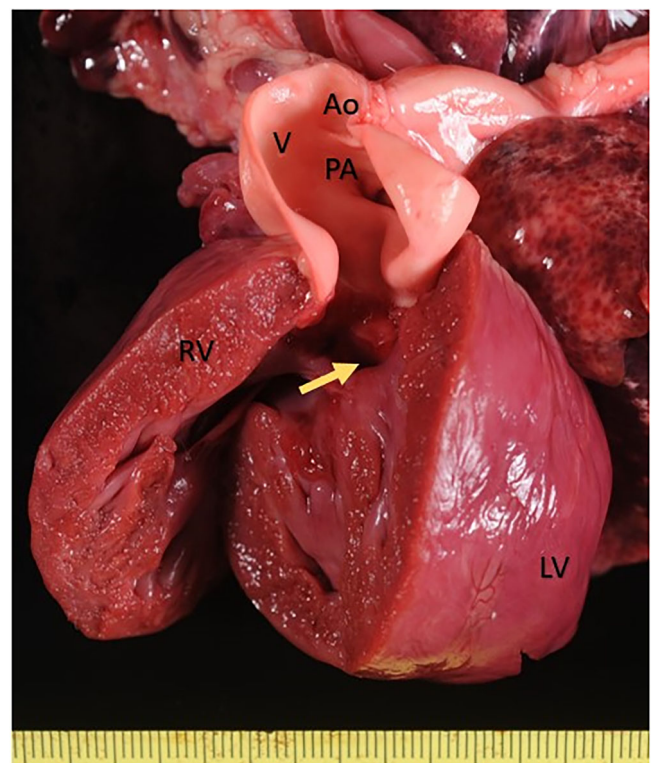


FIGURE 2 Macroscopic evaluation of the heart during necropsy. Communication is indicated from the left ventricle (LV) to the same arterial vestibule (V) and posterior truncus arteriosus (PTA) that leaves from the open right ventricle (RV). A yellow arrow points to the entrance of the interventricular defect.

continuity between mitral valve, tricuspid valve and semilunar valve (Figure 3).

Microscopically, in the lung there was diffuse moderate distension of interalveolar capillaries and small to medium-calibre blood

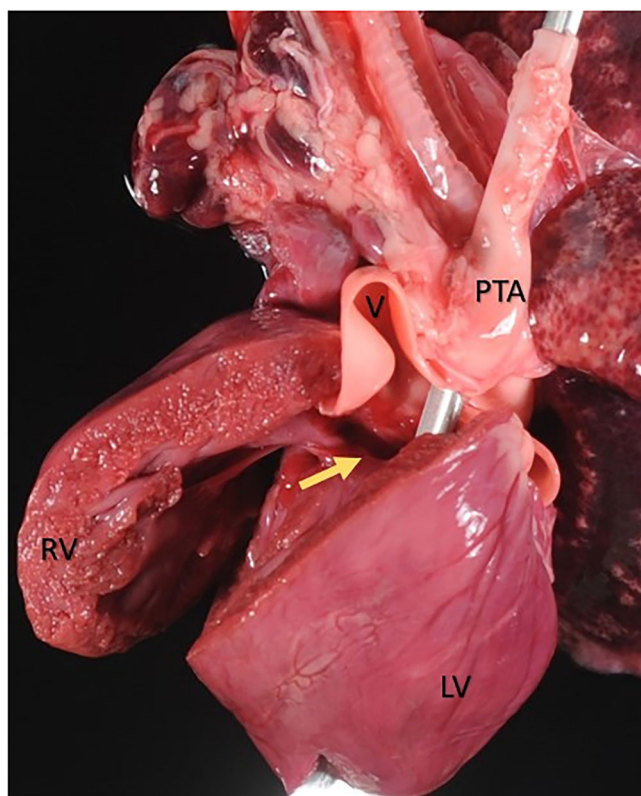


FIGURE 3 Macroscopic evaluation of the heart during necropsy. Thickening of the right ventricle wall (RV) and distension of the common arterial vestibule (V) were observed. Aorta (Ao) and pulmonary arteries exit from the common arterial vestibule. A yellow arrow points to the entrance of the interventricular defect.

vessels (congestion), and a moderate increase of intraalveolar foamy macrophages, frequently with phagocytosed erythrocytes (erythrophagocytosis, heart failure cells). At the cardiac level, an extensive multifocal increase in muscle fibre size was observed in both ventricles, with cytoplasmic hypereosinophilia and karyomegaly indicative of myocardial hypertrophy. Myofibres with irregular vacuolisation of the sarcoplasm compatible with fibre degeneration were also identified. In the liver changes indicative of chronic passive congestion were observed.

Considering all findings, a diagnosis of bilateral congestive heart failure associated with persistent *truncus arteriosus* with the presence of a concomitant perimembranous inlet ventricular septal defect was reached. The role of arrhythmia in congestive heart failure was unknown but it must be taken into account as a probable cause of heart failure.

2 | DISCUSSION

Persistent *truncus arteriosus* in cats has been described in seven prior publications. In five cases, the type 1 persistent *truncus arteriosus* (Bertrand et al., 2019; Chuzel et al., 2007; Markovic et al., 2017; Nicolle et al., 2005) was the same as that described in this study, in two cases the defect was described as type II (Buergelt & Suter, 1968; Nakao

et al., 2021) and the last one as type III (Kochi et al., 2021) under the Collet and Edwards (1949) classification.

The previously described feline cases affected were DSH cats, four males (Bertrand et al., 2019; Buergelt & Suter, 1968; Chuzel et al., 2007; Markovic et al., 2017) and three females (Kochi et al., 2021; Nakao et al., 2021; Nicolle et al., 2005) as the case we describe.

Clinical signs were present from 3 week to 6 months of age (Buergelt & Suter, 1968; Chuzel et al., 2007; Kochi et al., 2021; Markovic et al., 2017; Nakao et al., 2021; Nicolle et al., 2005), but our patient did not show any clinical signs until 10 months of age. The initial examination detected a cardiac murmur (Bertrand et al., 2019; Chuzel et al., 2007; Kochi et al., 2021; Markovic et al., 2017; Markovic et al., 2017), exercise-induced tachypnoea (Chuzel et al., 2007; Markovic et al., 2017; Nakao et al., 2021), tachypnoea and cyanosis (Nakao et al., 2021; Nicolle et al., 2005), and weakness and slow development in the 3-week-old male (Buergelt & Suter, 1968). In our case, the patient presented with acute respiratory signs and, unlike the previous cases, cardiac arrhythmia.

Respiratory problems are common in animals and people with cardiac malformations that affect the great vessels (Hoffman et al., 1981; Ware & Bonagura, 2021; Williams & Sommerville, 1998). Damage in the muscular layer of the pulmonary vessels produces severe pulmonary hypertension (Hoffman et al., 1981; Ware & Bonagura, 2021), which can cause reversal of the flow and passage of nonoxygenated blood into the systemic circulation. In the present case, cyanosis was present at the time of diagnosis, suggesting reversal of the flows at least in the hours prior to death.

Case reports that include electrocardiography describe sinus rhythm with deviation to the right (Markovic et al., 2017) and premature ventricular complexes (Nicolle et al., 2005). A differential aspect of our case is the finding of an electrocardiographic alteration: a conduction disturbance with an atrioventricular dissociation, third-degree sinoatrial block with presence of P_t' waves posterior to the QRS complex; these P_t' waves were positive and more marked in leads I and III. The P_t' wave is posterior to the S wave but before the T wave, with a short RP_t' interval. QRS complexes had normal morphology and duration. Wide QRS complexes could appear if a preexisting intraventricular block or ventricular escape beat occurs (Santilli, 2019; Willis et al., 2018).

Third-degree sinoatrial block usually include the absence of P wave and atrioventricular or ventricular escape rhythm. But can be seen, in some cases, retrograde conduction as P_t' wave with an inferior-superior axis within the first portion of the ST segment with ventriculoatrial conduction ratio of 1:1 (Santilli, 2019). This definition coincides with the observations in our patient. Nevertheless, atrial standstill could not be ruled out because third-degree sinoatrial block with a junctional escape rhythm is indistinguishable from sinus standstill from the surface electrocardiogram (Santilli, 2019; Willis et al., 2018), and advanced electrophysiological examinations could not be performed. Pacemaker implantation is the best treatment option in both arrhythmias (Côté et al., 2011; Santilli, 2019; Willis et al., 2018).

In a normal heart, a fibrous ring in the area of the atrioventricular valves prevents the conduction of retrograde impulses from the

ventricle to the atrium (Lu et al., 2016; Santilli, 2019). Due to the congenital cardiac malformation present in our patient, that is, the persistent *truncus arteriosus* and perimembranous inlet interventricular septal defect, we consider that a deficit in the formation of this fibrous ring allowed retrograde conduction of the electrical impulse towards the atria. However, this electrocardiographic anomaly has not been observed in similar cases, and this is the first time that this alteration has been described in a feline patient with *persistent truncus arteriosus*. This arrhythmia has been described in human medicine without other concomitant cardiac pathologies (Sigurd et al., 1973).

It is an interruption of the transmission of electrical impulses between the sinus node and the atrial myocardium (Santilli, 2019). This block can be produced by inflammation, fibrosis, degeneration of the sinus node, hypervagotonia, increased intracranial pressure, abnormalities in ion channel function or use of antiarrhythmic drugs (Santilli, 2019; Sigurd et al., 1973).

In our case, no relevant areas of fibrosis were seen upon microscopic examination, and we cannot rule out electrolyte problems because a blood test was not performed.

The influence of this arrhythmia at the haemodynamic level and on the presentation of clinical signs in our patient is not clear but it could be a cause of the pulmonary and hepatic congestion observed. Dissociation between atrial contraction and ventricular contraction can cause a decrease in ventricular ejection volume and therefore a decrease in cardiac output, this could have mattered because atrial contraction represents 25% of ventricular diastolic filling (Fuentes, 2015).

In cats, bradycardia is defined as a rhythm less than 140 beats per minute (bpm). Clinical signs will not be observed if the escape rhythm rate is above 100 bpm. Cats could present clinical signs with third-degree sinoatrial block like syncope and if the escape rhythm rate falls below 100 bpm, congestive heart failure develops (Côté et al., 2011; Santilli, 2019).

Decreased ventricular filling and bradycardia could affect the patient's cardiac output and activate the neurohormonal compensatory mechanisms. Activation of neurohormonal compensatory mechanisms over time together with cardiac malformation could have led to bilateral congestive heart failure.

This case is the first description of simultaneous third-degree sinoatrial block and *persistent truncus arteriosus* in a feline species. Persistent *truncus arteriosus* has not previously been associated to this arrhythmia, but some cases with this malformation may not be detected due to the early death without evaluation by a specialist. The anatomical malformation can be related to the arrhythmia, but we cannot exclude other causes not related to the cardiac pathology.

AUTHOR CONTRIBUTIONS

Oscar Monge Utrilla, M Belén García Rodríguez, Inmaculada Diez Prieto: clinical care of the patient, writing and editing the manuscript. Nerea Cuesta García: post-mortem examination, writing and editing the manuscript.

CONFLICT OF INTEREST STATEMENT

The authors declare any conflict of interest.

ETHICS STATEMENT

The authors confirm that the ethical policies of the journal have been adhered to. No ethical approval was required as this was a clinical case under veterinary care.

DATA AVAILABILITY STATEMENT

The article describe a clinical case and there is no more data to include.

ORCID

M Belén García-Rodríguez  <https://orcid.org/0000-0002-4033-0309>

PEER REVIEW

The peer review history for this article is available at <https://publons.com/publon/10.1002/vms3.1132>.

REFERENCES

- Bertrand, A. F. T., Lazard, M., & Bouhsina, N. (2019). What is your diagnosis? *Journal of the American Veterinary Medical Association*, 254, 583–585.
- Buergelt, C. D., & Suter, P. F. (1968). Persistent *truncus arteriosus* in a cat. *Journal of the American Veterinary Medical Association*, 153, 548–552.
- Chuzel, T., Bublot, I., Couturier, L., Nicolier, A., Rivier, P., Mai, W., & Cadore, J. L. (2007). Persistent *truncus arteriosus* in a cat. *Journal of Veterinary Cardiology*, 9, 43–46.
- Collett, R. W., & Edwards, J. E. (1949). Persistent *truncus arteriosus*: A classification according to anatomic types. *Surgical Clinics of North America*, 29, 1245–1270.
- Côté, E. (2011). Arrhythmias and other electrocardiographic abnormalities. In E. Côté, K. A. MacDonald, K. M. Meurs, & M. M. Sleeper (Eds.), *Feline cardiology* (pp. 213–253). John Wiley & Sons.
- Eroksuz, H., Yilmaz, S., Eroksuz, Y., & Borzouee, M. (2015). Persistent *truncus arteriosus* with intact ventricular septum and other cardiovascular malformations in a calf. *Revue de Médecine Veterinaire*, 166, 122–126.
- Fuentes, V. L. (2015). Echocardiography and Doppler ultrasound. In F. W. K. Smith, L. P. Tilley, M. Oyama, & M. M. Sleeper (Eds.), *Manual of canine and feline cardiology* (pp. 77–91). Elsevier Health Sciences, Missouri.
- Hoffman, J. I., Rudolph, A. M., & Heymann, M. A. (1981). Pulmonary vascular disease with congenital heart lesions: pathologic features and causes. *Circulation*, 64, 873–877.
- Kochi, M., Sugimoto, K., Kawamoto, S., Inoue, M., & Machida, N. (2021). Persistent *truncus arteriosus* with an anomalous coronary artery in a cat. *Journal of Veterinary Cardiology*, 35, 8–13.
- Lu, Z., He, B., He, W., Xie, J., Yu, X., & Jiang, H. (2016). Electrocardiographic characteristics of idiopathic premature ventricular contractions originating from the junction of the right ventricular outflow tract and tricuspid annulus. *International Journal of Cardiology*, 203, 5–11.
- Markovic, L. E., Scansen, B. A., & Potter, B. M. (2017). Role of computed tomography angiography in the differentiation of feline *truncus arteriosus* communis from pulmonary atresia with ventricular septal defect. *Journal of Veterinary Cardiology*, 19, 514–522.
- Nakao, S., Atkinson, A. J., Motomochi, T., Fukunaga, D., & Dobrzynski, H. (2021). Common arterial trunk in a cat: A high resolution morphological analysis with micro-computed tomography. *Journal of Veterinary Cardiology*, 34, 8–15.
- Nicolle, A. P., Tessier-Vetzel, D., Begon, E., Carlos Sampedrano, C., Pouchelon, J.-L., & Chetboul, V. (2005). Persistent *truncus arteriosus* in a 6-year-old cat. *Journal of Veterinary Medicine Series A*, 52, 350–353.
- Santilli, R. (2019). Anatomy and physiology of the conduction system. In R. Santilli, N. S. Moïse, R. Pariaut, & M. Perego (Eds.), *Electrocardiography of the dog and cat, diagnosis of arrhythmias* (pp. 1–19). Edra, Milano.
- Scansen, B. A., Matthias, S., & Bonagura, J. D. (2015). Sequential segmental classification of feline congenital heart disease. *Journal of Veterinary Cardiology*, 17, S10–S52.

- Schrope, D. P. (2015). Prevalence of congenital heart disease in 76,301 mixed-breed dogs and 57,025 mixed-breed cats. *Journal of Veterinary Cardiology*, 17, 192–202.
- Sigurd, B., Jensen, G., Meibom, J., & Sandoe, E. (1973). Adams-Stokes syndrome caused by sinoatrial block. *British Heart Journal*, 35, 1002–1008.
- Ware, W. A., & Bonagura, J. D. (2021). Respiratory distress. In W. A. Ware, & J. D. Bonagura (Eds.), *Cardiovascular disease in companion animals: Dog, cat and horse* (pp. 211–223). CRC Press.
- Williams, R. L., & Sommerville, R. J. (1998). *Truncus arteriosus*. In R. A. Garson, J. T. Bricker, D. J. Fisher, & S. R. Neish (Eds.), *The science and practice of pediatric cardiology* (pp. 1002–1022). Baltimore.
- Willis, R. (2018). Bradyarrhythmias and conduction disturbances. In R. Willis, P. Oliveira, & A. Mavropoulou (Eds.), *Guide to canine and feline electrocardiography* (pp. 79–108). Wiley Blackwell.

How to cite this article: Monge-Utrilla, O., García-Rodríguez, M. B., Cuesta-García, N., & Diez-Prieto, I. (2023). Atrioventricular dissociation in a cat with persistent *truncus arteriosus*. *Veterinary Medicine and Science*, 9, 1031–1035. <https://doi.org/10.1002/vms3.1132>